An Early Ottoman Cemetery at Ancient Corinth
Author(s): Orestes H. Zervos, Arthur H. Rohn, Ethne Barnes and Guy D. R. Sanders
Source: *Hesperia: The Journal of the American School of Classical Studies at Athens*, Vol. 78, No. 4 (Oct. - Dec., 2009), pp. 501-615
Published by: The American School of Classical Studies at Athens
Stable URL: http://www.jstor.org/stable/25622710
Accessed: 11/10/2013 01:17

Your use of the JSTOR archive indicates your acceptance of the Terms & Conditions of Use, available at http://www.jstor.org/page/info/about/policies/terms.jsp

JSTOR is a not-for-profit service that helps scholars, researchers, and students discover, use, and build upon a wide range of content in a trusted digital archive. We use information technology and tools to increase productivity and facilitate new forms of scholarship. For more information about JSTOR, please contact support@jstor.org.

The American School of Classical Studies at Athens is collaborating with JSTOR to digitize, preserve and extend access to *Hesperia: The Journal of the American School of Classical Studies at Athens.*

http://www.jstor.org

This content downloaded from 78.100.65.226 on Fri, 11 Oct 2013 01:17:53 AM
All use subject to JSTOR Terms and Conditions

HESPERIA 78 (2009)
Pages 501–615

AN EARLY OTTOMAN CEMETERY AT ANCIENT CORINTH

ABSTRACT

The authors report in this article on the excavation and skeletal analyses of 81 graves containing the remains of 133 individuals in a 17th-century cemetery in the Panayia Field at Ancient Corinth. Two distinct styles of burial reflect Orthodox Christian and Muslim traditions. Osteological analyses revealed a preponderance of adult males over females; more young and middle-aged males and fewer small children than might be expected; and numerous instances of physical violence, including two obvious cases of punishment. The presence of iron boot-heel reinforcement cleats and the mixing of Christian and Muslim burial practices suggest that the cemetery may have served a garrison population in Corinth under Ottoman rule during the early 17th century.

This article presents the results of the excavation of an early Ottoman cemetery in the Panayia Field at Ancient Corinth and the thorough analyses of the human remains and grave goods found within it.[1] As two archaeologists and one physical anthropologist, we do not presume to provide a historical overview of Ottoman society and its impact on its many conquered and subservient peoples, but instead focus here on one particular population

1. Excavation of the human burials in the Panayia Field in 1995–1997 and 2000–2003 formed part of the annual investigations at Ancient Corinth by the American School of Classical Studies at Athens. We gratefully acknowledge the support of the American School and of the Greek Archaeological Service and its local representatives, F. Pachyianni-Kaloudi, E. Spathari, and A. Mantis, the directors of the 37th Ephoreia of Prehistoric and Classical Antiquities, and K. Skarmoutsou, the director of the 25th Ephoreia of Byzantine and Post-Byzantine Antiquities, during this period.

Anastasios Kakouros, Dimitris Notis, Athanassios Notis, Vassilis Papanikolaou, Nikos Rothonis, and Athanassios Sakellariou were trained by Rohn to excavate these graves, while Ioannis Economopoulos, Panayiotis Kakouros, and Giorgios Kakouros were later instructed by A. Kakouros and D. Notis. A few unusual graves were excavated by Rohn, Barnes, and Alicia Carter. Many individuals participated in recording the cemetery, and their contribution toward compiling an accurate record of the burials is greatly appreciated. The majority of the graves were recorded by Rohn, assisted by Carter, with a smaller number recorded by Kostis Kourelis, also assisted by Carter. Objects associated with the burials were usually assigned a Corinth inventory number (MF-); whenever available, these numbers are given in the text. Coins were analyzed by Orestes Zervos (see Appendix).

Unless otherwise indicated, James Herbst provided the drawings of the burials presented here. Field photography was carried out by Rohn, Sanders, and Herbst; Barnes was responsible for all photographs of skeletal remains; and I. Ioannidou and L. Barzioti photographed the coins and other artifacts.

© The American School of Classical Studies at Athens

This content downloaded from 78.100.65.226 on Fri, 11 Oct 2013 01:17:53 AM
All use subject to JSTOR Terms and Conditions

and the ways in which its mortuary records enrich our understanding of Corinthian lives under Ottoman domination. An extensive literature can be found elsewhere on Ottoman administration, economics, production, trade, and taxation.[2]

The emphasis on mortuary records is important because of the paucity of similarly reported Ottoman cemeteries within the Aegean region. Scholars have previously remarked on the tendency of classical and biblical archaeologists to be hasty when excavating the recent phases of their sites so that they can quickly reach the underlying strata in which they are more interested.[3] The fact that so few Ottoman-period or Muslim cemeteries have been excavated and carefully recorded, let alone published, may be in part a consequence of this behavior.

After a general introduction to Ottoman Corinth, we provide a description of the Panayia Field cemetery—its extent, stratigraphy, dating, and composition (i.e., the nature of the graves and their various contents). During the recording of the graves, great attention was paid to details of grave alignment and specific positions of the various skeletal parts. As described below, the exact azimuth to which the head points provides a crucial clue in the differentiation between Christian and Muslim grave styles. Similar aspects of head position—facing up, having been propped up, lying to one side or the other, mouth remaining closed or open—help in the interpretation of funerary behavior. Similarly the precise positions of elbows, hands, and feet contribute both to differentiating styles of graves and to interpreting the past treatment of the dead.

There follows a discussion of the results of osteological analyses of the human remains found in the cemetery. We then attempt to reconstruct the funerary behavior of the people who chose to bury their dead in this cemetery. The article also includes a catalogue of the graves, and an appendix describing associated coins.

OTTOMANS AT CORINTH

Excavations at the site of Ancient Corinth by the American School of Classical Studies at Athens from 1896 through the present have produced a remarkable store of both published and unpublished information about the site's long history of continuous occupation from the Early Neolithic to late medieval times.[4] By contrast, relatively little information about Corinth's post-medieval remains has been published in any great detail.

From its beginnings in Anatolia during the late 13th century A.D., first the Seljuk Sultanate and then the Ottoman Sultanate (and subsequent Empire) steadily expanded into Mesopotamia, across northern Africa, and into the Balkans.[5] Each new conquest enhanced Ottoman power and its appetite for more conquests. While Turkish and Anatolian peoples had already begun sizeable immigration into the area of present-day Greece during the late 14th and early 15th centuries,[6] the fall of Constantinople in 1453 effectively opened up all of Greece and the Aegean to Ottoman domination.

History has recorded Turkish raids on Corinth in 1387, 1388, and 1395.[7] When Nicola de Marthono, an Italian notary, visited Corinth during troubled times in 1395, he found the lower town abandoned and

2. See, e.g., Woodhouse 1991; İnalcık 1993; Jennings 1999; Faroqhi 1999, 2000; Baram and Carroll 2000a; Forbes 2000; and Greene 2000, to mention only a few.

3. See, e.g., Insoll 1999, p. 166; Baram and Carroll 2000b, pp. 15–25.

4. The primary results of this work appear in *Hesperia, AJA,* and the *Corinth* series. Discussions of the present state of our knowledge appear with a full primary bibliography in *Corinth* XX.

5. Woodhouse 1991, pp. 84–85.

6. Woodhouse 1991, pp. 86–98.

7. *Corinth* III.2, p. 141.

This content downloaded from 78.100.65.226 on Fri, 11 Oct 2013 01:17:53 AM
All use subject to JSTOR Terms and Conditions

the entire population, consisting of an estimated 50 families, living on Acrocorinth.[8] Refurbishment of the trans-Isthmian wall in 1396 could not stop the Ottoman Evrenos Bey's assault of 1397. Turkish raids continued in increasing strength, bypassing Acrocorinth, until May 15, 1458, when Mehmed II camped near Corinth. A subsequent siege led by Mahmut, his Grand Vizier, lasted until August 6 and resulted in the capitulation of the garrison and its population. In 1612, Corinth was briefly taken by Vaqueras, commander of the Knights of Malta.[9]

Scraps of information about post-medieval monuments in the lower town, for instance the later churches, have been published by Robert Scranton, and more recently by Pierre MacKay for the fountain of Hadji Mustapha (Joseph the Tailor) and by Metaxia Chrysafi-Zografou for the houses and for the monuments of Corinth in general.[10] A single tree-ring date of 1508vv ("vv" indicates an unknown number of missing rings from the outside of the specimen) has been obtained "from oak stretchers within the walls of an unnamed and hitherto undated mosque" somewhere in Corinth or on Acrocorinth.[11] Rhys Carpenter, Antoine Bon, and Timothy Gregory have given rather fuller accounts of the fortifications of the site, especially the walls on Acrocorinth and the trans-Isthmian wall, but the massive Venetian fortifications between Lechaion and Mount Oneion remain less well documented.[12] In his monumental volume on the Byzantine pottery of the site, Charles Morgan mentioned, but did not elaborate on, the post-medieval material.[13] This gap in our knowledge of post-medieval ceramics is gradually being filled.[14] Finally, Henry and Rebecca Robinson have added more recently excavated information to the little garnered in the excavations before 1950.[15]

This report focuses on a phase of Corinth's history that closed with the Venetian reoccupation in 1687. Unlike earlier work, it concentrates not on the monuments and material culture of the inhabitants but on their mortal remains found in the Panayia Field (Fig. 1). The first burials were encountered during the earliest three seasons of excavation, conducted on a limited scale in 1995–1997.[16] After the end of the 1997 season, topsoil was removed from a large portion of the field to the north of the Late Roman bath, revealing the disturbed foundations of Early Modern structures. This area was not systematically explored until 2001, when an open-area, single-context excavation system was adopted to cope with the large numbers of burials. This system reveals the remains of a single phase distributed across an extensive area.

8. Vin 1980, pp. 615–620.

9. Pouqueville 1826, p. 449, n. 3.

10. *Corinth* XIV, pp. 88–102; MacKay 1967; Chrysafi-Zografou 1984, 1987.

11. Kuniholm 2000, p. 116.

12. *Corinth* III.2, pp. 146–159; *Isthmia* V.

13. *Corinth* XI, pp. 171–174.

14. Williams and Zervos 1992, pp. 133, 171–173. In the upper levels of the Panayia Field are several pits and other contexts with coins, pipes, and pottery of the Late Ottoman and Early Modern periods. This material is currently under study for publication.

15. Robinson 1962, pp. 120–130, pls. 37–40; 1976, pp. 219, 223–224, pl. 48; Robinson 1985.

16. This work focused on illuminating the nature and date of two structures partially excavated previously by the 4th Ephoreia of Prehistoric and Classical Antiquities in response to applications to build homes. One structure with mosaic pavements was found to belong to a Late Antique urban *domus* in the southwest corner of the property and the other was a small Late Roman bath that overlay the *domus* in the center of the property. Sanders (2001, p. 5; 2005, pp. 420–429) discusses the *domus* and bath phases; see the later publication for illustrations of the *domus* (p. 422, fig. 16.2) and the bath and associated buildings (p. 427, fig. 16.5).

This content downloaded from 78.100.65.226 on Fri, 11 Oct 2013 01:17:53 AM
All use subject to JSTOR Terms and Conditions

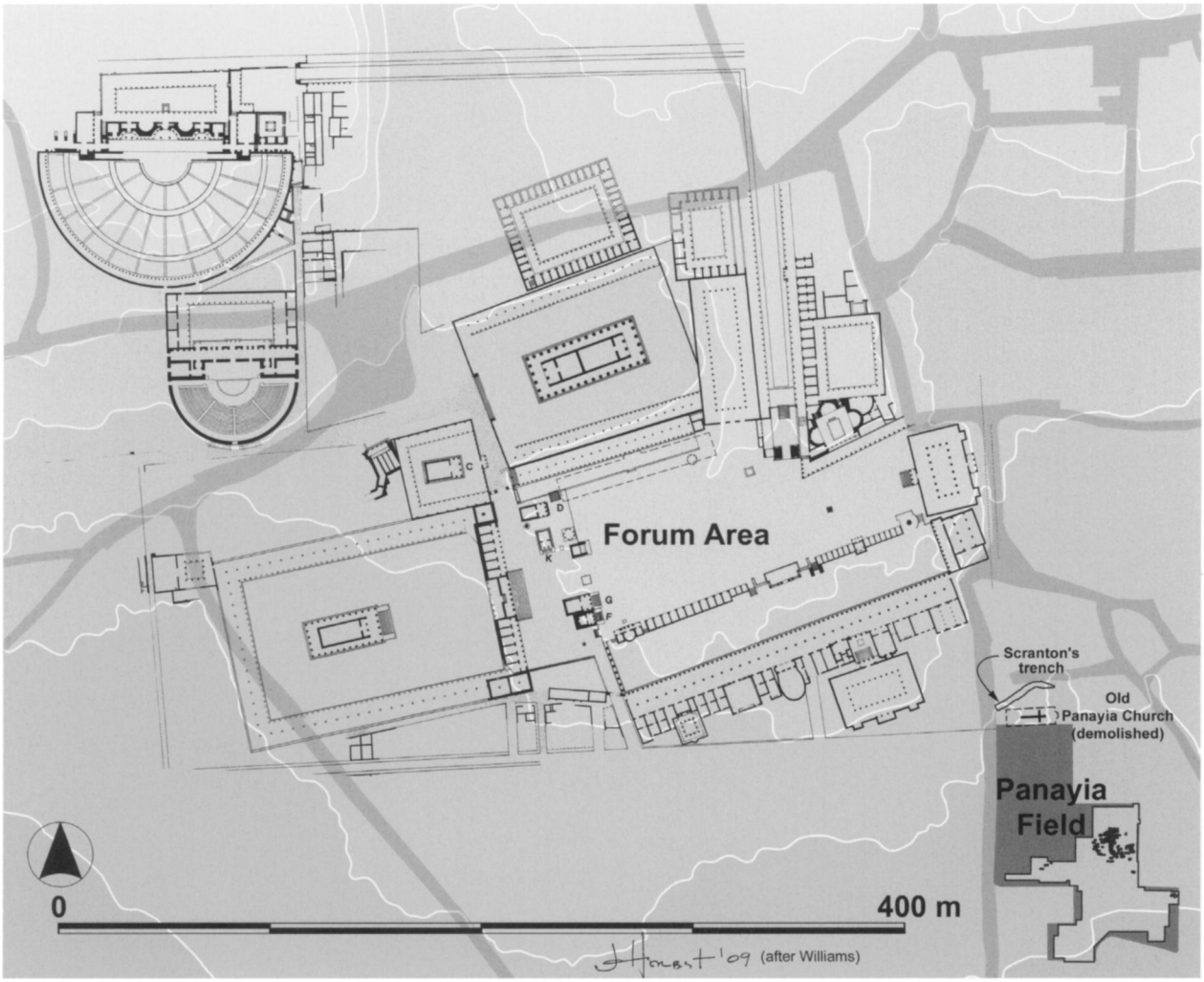

Figure 1. Plan of the central area of Ancient Corinth showing the Panayia Field in relation to the Roman Forum. J. Herbst

Agricultural activity in the Panayia Field, specifically the repeated episodes of shallow plowing and successive planting of lemon trees, and subsequently orange trees, has almost obliterated the upper subsurface strata. With rare exceptions, only the foundations of Early Modern structures survive, while even the floors, destruction contexts, and upper fill of pits associated with the architecture have been obliterated. Nevertheless, the outline of three almost complete and five partial Early Modern houses and sections of their adjoining gardens have been traced in the area excavated (Fig. 2).

Although evidence for the last phases of occupation has largely been destroyed, the lower fills of several rubbish pits and the dumped fills contain material culture spanning this Early Modern period of occupation. Removing the foundations of a house at the north end of the excavated area enabled the continuation of work in anticipation of revealing more of the Late Antique city, more specifically the north side of the 3rd–4th-century A.D. Roman house *(domus)*. Instead, it was discovered that a late-18th-century pit partially underlay the foundations of the walls. Both the house foundations and this pit physically cut into a cluster of individual graves belonging to an earlier post-medieval phase. The graves themselves had been dug into Late Antique and, in places, medieval strata.

This content downloaded from 78.100.65.226 on Fri, 11 Oct 2013 01:17:53 AM
All use subject to JSTOR Terms and Conditions

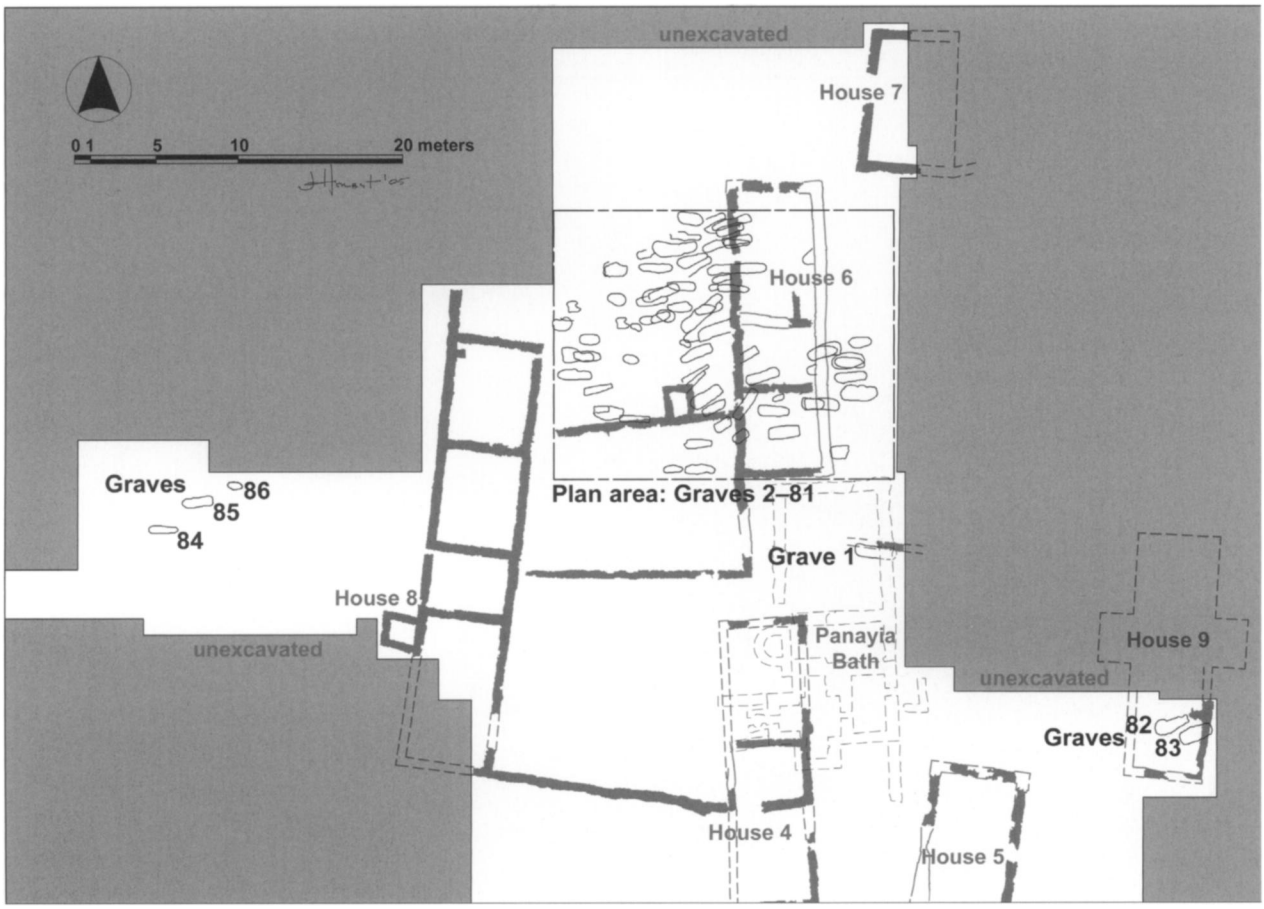

Figure 2. Seventeenth-century cemetery and outlying graves (numbered) in the Panayia Field, with 19th-century house foundations. Figures 3 and 4 present enlargements of the "plan area." J. Herbst

THE CEMETERY

The identification of this group of graves as the Panayia Field cemetery derives from the close clustering of 80 excavated graves and at least 10 additional unexcavated graves (apparent from outlines) within a subcircular space 19 m east–west by 16 m north–south (Figs. 3, 4). The graves lie juxtaposed to one another (Fig. 5) along generally parallel axes angling east–west to northeast–southwest. In cases where one grave intersects another, bones from the disturbed burial have been redeposited within the fresh grave. Frequent reopening of older graves to inter newly deceased individuals indicates that the location of these graves was known. Thus, this cemetery probably reflects patterned behavior for a single cohesive community.

Excavations have essentially defined the southern and eastern edges of the Panayia Field cemetery, which extends westward stratigraphically beneath an adjacent and later cemetery associated with the (now-demolished) Old Panayia Church (see Fig. 1). Although its presence is known through village oral history, the Panayia Church cemetery has never been systematically excavated (see below, pp. 508–509). Robert Scranton reported an unspecified number of relatively recent burials in a trench excavated north of the church (see Fig. 1).[17]

Grave **1** lies only about 4 m southeast of the Panayia Field cluster's southeasternmost grave (see Fig. 2), and it is therefore considered an outlier of this cemetery, bringing the total number of graves catalogued to 81.

17. Corinth notebook 193, pp. 55–61 (March 3–8, 1947).

This content downloaded from 78.100.65.226 on Fri, 11 Oct 2013 01:17:53 AM
All use subject to JSTOR Terms and Conditions

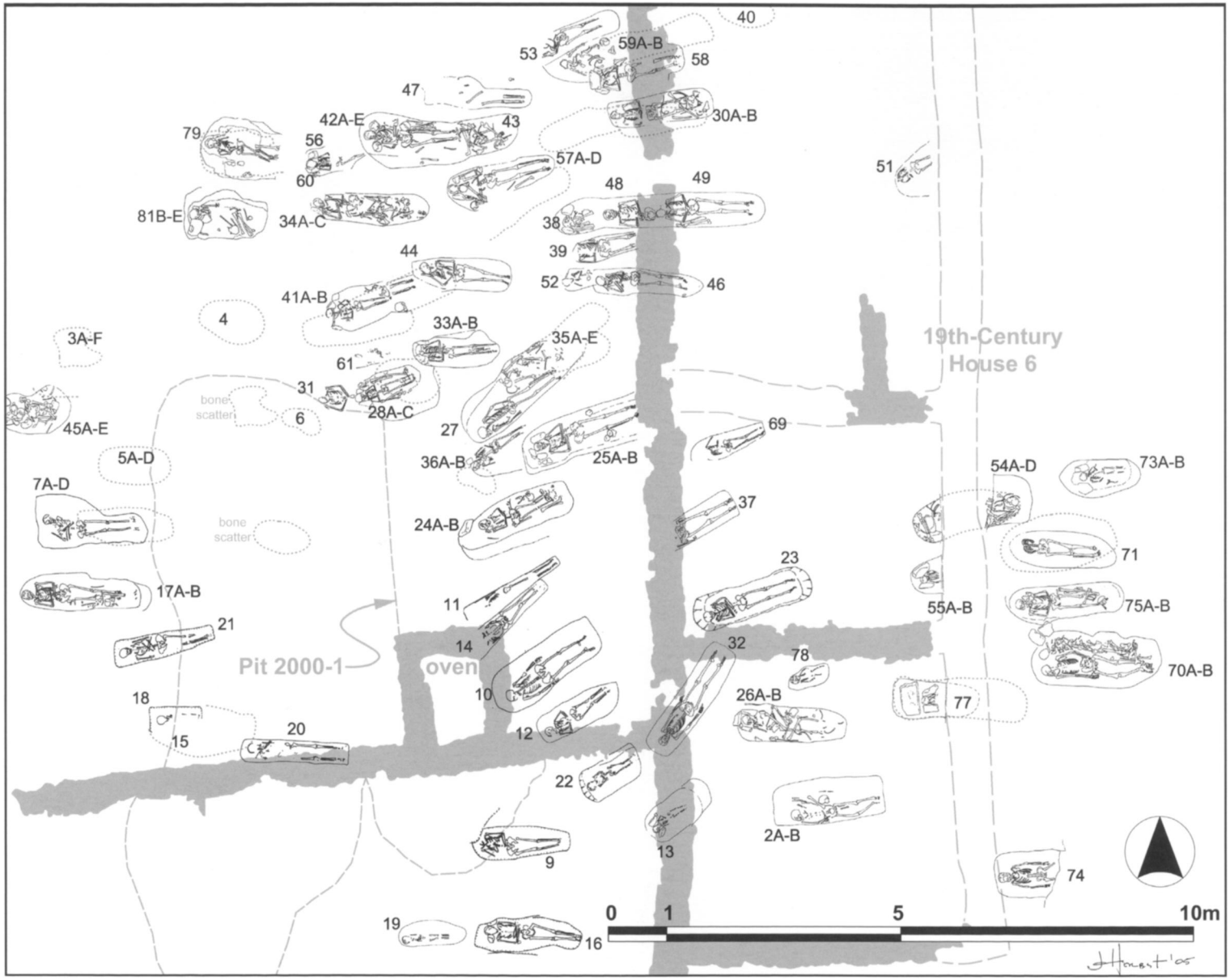

Figure 3. Upper-level graves in the Panayia Field cemetery (detail of Figure 2). Graves 64 and 80B–E not shown. J. Herbst

This content downloaded from 78.100.65.226 on Fri, 11 Oct 2013 01:17:53 AM
All use subject to JSTOR Terms and Conditions

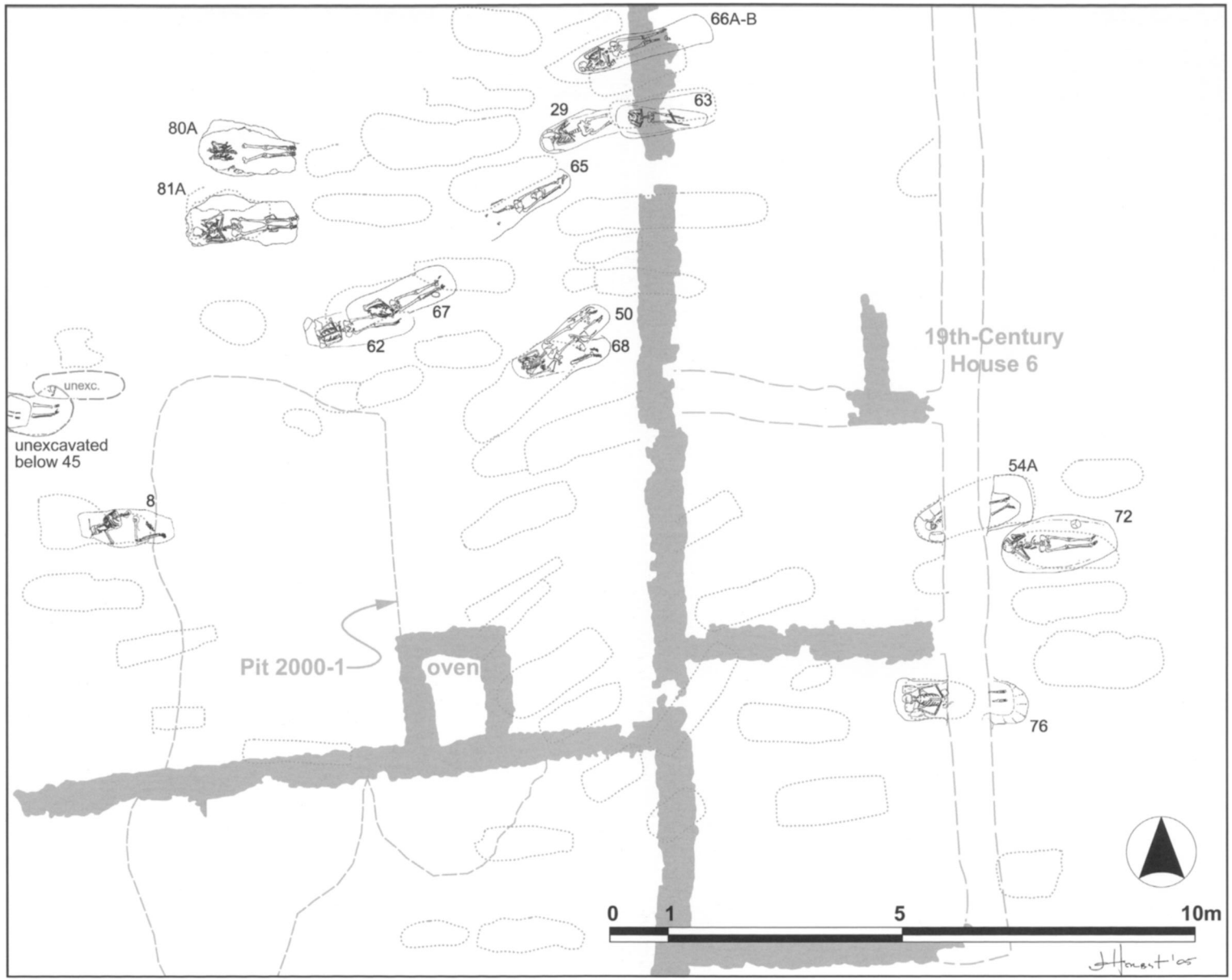

Figure 4. Lower-level graves in the Panayia Field cemetery (detail of Figure 2). J. Herbst

This content downloaded from 78.100.65.226 on Fri, 11 Oct 2013 01:17:53 AM
All use subject to JSTOR Terms and Conditions

Figure 5. Overview of the 17th-century cemetery, looking south

Another two excavated graves (**82, 83**) and at least three unexcavated ones, located 24 m to the southeast, may also prove to belong to the cemetery if additional graves are found in the block of land that remains to be excavated between them and the cemetery. The full extent of the cemetery to the west and north is unknown because the Panayia Church cemetery overlies the western limit of excavation, and, as noted above, 19th-century agricultural activities have apparently destroyed the northern limits. The two graves to the southeast (**82, 83**) and three others 19–20 m to the west (**84, 85, 86**) are described separately in the catalogue, since they may not belong to the Panayia Field cemetery.

Most of the graves had been dug into a thick reddish deposit dated by ceramics to the 6th or 7th century A.D. and related to Late Roman structures to the south. These structures included a bath[18] and two phases of a Roman villa. The top of this reddish layer marks an unconformity that represents time passing while no deposition took place. Hence, the establishment and use of this cemetery represents the next event in the stratigraphic record following the Late Roman deposition.

From above, a wide saucer-shaped pit measuring ca. 8.50 × 3.60 m across cuts into and through the southwestern portion of the known cemetery (pit 2000-1; Figs. 3, 4). This pit had served as a dump containing ceramics and other discarded materials dating it to ca. A.D. 1800±10. Within this dump, five Ottoman coins (2000-126, 2000-127, 2000-133, 2000-134, 2000-135) minted by Ottoman rulers between A.D. 1757 and 1789 were recovered (see Appendix). Four of these were struck during the reign of Sultan Abdul Hamid I, and the latest (2000-134) belonged to the sultan's 13th regnal year of 1786. The remaining coin (2000-126) is an undated *para* of Mustafa III (A.D. 1757–1774). Since this coin had been pierced, perhaps for secondary use in traditional costume jewelry, the date of its deposit probably falls

18. For the bath, see Sanders 1999.

This content downloaded from 78.100.65.226 on Fri, 11 Oct 2013 01:17:53 AM
All use subject to JSTOR Terms and Conditions

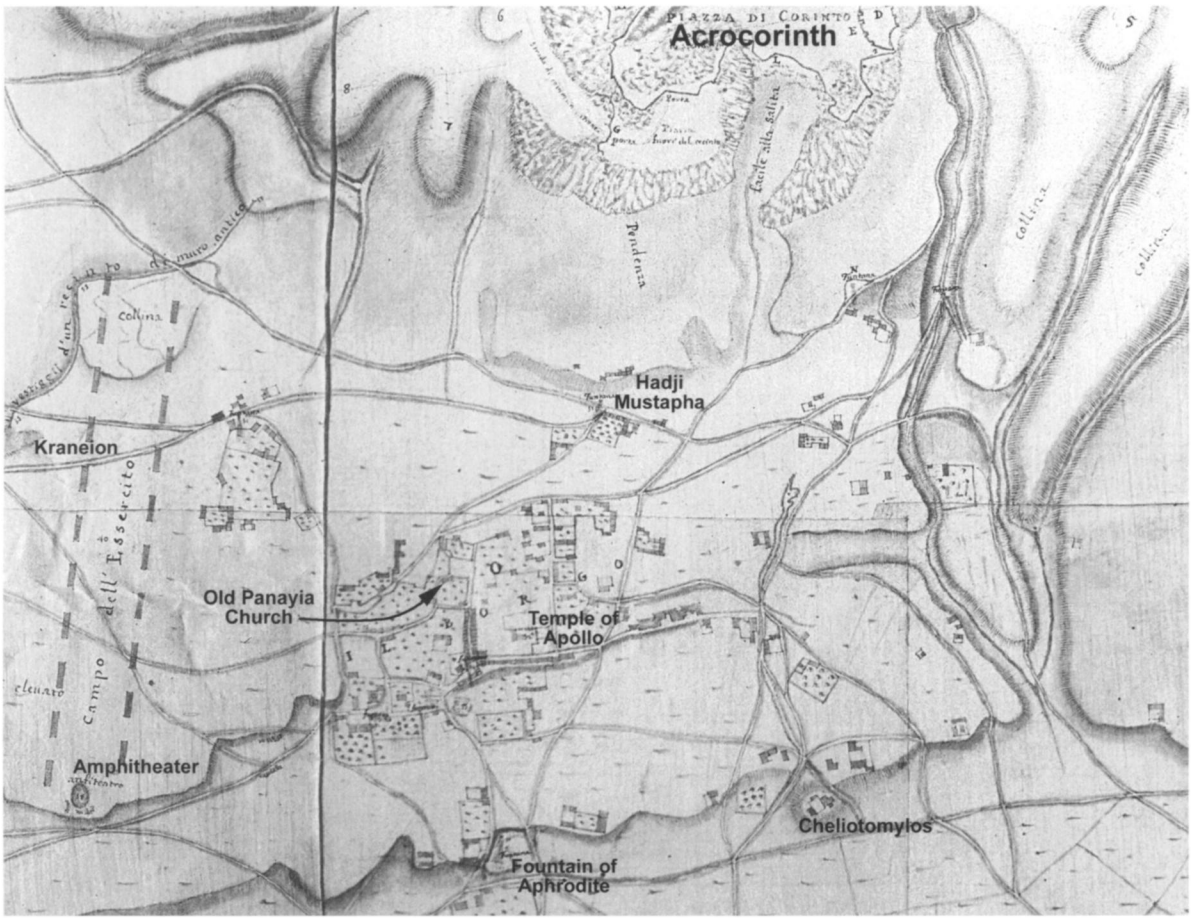

Figure 6. Ancient Corinth shown on a map of the Isthmus commissioned by Morosini in 1687 (labels added). The Panayia Field lies south and southeast of the Old Panayia Church. Photo courtesy Austrian State Archives

somewhere in the last quarter of the 18th century. Two other Ottoman coins found in deposits immediately above the graves confirm this chronological assessment. These are another undated *para* of Mustafa III and an undated, holed *para* of Selim III (A.D. 1789–1807) found in the plow zone over the cemetery (2001-118 and 2001-149).

Although the pit lies about 6 m west of an early-19th-century Greek farm building, house 6, its contents differ from the household furnishings of this farmstead, while the wall enclosing one of the fields adjacent to the house actually cuts through, and therefore postdates, the pit. There is no evidence that the Early Modern property owners who created the pit, cultivated the fields, and occupied the houses realized that there had once been a cemetery there, even when their wall foundations cut through several graves.

The much larger cemetery associated with the Old Panayia Church appears to overlie the Panayia Field cemetery on the west (see Fig. 1). The church was torn down around 1950 for relocation next to the plateia of the modern village and, unfortunately, we possess no definitive information about when it was originally built or when its associated cemetery operated. In 1676, the English traveler George Wheler refers to a cluster of about 80–100 houses around a marketplace with two mosques and one small church, dedicated to the Panayia, where the archbishop lived.[19] The church can be tentatively identified on a map commissioned by Morosini in 1687 (Fig. 6). It is possible, therefore, that the cemetery reported on in this

19. Wheler 1682, p. 439.

This content downloaded from 78.100.65.226 on Fri, 11 Oct 2013 01:17:53 AM
All use subject to JSTOR Terms and Conditions

article may have been associated with this Panayia Church. In any event, memory of the Panayia Field cemetery had been lost, probably during the period of Venetian government of Ancient Corinth (A.D. 1687–1715), but certainly no later than the Second Ottoman period (A.D. 1715–1823).

Stratigraphically, therefore, active use of the Panayia Field cemetery can be placed between the last Late Roman deposit of the 6th or 7th century A.D. and the cutting and filling of the wide saucer-shaped pit around 1800. Some 50 coins recovered from within and around the graves help to narrow the span (see Appendix). Twenty-four coins (16 from graves, and 8 from surrounding surfaces) are medieval (2), Roman and Late Roman (18), and pre-Roman (4) issues. All of these probably represent relocations from earlier contexts into which the graves of this cemetery had been dug. The underlying reddish deposit, the bath, and the villa belong to Late Roman and Roman uses of the Panayia locality, while Hellenistic and earlier deposits have been found beneath them. Another 18 coins, all from solid grave contexts, represent early Ottoman and other early-17th-century issues, providing strong evidence that the graves in which they were found could not have been dug before the early 17th century. One additional coin came from a pit that had cut into and partially removed grave **9**, containing the burial of a young female adult, and its deposition therefore postdates the grave. This coin is an anonymous Venetian colonial issue (2001-117) dated to A.D. 1684–1710.

Consequently, if all of the graves in this cemetery can be considered essentially contemporary, within a few years or decades of one another—and their general conformity and juxtapositions strongly support this view—the cemetery would most likely have been in use during the first two-thirds of the 17th century, toward the end of the First Ottoman period at Ancient Corinth. The period of Venetian government from 1687 to 1715, or the later Ottoman period that followed, may have obliterated all visible signs of this cemetery above ground.

The Graves

The question of what constitutes a grave becomes useful to ponder when several skeletons turn up in a single excavation context. We have elected to distinguish between a "burial" and a "grave" in the following manner: a "burial" represents the placement of a deceased person's corpse into a prepared "grave." Each burial marks a single funeral. However, more than one burial can be placed into one grave, with or without modification of the grave. Hence, the archaeologically derived contents of a single grave may reflect several separate burial events or funerals. In the following discussion, therefore, we employ these two terms to distinguish between individual funeral events (burials) and the contexts (graves) within which they took place. Graves are identified by boldface numbers, and the component burials are identified by letters.

During excavation, we soon recognized that the graves represented two distinct styles of burial. One style replicated the pattern widely seen in Christian graves throughout Corinth from Late Roman times to the present day. These graves are generally oriented east–west with the head to the west, the body extended on its back with feet together and arms folded

This content downloaded from 78.100.65.226 on Fri, 11 Oct 2013 01:17:53 AM
All use subject to JSTOR Terms and Conditions

Figure 7. Typical oblong grave pit, Christian-style grave 22

over the torso or pelvic area, and with sparse funerary objects, usually related to clothing and adornment. Christian graves frequently contain more than one individual from the same family.

The second burial style we interpret as Muslim. Graves containing these burials tend to be oriented in a more northeast–southwest direction, with the body extended on its back or the right side of the back, the head to the west and turned on its right side to face the Muslim sacred city of Mecca, feet separated and arms extended along the sides, and with no objects accompanying the burial. Muslim-style graves almost never contain more than a single individual.[20]

All 81 excavated graves in the Panayia Field cemetery were simple long oblong or ovoid pits dug into the underlying soil, most often into the Late Roman reddish deposit (Fig. 7). The gravediggers did not line the graves with stones, tiles, or other materials, leaving the sides of plain earth somewhat irregular. Such digging turned up Late Roman and sometimes earlier ceramics and other materials that were usually redeposited in the fill of the graves. Most graves ranged in depth from ca. 0.30 to 0.57 m, though one grave (**54**) extended down to 0.62–0.67 m. Graves for infants and small children tended to be slightly shallower. Unfortunately, 19th-century farming practices resulted in the tops of many graves being sliced off, making it impossible to gauge their precise depths.

Once the funeral participants laid the body of the deceased into the grave, presumably encased in a shroud (although we could detect no direct evidence for this practice), and all graveside rituals had been completed, the earth that had been dug out of the grave was used to refill it. Traces of any efforts to mark the graves with wooden or stone markers, or to maintain

20. See Insoll 1999, pp. 167–173. In formulating most of the criteria for distinguishing between Christian and Muslim burials at Corinth, Rohn used comparative data from Bedouin graves excavated in Israel (Toombs 1985, pp. 48–90; Eakins 1993, pp. 19–35).

This content downloaded from 78.100.65.226 on Fri, 11 Oct 2013 01:17:53 AM
All use subject to JSTOR Terms and Conditions

commemorative activities such as burning lamps, have been completely erased by later activities.

All of the graves in the Panayia Field cemetery were oriented east–west or northeast–southwest, with the heads located at the western ends. All of the Muslim-style graves and most of the Christian-style ones in the southeastern quadrant of the cemetery exhibited the northeast–southwest orientation, more typical of Muslim graves, while graves in the northern and western sectors lay east–west or, at most, east-northeast to west-southwest, more typical of Christian practice.

Grave **11** contained fragments of wood and numerous iron nails that must have derived from a coffin (Fig. 8). Many of the wood fragments lined the sides of the grave for this 15–16-year-old adolescent male, indicating that the coffin's shape mirrored the grave outline with straight sides tapering toward a squared foot end. It fit closely inside the grave with only 4 cm to spare on the northwest side. When grave **14** was partially cut into the foot end of the coffin, some wood fragments and nails were redeposited inside the newer grave.

Apart from this clear case, no wood fragments marking the presence of coffins appeared in any other graves. Iron nails turned up in seven additional graves, ranging in quantity from two to a dozen. Would any of these occurrences indicate a coffin, without the preservation of any wood fragments? Different woods deteriorate at different rates, so it is possible, but iron nails occur ubiquitously in construction debris. Ideally, the assessment of the possibility of a coffin having been present should include an analysis of the way in which the nails were distributed around the body and consideration of whether the grave was large enough to accommodate a coffin.

On these grounds, then, the seven iron nails distributed around the head, left side, and feet of the infant in grave **18** do suggest the outline of a coffin, and the grave size could certainly have allowed room for a small infant-sized coffin. Twelve iron nails came from grave **19**. Seven of them, with points up, outlining the head and left side of the body, also hint at the remains of a coffin ca. 1.03 m long in the grave (itself 1.15 m long) of this small four- to five-year-old child. Four of the six nails found in grave **21** partly outline the adult male body inside it (Fig. 9), but the space surrounding this body allowed no more than 7 cm at either of the two ends and at most 3 cm for either side. A wooden coffin would have had a very tight fit in this grave.

None of the other graves that produced nails could have held coffins. Grave **15** with five nails represents a secondary burial that most likely obtained its nails from the disturbance of the underlying grave **18**. The sides and end of grave **46**, containing six nails, lay too close to the enclosed body to have allowed room for a coffin. While the size of grave **70**, a reused Muslim-style grave containing two adult males, was ample for a coffin, the eight iron nails there were scattered throughout the grave fill. Finally, the two iron nails with an adult male in grave **7** do not provide sufficient evidence for a coffin.

In sum, there is strong circumstantial evidence for the presence of wooden coffins in only three graves (**11**, **18**, **19**), containing an adolescent, an infant, and a small child, all interred in a Christian manner along the

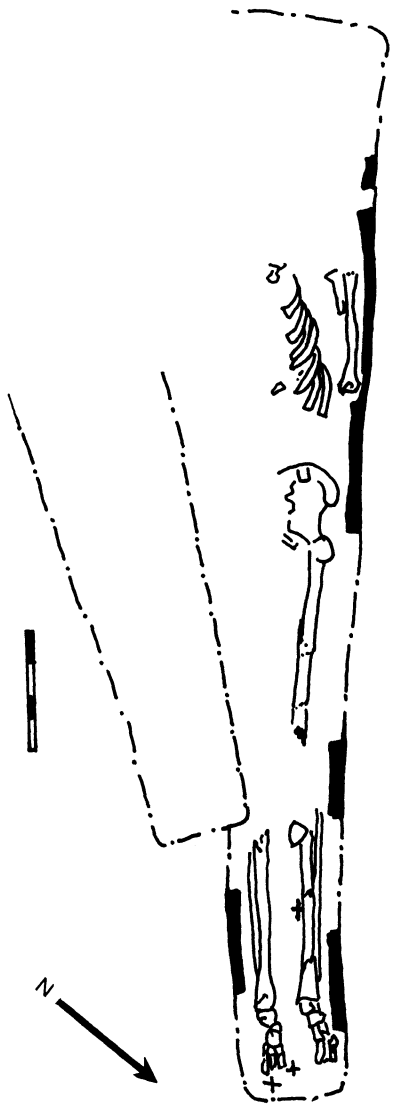

Figure 8. Wood (heavy black lines) and iron nails (marked by +) outlining an adolescent burial's coffin in grave 11. Later grave 14 has intruded along the south side, destroying part of the coffin and its grave. Drawing E. Barnes

This content downloaded from 78.100.65.226 on Fri, 11 Oct 2013 01:17:53 AM
All use subject to JSTOR Terms and Conditions

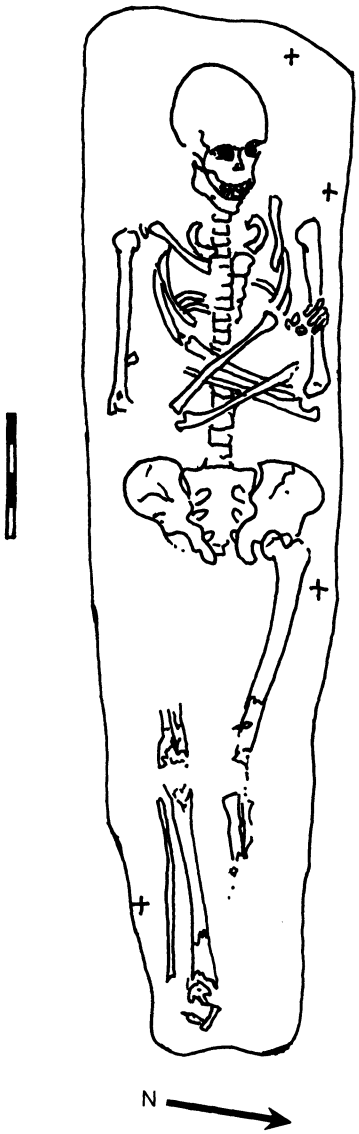

Figure 9. Four iron nails (marked by +) partially outlining the adult male body in grave 21. Drawing E. Barnes

southwest edge of the cemetery. No other graves offered convincing evidence for the presence of a coffin. In fact, the vast majority of the graves lacked adequate space surrounding the body for a coffin to have been present. Twenty graves contained stones flanking the head of the deceased; clearly, these graves could not have contained coffins. We must assume, then, that the majority of people had been buried in this cemetery without benefit of a coffin. Perhaps they had been encased in simple cloth shrouds instead. Intriguingly, although the sample is small, coffins appear to have been used only for subadults, and not for adults.

Christian versus Muslim Body Attitudes

While both post-medieval Christians and Muslims buried their dead in simple pit graves dug into earth, each group employed distinctive practices concerning how the bodies were laid out (body attitude) and what might accompany them into a prospective afterlife. Earlier cemetery excavations in and overlying remains of the Frankish city of Ancient Corinth, directed by Charles K. Williams II, provided the first evidence at the site for distinguishing Muslim-style from Christian burials.[21] Several additional graves subsequently excavated under the direction of Guy Sanders have helped in the identification of specific characteristics of both kinds of burial practices.[22] The marked differences observed in funerary practice and behavior surely reflect the different belief systems of Muslims and Christians. As noted above, the bodies of Muslims at Corinth, as elsewhere, communicated with Mecca, and the graves were oriented so that inclination of the body or head to the right directed the gaze of the deceased toward Mecca. Christian burials, on the other hand, are oriented east–west, with the head at the west and the arms crossed over the pelvis or chest.[23]

These characteristics can be further refined in the present study of the 17th-century cemetery at Panayia Field. Muslims arranged the bodies of their deceased at Corinth in a northeast–southwest orientation in extended fashion on their backs, heads toward the southwest or west, arms extended at the sides with palms placed down and next to the hips, and with legs separated, indicating that the feet had not been tied together (Fig. 10). Heads more often pointed toward the southwest rather than the western orientation characteristic of most Christian burials. This more southwesterly orientation permitted the heads, when turned to their right, to face more accurately toward Mecca. In the majority of Muslim-style burials (five out of eight cases for which skulls were present), the heads had been turned onto their right sides to face southeast and hence look toward Mecca (Fig. 11). In only three cases did the heads face upward. Sometimes the torsos and legs even twisted slightly onto the right side.

21. Specifically, 25 burials from the excavations southeast of Temple E. See Williams and Zervos 1991, pp. 39–40; Barnes 2003, p. 436; Barnes, in prep.

22. Blackman 1999, p. 32.

23. See Insoll 1999, pp. 166–200; also Marks et al. 1997 for burials in Crimea: in cemeteries roughly contemporary with that at Corinth, both Christian and Muslim groups rarely employed wooden coffins and only occasionally lined the grave pits with stones.

This content downloaded from 78.100.65.226 on Fri, 11 Oct 2013 01:17:53 AM
All use subject to JSTOR Terms and Conditions

Figure 10. Muslim-style burial in grave 27 showing orientation, placement of the head toward the southwest, and arms extended with hands palms down

Each individual usually occupied his or her own grave solely. In only two of 11 Muslim-style graves had one earlier burial been disturbed, and in both cases the older remains had been simply pushed to one side (Fig. 12) rather than exhumed and redeposited as was typical of Christian practice. A small metal bead or button was found with an infant burial in grave **78**; all other Muslim graves were devoid of any nonperishable burial accompaniments such as jewelry and personal items. Grave **78** also differs from the majority of Muslim burials in the position of the individual's head, facing upward (see also graves **1**, **32**). However, the arm and leg positions fit better within the Muslim pattern than the Christian pattern.

By contrast, Christian burials favored an east–west orientation with the bodies extended on their backs and heads to the west. Heads either faced upward or had been propped up somewhat on earthen mounds to face east toward their feet in order to be prepared for the ultimate day of resurrection. Arms were crossed over the chest or abdomen (Fig. 13), while the ankles tended to lie nearer one another, suggesting that in some instances they may have been tied together. It was common for Christians to exhume an individual, presumably a relative, from an existing grave in order to inter a newly deceased person in that grave. They then redeposited the bones of any previous occupants on top of the latest burial before refilling the grave (Fig. 14).

The reuse of existing graves characterizes half (25 of 50 clear cases) of the Christian graves in the northeastern section of the Panayia Field cemetery; 11 of the 17 unassigned graves from the same cemetery yielded redeposited bone piles (see below), probably reflecting similar reuse since such bone piles do not occur in Muslim-style graves. Personal items attached to clothing, such as jewelry or cleats to reinforce boots, often accompanied the Christian dead. Mourners apparently also deposited coins with the corpse or in the grave fill, presumably to pay "the ferryman" during the journey into afterlife. Although this practice represents a pre-Christian concept, Greek Orthodoxy has retained the idea of Charon as an emblem representing death and an afterworld.[24]

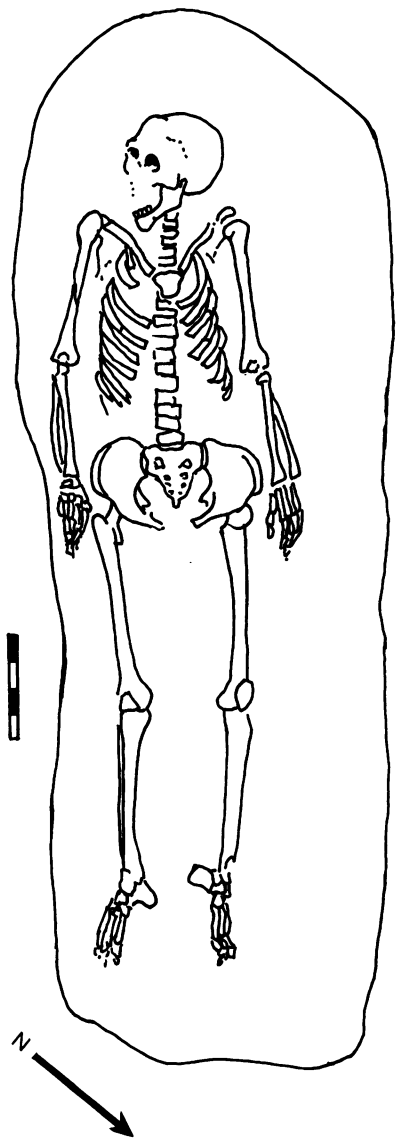

24. Rush 1941, p. 94.

This content downloaded from 78.100.65.226 on Fri, 11 Oct 2013 01:17:53 AM
All use subject to JSTOR Terms and Conditions

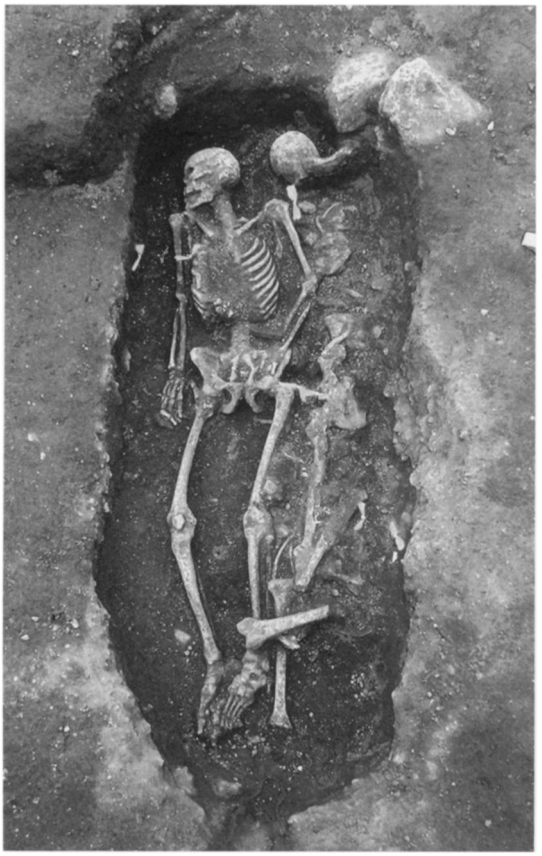



Figure 11 *(opposite)*. **Muslim-style burial in grave 10, with head facing Mecca. The ankles are separated, indicating that the feet had not been tied together.** Drawing E. Barnes

Figure 12 *(above, left)*. **Muslim-style burial reusing earlier grave in grave 70. The bones of the earlier occupant have been pushed to one side.**

Figure 13 *(above, right)*. **Christian-style burial in grave 23, with head to the west and arms crossed over the chest**

Figure 14 *(right)*. **Christian-style burial in grave 26, showing the reuse of an earlier grave with bones of the earlier occupant(s) redeposited on top of the latest burial**

This content downloaded from 78.100.65.226 on Fri, 11 Oct 2013 01:17:53 AM
All use subject to JSTOR Terms and Conditions

Another practice found at Corinth only in Christian-style graves is the use of stone blocks to flank the heads of interred bodies and occasionally to span the space over the head between the flanking stones, creating a sort of niche. As noted earlier, 20 instances were found in which a pair of stone blocks had been arranged as a frame, one on each side of the head, but rarely near enough to support the head from rolling to one side or the other after rigor mortis relaxed (Fig. 15). Ten of those stone frames supported a third, flatter, stone that spanned the space between them and covered the head (Figs. 16, 17). This feature was observed in burials of all ages, from infants to adults. Of the remaining Christian-style burials, only 18 retain their skulls (the others had been disturbed), so we can suggest that they may have been buried without the flanking stones. In one burial, that of a child in grave **24**, two small stones were seen to the right of the skull.

None of the practices for lining graves observed in earlier Christian-style graves excavated at Ancient Corinth appeared in the 17th-century Panayia Field cemetery. These practices include complete or only partial lining of the grave sides and ends with large ceramic tiles or tile fragments and the covering of all or just the upper parts of the body, again with ceramic tiles. This pattern had existed in some Classical and Roman graves, and it has been traced through Early and Middle Byzantine times, through the period of Frankish government, and into the early post-Frankish period when the portion of the body enclosed or covered by tiles steadily decreased until the practice gradually died out. For a short time during the period of Frankish rule, mourners placed small stones, broken tile fragments, or even potsherds beneath the chins of the deceased to prevent their mouths from falling open after relaxation of rigor mortis. We found no occurrences of chin props in the Panayia Field cemetery. In fact, most mouths gaped widely (Fig. 17).

Stone or tile props designed to elevate the head to face eastward and keep it from rolling to either side had been commonly used in earlier times, but appear to have been replaced in the Panayia Field cemetery by stones framing or flanking the heads or forming a crude niche into which the head fit. Within this niche, the heads often tilted somewhat toward one side or the other. With one exception—grave **76** in which a stone lay beneath the head of the burial—any propping of the head to face east relied solely on earthen lumps.

Even the bodies had been prepared slightly differently from those in the earlier cemeteries. While forearms were still folded across the torso, usually perpendicular to the spine, the hands often clasped the opposing wrists, which may have been bound together, causing the elbows to flare outward from the body (Fig. 18). We also observed a tendency for hands to have been closer to the pelvis than in earlier times. Both legs extended fully from the hips, but ankles sometimes remained separated as if the feet had not always been bound together, as they seem to have been both before and after the use of this early 17th-century cemetery.

Employing these criteria, we have sorted the 17th-century Panayia Field graves into 11 Muslim-style graves and 55 Christian-style graves. Nine of the unassigned graves probably represent badly disturbed Christian-style burials or remnants of them. The remaining six graves reflect neither pattern and seem to express individual circumstances.

Figure 15 ***(top left)*****. Christian-style burial in grave 25, with stone blocks framing the head**

Figure 16 ***(top right)*****. Christian-style burial in grave 54, with stone framing blocks and slab covering head**

Figure 17 ***(bottom left)*****. Christian-style burial in grave 62, with the head in a stone niche and illustrating the absence of a chin prop**

Figure 18 ***(bottom right)*****. Christian-style burial in grave 44, illustrating the positioning of opposing wrists**

This content downloaded from 78.100.65.226 on Fri, 11 Oct 2013 01:17:53 AM
All use subject to JSTOR Terms and Conditions

This content downloaded from 78.100.65.226 on Fri, 11 Oct 2013 01:17:53 AM
All use subject to JSTOR Terms and Conditions

Unusual Features

The excavation of several apparent grave outlines revealed piles of disarticulated bones that at first resembled secondary burials. In the broader context, however, these remains more closely resemble bone piles redeposited on top of more recent Christian interments. In grave **35**, for example, a bone stack rested atop another grave (**50**) and two remnant graves (**64, 68**). Similarly, grave **45** (Fig. 19) contained a stack of bones representing five individuals later found to directly overlie the feet and legs of an articulated burial that extended beneath the edge of the trench scarp and hence could not be excavated. As noted above, the bone stacks mark these graves as probable Christian burials. Graves **3**, **5**, **6**, and **15** also seem to reflect this pattern, although the excavators encountered no articulated burials beneath them. Grave **47** (Fig. 20) contained only a remnant burial similar to graves **64** and **68**.

We assigned the label "grave **40**" to an isolated skull that appeared beneath the floor of an early-19th-century farmhouse in anticipation of finding the rest of the body deeper beneath the floor. When only the matching mandible and fragments of another skull appeared, we began to suspect that this skull and mandible had been displaced from some other grave. Consequently, it stands alone.

Grave **72** contained the skeleton of a young male (14–15 years old) stretched out on his back with his head toward the west but severely twisted backward and onto its left side to face northwest (Fig. 21). The arms crossed the upper chest in an awkward manner, causing the left hand to appear to clasp the neck while the right hand pressed against the right side of the chest from a widely flaring right elbow. Perhaps rigor mortis had set in before the young man's family could properly arrange his body position. In any event, we cannot satisfactorily identify the burial position as fitting either a Muslim or a Christian pattern.

Grave **8** contained the skeleton of a 25–27-year-old woman arranged in a semiflexed position on her right side (Fig. 22). Her thighs were bent at about an 85° angle from her spine, with her knees also bent at 85° and about 30° from the thighs, placing her feet quite far apart. Her right humerus (upper arm) projected southward at a right angle to the spine, but the rest of the arms were missing. This body position matches neither Muslim nor Christian practice, although the positioning on the right side with the head facing south could be seen as a Muslim-like quality. However, since two burials had been found in the same grave pit (grave **7** intrudes into grave **8**), and elements of the two children in grave **7** were intermingled with the bones in grave **8**, this suggests grave reuse in the Christian pattern, with redeposition of bones of earlier burials on top of the most recent interment.

As excavators were carefully sweeping to define the edges of graves **56** and **62**, the skeletons of two newborn babies appeared. In neither case could a grave outline be discerned. Grave **60** consisted of one of the newborns' thoracic cavity, with vertebrae and ribs indicating that the body had been placed on its back with the head toward the west, possibly a Christian-style burial arranged in the same manner as other burials in the vicinity. Grave **61** represented a newborn lying in a semiflexed position on the left

Figure 19 *(top left)*. **Redeposited bones of four individuals on top of the legs of articulated burial in Christian-style grave 45**

Figure 20 *(top right)*. **Remnant burial in grave 47**

Figure 21 *(bottom left)*. **Burial in grave 72, illustrating possible evidence of rigor mortis**

Figure 22 *(bottom right)*. **Semiflexed adult burial on right side in grave 8**

This content downloaded from 78.100.65.226 on Fri, 11 Oct 2013 01:17:53 AM
All use subject to JSTOR Terms and Conditions



This content downloaded from 78.100.65.226 on Fri, 11 Oct 2013 01:17:53 AM
All use subject to JSTOR Terms and Conditions

Figure 23 *(left)*. Semiflexed newborn burial on left side in grave **61**

Figure 24 *(bottom left)*. Detail of young male in grave **20**, showing iron hook beneath left clavicle. Drawing E. Barnes

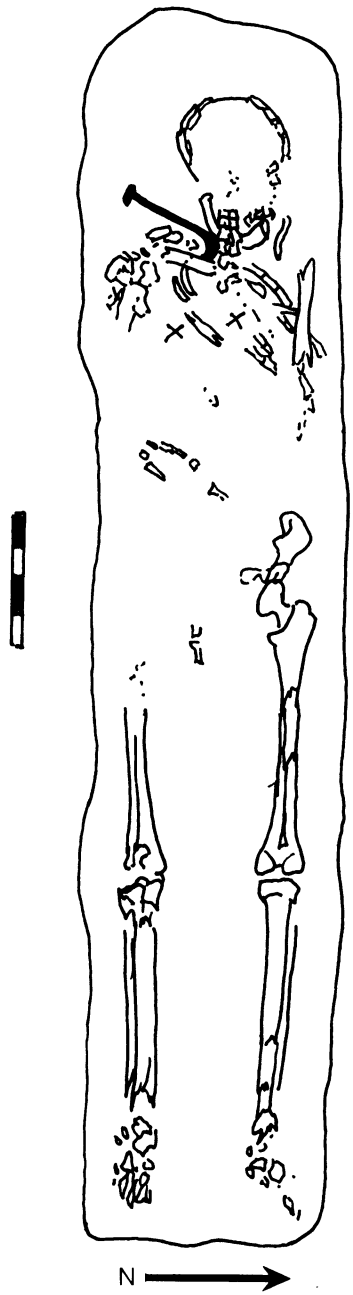

Figure 25 *(bottom right)*. Burial of downward-facing young male in grave **20**. The findspots of burial accompaniments are marked by X. Drawing E. Barnes

This content downloaded from 78.100.65.226 on Fri, 11 Oct 2013 01:17:53 AM
All use subject to JSTOR Terms and Conditions

side of its back with head pointing toward the west. Its legs had been bent at an angle of about 100° at the knees (Fig. 23). Neither grave contained any burial accompaniments.

Grave **20** contained the body of a young 20–21-year-old male lying extended with his head pointing westward, but face down (Figs. 24, 25). A thick iron rod projecting out of the left side of his neck turned out to be an iron hook that had been inserted into his left shoulder beneath his left clavicle (collarbone). Apparently, he had been suspended from this hook until he died, because both legs and feet extended fully and parallel to one another as they would have while he hung and rigor mortis set in. His right hand had balled up into a fist that clutched the spot where the hook had been inserted into his shoulder. His left arm dangled behind his back. Presumably, once he had died, his punishers had taken down his rigid body and placed it face down (a position of disgrace?) into his final resting place, leaving the hook still embedded. We suspect this represents a death sentence for an individual who defied the order of the local governing body. Ottoman rule at Ancient Corinth during the early 17th century apparently tolerated Christian religious practice, but only as long as the Christians obeyed their rulers and did not cause trouble for them.

Burial Accompaniments

Workmen excavating the Panayia Field cemetery graves recovered 33 coins and coinlike objects from 21 graves (see Appendix), found either directly in association with the skeletons or in the fill above them. Three other coins were found in two outlying graves (**82**, **85**). Clearly some coins had been placed on specific parts of the body such as the chin (graves **46**, **73**) or upper lip (grave **58**), under the jaw but not in the mouth (grave **29**), near the skull (grave **42**, cupric stain), at the hip (grave **69**), near a leg (graves **30**, **63**), and on (grave **76**) or under (grave **63**) the body. Such placements represent conscious actions on the part of mourners. Other coins had been added—probably in most cases intentionally—to the grave fill as the grave was refilled. Nine of these 21 graves also contained other burial accompaniments. All the graves that contained coins or other burial accompaniments fit into the Christian burial style.

The unusual burial in grave **20** with the iron hook was accompanied by a curious set of objects that apparently had hung around the individual's neck when he died (Fig. 26). These items include a tightly-packed stack of five Turkish *akches,* a highly polished bone slab in the shape of a long parallelogram perforated in the center (6.2 × 1.2 × 0.1–0.2 cm with a 0.3 cm biconical perforation) and exhibiting a strong green cupric stain, a small loop of bronze wire bent into a crude circle (1.7 × 1.6 × 0.2 cm) although the ends do not meet, and a roughly D-shaped bronze loop (4.1 × 3.1 × 0.2–0.25 cm). Undoubtedly, the bone piece's cupric stain derived from contact with the associated bronze pieces. This would seem to be a strange sort of necklace, but the presence of all these diverse pieces together beneath the individual's upper chest and left collarbone argues for their combination into some sort of neckpiece.

Other than coins, virtually all the recovered nonperishable burial accompaniments represented personal belongings such as attachments to

This content downloaded from 78.100.65.226 on Fri, 11 Oct 2013 01:17:53 AM
All use subject to JSTOR Terms and Conditions

Figure 26. Objects accompanying the young male burial in grave 20. Top row: five coins (2001-189, 2001-190, 2001-191, 2001-192, 2001-193); middle row: perforated worked bone object and two metal rings; bottom: iron hook (MF-2001-26). Scale 1:2

Figure 27. Objects accompanying burials. Upper left and right: bronze rings (MF-2001-34, MF-2001-35) with adult male in grave 50; upper center: small lead weight (MF-2001-33) with child in grave 63; center: iron belt buckle (MF-2001-32) with adult male in grave 57; bottom: bronze "nail" (MF-2001-38) found in grave fill above adult female in grave 26. Scale 1:2

clothing or items of jewelry. Presumably, these items indicated that the dead had been dressed before burial, whether or not a shroud encased them for their final journeys. The most obvious clothing items include an iron belt buckle (Fig. 27: MF-2001-32) at the right side of the waist of the 45–55-year-old male in grave **57**, a round-headed bronze pin (perhaps for fastening a garment) with the two women in grave **75**, two metal hooks, one in an eyelet (to secure a shirt or cape?), at the right rib cage of grave **79**, and a single eyelet in grave **71**. A pair of ornamental bronze rings found just below the knees of a 40–50-year-old male in grave **50** look as if they had once been attached to the ends of knee-length trousers (Fig. 27: MF-2001-34, MF-2001-35). Perhaps the bronze "nail" with a square shank (Fig. 27: MF-2001-38) found with the male and female in grave **26** was some form of fastener for a garment.

Horseshoe-shaped iron objects with sets of prongs on one side can be readily identified from their contexts as metal reinforcements for the heels of footwear, most likely boots. Boot cleats were formed as flat, semicircular iron strips, wider in the middle than at the ends. Sharp prongs projected from one flat surface to allow the cleat to be hammered into the underside of the boot heel. We found one pair each standing upright between the heels of the 15–16-year-old male in grave **11** (Fig. 28) and the 6–7-year-old

This content downloaded from 78.100.65.226 on Fri, 11 Oct 2013 01:17:53 AM
All use subject to JSTOR Terms and Conditions

Figure 28. Iron boot-heel reinforcements with adolescent in grave 11. Scale 1:2

Figure 29. Iron boot-heel reinforcements with child in grave 28 (top, lower left: MF-2001-30A, B) and near female adult in grave 30 (lower right). Scale 1:2

child in grave **28** (Fig. 29: MF-2001-30A, B), as if both had been wearing boots when interred. A single boot cleat standing upright at the right heel of the 30–40-year-old female in grave **30** (burial A), another under the left foot of an over-50-year-old woman burial in grave **75** (burial A), and another by the left foot of the 22–24-year-old male burial in grave **81** (burial A) suggest only one boot heel needed reinforcement in each case. Four additional boot cleats (one shown in Fig. 29, lower right) clustered beyond the feet of burial A in grave **30**, where they most likely had been deposited when the disarticulated male burial B in grave **30** was redeposited over the woman's legs and feet. The remaining boot cleats came from disturbed contexts between the legs of the 35–40-year-old male in grave **42** (two specimens) and in the fill of grave **66** containing the skeleton of a 14–15-year-old adolescent boy.

Most cleats had three prongs but one pair had five visible prongs, spaced in such a way to suggest that originally there had been six (Fig. 28). Sizes seemed to vary according to the size of the boot, and probably its wearer. The smallest cleats accompanied the 6–7-year-old child in grave **28** and measure 6.2–6.5 cm across the ends of the horseshoe, 4.7–4.9 cm from the ends to the center of the arch, 1.0 cm wide at the ends, and 1.3 cm wide in the middle, with four prongs each (Fig. 29: MF-2001-30A, B). For comparison, the larger cleats (Fig. 28) are 7.0–8.0 cm across the open ends and 5.0–6.5 cm deep from the ends to the center, with strip widths

This content downloaded from 78.100.65.226 on Fri, 11 Oct 2013 01:17:53 AM
All use subject to JSTOR Terms and Conditions

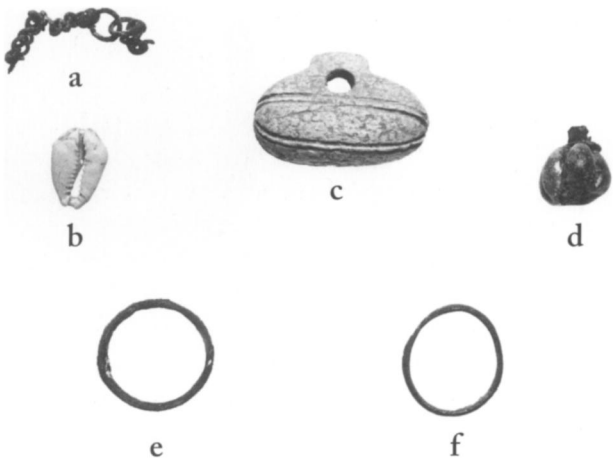

Figure 30. Objects accompanying burials: (a) bronze chain and (b) small cowrie shell (both MF-2002-28) with infant from grave 77; (c) melon-bead pendant (MF-2001-39) with young adult male from grave 29; (d) melon bead (MF-2001-31) with child from grave 63; (e) finger ring (MF-2001-36) with adult female from grave 46; (f) finger ring (MF-2001-37) with adult female from grave 44. Scale 3:4

varying from 0.9 to 1.3 cm. Each individual boot maker seems to have had his own style for making and attaching these items.

Our evidence certainly suggests that both males and females wore boots, and that even children began to wear them at a young age. While most of the heel cleats accompanied six males and one small child (a boy?) into their graves, at least two women also wore boots. Whether the boot-heel cleat found in grave **75** with burial A belonged to that individual or had been redeposited along with the redeposited bones from burial B in the grave, the object accompanied a woman.

In 1668, at the end of the Panayia Field cemetery's use, Evliya Çelebi observed of the Corinthian Christian population that "the young men dress like Algerians, in tight fitting clothes, and walk barelegged, wearing a red fez, and with a two-edged knife at the waist. On their feet they wear black Frankish boots. The women wear cloth mantles of many colors and wide-brimmed hats bound with a white kerchief."[25] "Frankish boots" refers to a style imported from the west. Would some of these boots have sported iron heel cleats? Walking "barelegged" might suggest trousers cinched at or just below the knees. A round-headed bronze pin would have been ideal for fastening a mantle or even for securing a hat to one's hair. The iron knife blade fragment recovered from grave **41** could have originally belonged to any one of the three burials within it—the 5.5–6.5-year-old child, the 12–13-year-old male, or the adult for whom only the skull remains. The knife, too, fits the description cited above.

Items of jewelry accompanied 10 separate burials. Two bronze rings (Fig. 30:e, f) were discovered in place, accompanied by strong cupric stains, on or near the fourth finger of the right hand on female burials in graves **44** and **46**; the individuals lay just over a meter apart, east–west. Both rings measure 2.0 cm in diameter, while the plain band without a visible joint (MF-2001-36) on the burial in grave **46** has a thickness of 0.5 cm.[26] The band on the burial in grave **44** (MF-2001-37) is 0.3 cm thick without any visible joint and has a slightly convex section while, in place of a bezel, a rectangular hole, possibly covered by a thin slice of glass, may have been used for a setting. Greek women and men traditionally have worn, and still do wear, their wedding bands on the fourth finger of the right

25. MacKay 1968, p. 393; MacKay n.d., folio 259a, lines 14–16. We would like to thank Pierre MacKay for generously allowing us to refer to his unpublished manuscript.

26. This specimen resembles *Corinth* XII, p. 230, type J, nos. 1908–1913, dated to the Byzantine period.

This content downloaded from 78.100.65.226 on Fri, 11 Oct 2013 01:17:53 AM
All use subject to JSTOR Terms and Conditions

Figure 31. Necklace (MF-2001-40) and perforated Nuremberg jetons (coins 2001-196, 2001-199, and 2001-200) found with young adolescent in grave 33. Scale ca. 1:2

hand. A plain ring, fashioned from iron and mended from three fragments (MF-2001-43), accompanied the preadolescent burial in grave **54**, burial A.

Grave excavators found elaborate necklaces around the necks of two children (Figs. 31, 32). Each consisted of a string of glass paste or faience beads plus additional pendants, although the precise locations of the pendants could not be discerned. Both necklaces contained a mix of thicker (0.3–0.4 cm) and thinner (0.2 cm) beads in different colors. Presumably, the thicker beads occupied the front center of each necklace with the smaller and thinner beads toward the back. The 10–11-year-old child in grave **33** had worn a necklace consisting of at least 135 small dark blue and white beads, alternating in color, together with three jetons (Fig. 31). During restringing of these beads for photography, the conservator found a short piece of fine bronze wire inside the perforation of one bead. Thus, we can conclude that the necklace had originally been strung on fine bronze wire. Restringing this set of beads produced a strand at least 37.7 cm long. All three jetons (coins 2001-196, 2001-199, and 2001-200) were Nuremberg issues that had been perforated near one edge, probably to be strung together with the beads. Jetons served as counters for checkerboards (as used by accountants), and as gaming tokens, and they could also have passed as money.

The 12–13-year-old preadolescent (burial A) in grave **54** sported a necklace consisting of at least 186 small round glass beads in white, yellow, and dark blue colors (MF-2001-27) plus three perforated cowrie shells (MF-2001-28A–C), a fluted globular glass paste or faience melon bead with bronze caps (part of MF-2001-27), and a perforated Nuremberg jeton, coin 2001-211 (Fig. 32). When restrung, this necklace reached at least 54.2 cm in length. We found no direct evidence for the original stringing material. The back of all three shells had been broken out and the broken edges smoothed by grinding or polishing. Their lengths are 2.2, 2.0, and 1.6 cm, respectively.

Why might the two most elaborate pieces of jewelry discovered have adorned these two young persons, while older people had only single beads or no jewelry at all? Both of these young persons did lie in graves with their heads between framing stones, but this feature alone is hardly sufficient to represent a status symbol.

Single beads or pendants occurred in five other graves where they may have once functioned as solitary pendants. A single small cowrie shell (Fig. 30:b) accompanied an infant skull in grave **77** while a fragment of bronze chain (Fig. 30:a), 3.0 cm long and 0.3 cm thick, found among the secondarily deposited bones upon which the skull rested, suggests that the shell once hung from a bronze chain around the infant's neck, presumably at the time of burial. The back of this shell had also been deliberately fractured, but its broken edges had not been smoothed down. It measured only 1.4 cm long. A lone dark blue glass paste or faience melon bead (MF-2001-31), measuring 1.5 cm high and 1.4 cm in diameter with a 0.3 cm diameter hole, and with bronze caps and an iron rod holding the various parts together (Fig. 30:d), appeared at the right rib cage of the child

This content downloaded from 78.100.65.226 on Fri, 11 Oct 2013 01:17:53 AM
All use subject to JSTOR Terms and Conditions

in grave **63** where it probably came to rest from its original position over the chest. This bead is virtually identical to the melon bead that comprised part of the necklace for burial A in grave **54** (Fig. 32). Hence, it too probably served as a pendant hung around the neck.

Another melon-shaped bead fashioned from bone or ivory (Fig. 30:c) was recovered from the lower leg region of grave **29**, containing a young adult male, where it certainly could not have been in place as a pendant worn around the neck, unless its cord broke during interment. The bead itself (MF-2001-39), measuring 3.1 × 2.0 × 1.3 cm, had been suspended by a hole through a raised flange in the middle of one long side.[27] Four pairs of straight longitudinally incised lines ornament the bead at regular intervals around its circumference. Despite its unlikely findspot, this piece most surely was once a pendant.

Grave **30** yielded a large cube-shaped light blue faience bead with a large biconical perforation in its center, whose only apparent function must have been as a single bead worn around the neck, wrist, or ankle. This bead measures roughly 1.5–1.6 cm on each side, so it would have been most comfortable dangling from a cord around the neck. Since this grave contained both an articulated skeleton of an adult female and the disarticulated skeleton of a slightly younger adult male, and the bead came from the foot area of the grave, it is more likely that it belonged to the earlier, male burial.

A small metal buttonlike bead in infant grave **78** turned up at the individual's left temporal. Marked by a strong green cupric stain on the temporal bone, it appears to have functioned as an earring even though no mate for it was found. Interestingly, this specimen provides the only possible case for an earring having adorned one of the dead in this cemetery, even though earrings occurred several times in the earlier Frankish cemetery.

One final piece of jewelry in the form of a long ovoid yellowish-orange glass gem, approximately 0.8 cm long, appeared beneath the ribs of burial A, a 30–35-year-old male, in grave **34**, where it could have fallen from either hand. No ring with a missing setting came from this grave, however, and the gem's occurrence presents a mystery.

Other personal items found with the dead include the iron knife blade fragment mentioned above from grave **41** and both a small lead weight (Fig. 27: MF-2001-33) and half of a blue steatite spindle whorl found in grave **63** along with three coins (2001-212, 2001-213, 2001-217), and the single faience melon bead illustrated above (Fig. 30:d). Articulated remains of a 5–6-year-old child with redeposited adult bones from intrusive grave **30** occupied this grave.

The only adult Muslim-style burial to contain any kind of nonperishable accompaniment was in grave **70**, where a miniature terracotta female head lay face down on the pelvis of the 39–44-year-old male whose later burial had disturbed that of a 30–35-year-old male. This item, as well as coins 2002-19 from Theodosius I (A.D. 388–393) and 2002-20 from John II (A.D. 1118–1143), was found in the grave fill and appears to represent older material employed in filling the grave rather than offerings made to the grave occupants.

Figure 32. Necklace (MF-2001-27) with three shells (MF-2001-28A–C), a glass paste or faience melon bead with bronze caps (MF-2001-27), and a perforated Nuremberg jeton (coin 2001-211) found with preadolescent burial A in grave 54. Scale 1:3

27. This bead closely resembles *Corinth* XII, p. 262, no. 2123.

This content downloaded from 78.100.65.226 on Fri, 11 Oct 2013 01:17:53 AM
All use subject to JSTOR Terms and Conditions

OSTEOLOGICAL ANALYSIS

Most individuals buried singly or placed last in a grave represented complete or fairly complete skeletons, while those found in disturbed graves and redeposited burials often consisted of incomplete skeletons. Most infant skeletons were fragmented from ground damage. Some graves contained extra bones and bone fragments from other disturbed burials inadvertently deposited in newly opened graves. Those extra bone elements that did not match up with any reburied individuals have been excluded from the sum total of identified individuals. Careful separation by excavators of each burial or of commingled redeposited bones apart from the last burial within a grave greatly facilitated analysis; otherwise, it would not always have been possible to discriminate individuals buried in the same grave had their remains arrived at the laboratory mixed in the same container. Redeposited skeletal remains of more than one individual that could not be separated in the field or the laboratory have been treated as commingled remains.

Skeletal remains for each individual represented were inventoried and analyzed for as much information as possible (see catalogue). The information gleaned from partial or fragmented skeletal remains was sometimes minimal, while more complete skeletons were more illuminating. Adults and older adolescents were analyzed for age, sex, stature, cranial morphology, dental pathology and anomalies, skeletal pathology and developmental variants, and signs of functional stress reflecting habitual behaviors. Children and infants were also analyzed for age, dental and skeletal pathology, and developmental variants. Some children showed signs of functional stress as well. Variations in dentition and skeletal development were assessed for genetic familial relationships, while cranial shapes were assessed to determine if the cemetery sample contained a mixed or homogeneous population.[28]

Demography

The 81 graves in the Panayia Field cemetery yielded 133 individuals: 79 adults, 9 adolescents, 6 preadolescents, 20 children, and 19 infants. Overall, male adults and adolescents outnumber females by a proportion of 7:3, and among the 25–35-year-olds by almost 8:1 (Table 1). Generally in a cemetery sample of this size, females outnumber males. Infants

28. Multiple criteria used for assessing adult ages include dental wear (Brothwell 1981, p. 72), pubic symphysis morphology (Bass 1987, pp. 194–195), presence of spinal degenerative joint disease, ossification of rib end cartilage (Bass 1987, pp. 134–141), and sometimes endocranial suture closure (Krogman 1962, p. 869). Fusion of epiphyses from growing bones helped in assessing age for older adolescents and young adults (Krogman 1962, pp. 28–55). Dental development (Gorlin, Pinborg, and Cohen 1976, pp. 779–780) plus long bone diaphyseal lengths provide criteria for aging children and infants based on Barnes's measurements of juvenile bones from individuals with known dental age gathered from other skeletal populations from Corinth. Multiple criteria were used to sex adults and adolescents (Ubelaker 1978, pp. 42–44), such as gracile versus robust bones, femoral head diameter (Bass 1987, p. 220), sciatic notch width, and pubic arch angle. Stature estimates were based on the length of one or more long bones, preferably the tibia or femur, using a regression formula developed by Trotter and Gleser (1952, 1958). Cranial shape descriptions are based on criteria developed by Rogers (1984, pp. 75–76), and standard cranial index categories: mesocrany (medium), brachycrany (broad or round), hyperbrachycrany (very broad), and dolichocrany (long) (Bass 1987, p. 69). Functional stress was inferred from signs of repetitive overuse of muscle tendons, ligaments, and joints.

This content downloaded from 78.100.65.226 on Fri, 11 Oct 2013 01:17:53 AM
All use subject to JSTOR Terms and Conditions

TABLE 1. DEMOGRAPHIC PROFILE

Age Group	♀*F*	♂*M*	♀♂	*Total*
Adults				
>54 years	6	2	—	8
45–54	1	9	—	10
36–44	6	9	—	15
30–35	1	17	—	18
25–29	2	6	—	8
19–24	4	7	—	11
Unknown	3	4	2	9
Subtotal	23	54	2	79
Adolescents				
16–18 years	2	2	1	5
14–16	—	4	—	4
Subtotal	2	6	1	9
Preadolescents				
11–13 years	—	—	6	6
Subtotal	—	—	6	6
Children				
8–10 years	—	—	6	6
5–7	—	—	7	7
3–4	—	—	4	4
Unknown	—	—	3	3
Subtotal	—	—	20	20
Infants				
24–36 months	—	—	4	4
18–24	—	—	2	2
12–18	—	—	3	3
6–12	—	—	2	2
3–6	—	—	1	1
1–3	—	—	2	2
Newborn	—	—	4	4
Unknown	—	—	1	1
Subtotal	—	—	19	19
Total	25	60	48	133

represent less than 15% of the total number, a rather small percentage for this sample size. The greatest number of adult male deaths occurred during their prime years—30s to early 40s—while more females died in later years.

Life expectancy was calculated on the basis of a sample of 105 individuals, excluding adults of unknown age and infants (Table 2). The exclusion of infants from the calculations presents a more realistic picture of the chances for survival from childhood into adulthood, because pre-20th-century populations generally lost high numbers of infants and compensated for that by having more children. Adolescence was reached by three-quarters of the children, while about half of young adults survived into their prime

This content downloaded from 78.100.65.226 on Fri, 11 Oct 2013 01:17:53 AM
All use subject to JSTOR Terms and Conditions

TABLE 2. LIFE EXPECTANCY

Age at Death	*%*	*n*	*Projected Survival Frequencies*	*%*	*n*
Childhood					
3.5–13 years	25	26	Surviving beyond childhood	75	79
Adolescence					
14 –18 years	9	9	Surviving beyond adolescence	67	70
Young adulthood					
19–24 years	10	11	Surviving beyond young adult	56	59
Prime adulthood					
25–44 years	39	41	Surviving beyond prime years	17	18
Middle age					
45–55 years	10	10	Surviving beyond middle age	8	8
Old age					
>55 years	8	8			

Life expectancy based on a sample of 105 individuals with known ages, excluding infants.

years. Only 17% of this population reached middle age, and 8% lived to old age, most of those being women.

Stature estimates using a regression formula based on the length of long bones provide approximate heights, accurate to within a few centimeters (Table 3). Stature estimates for 45 males from the Panayia Field cemetery range from 178.00 cm (5′8″) to 159.85 cm (5′2″), with nearly 50% of male statures falling between 175.10 cm (5′7″) and 169.42 cm (5′6″). Stature estimates for 19 females range from 171.18 cm (5′6″) to 146.84 cm (4′8″), with most female statures falling between 159.84 cm (5′2″) and 155.27 cm (5′1″).

TABLE 3. ADULT STATURES

	Height (cm)	*Height (ft/in)*	*n*	*%*
MALES				
	178.00–175.50	5′8″	7	15.55
	175.10–172.39	5′7″	10	22.22
	171.55–169.42	5′6″	11	24.44
	168.08–166.63	5′5″	7	15.55
	165.87–163.43	5′4″	7	15.55
	161.58–160.72	5′3″	2	4.44
	159.85	5′2″	1	2.22
Total			45	
FEMALES				
	171.18	5′6″	1	5.26
	164.76	5′4″	1	5.26
	159.84–157.07	5′2″	8	42.10
	156.84–155.27	5′1″	4	21.05
	153.36	5′0″	1	5.26
	151.72–151.42	4′10″	3	15.78
	146.84	4′8″	1	5.26
Total			19	

This content downloaded from 78.100.65.226 on Fri, 11 Oct 2013 01:17:53 AM
All use subject to JSTOR Terms and Conditions

TABLE 4. CRANIAL INDEXES AND SHAPES FOR ADULT MALES AND FEMALES

Grave	*Style*	*Cranial Index*	*Cranial Shape*
Males			
23	Christian	112.99[a]	Hyperbrachycrany
26B	Christian	103.73	Hyperbrachycrany
25A	Christian	97.53	Hyperbrachycrany
29	Christian	92.26	Hyperbrachycrany
5A	secondary[b]	91.07	Hyperbrachycrany
32	Muslim	90.96	Hyperbrachycrany
42D	Christian	87.15	Hyperbrachycrany
42B	Christian	86.34	Hyperbrachycrany
58	Christian	85.33	Hyperbrachycrany
45A	Christian	85.14	Hyperbrachycrany
70A	Muslim	83.61	Brachycrany
80A	Christian	—	Brachycrany
54B	Christian	83.15	Brachycrany
17A	Christian	82.66	Brachycrany
76	Christian	82.45	Brachycrany
21	Christian	82.08	Brachycrany
81B	Christian	81.92	Brachycrany
57A	Christian	81.87	Brachycrany
2B	Muslim	80.87	Brachycrany
17B	Christian	80.56	Brachycrany
16	Christian	—	Brachycrany
49	Christian	—	Brachycrany
30B	Christian	79.89	Mesocrany
5C	secondary[b]	79.23	Mesocrany
45C	Christian	77.59	Mesocrany
81A	Christian	77.40	Mesocrany
27	Muslim	76.40	Mesocrany
70B	Muslim	76.11	Mesocrany
35A	secondary[b]	75.54	Mesocrany
45B	Christian	75.28	Mesocrany
7A	Christian	—	Mesocrany
42A	Christian	—	Mesocrany
50	Christian	—	Mesocrany
57B	Christian	—	Mesocrany
34A	Christian	—	Mesocrany
67	Christian	74.46	Dolichocrany
48	Christian	—	Dolichocrany
34B	Christian	74.05	Dolichocrany
34C	Christian	—	Dolichocrany
5B	secondary[b]	—	Dolichocrany
66	Christian	—	Dolichocrany
Females			
75B	Christian	85.71	Hyperbrachycrany
8	disrupted[c]	83.13	Brachycrany
80B	Christian	82.58	Brachycrany
75A	Christian	82.48	Brachycrany
1	Muslim	80.55	Brachycrany
2A	Muslim	—	Brachycrany
10	Muslim	79.10	Mesocrany
42C	Christian	—	Mesocrany
40	unassigned	79.07	Mesocrany
26A	Christian	78.41	Mesocrany
59A	Christian	78.03	Mesocrany
62	Christian	77.53	Mesocrany
30A	Christian	—	Mesocrany
35C	secondary[b]	75.84	Mesocrany
38	Christian	75.70	Mesocrany
81C	Christian	75.53	Mesocrany

— Unable to obtain cranial index; individual placed in order of matching cranial form.
[a] Artificially flattened on back of skull.
[b] Redeposited skeletal parts.
[c] Disturbed by later activities.

Cranial Morphology and Genetics

The assessment of cranial shapes was derived from 57 intact and partially intact adult skulls, 41 male and 16 female, but cranial indices could only be determined for 71% of male skulls and 81% of female skulls (Table 4). Female skulls reflect more homogeneity than do male skulls with the majority (62.5%) within the mesocrany (medium) range (Fig. 33). Nearly a third of male skulls fall within the mesocrany range, while the majority of male skulls are broad or round (brachycrany) or very broad (hyperbrachycrany) (Fig. 34). The remainder of the female skulls falls within the brachycrany range, with only one female skull exhibiting hyperbrachycrany. Male skulls also include six long (dolichocranic) skulls, while there are none among the female skulls.

This content downloaded from 78.100.65.226 on Fri, 11 Oct 2013 01:17:53 AM
All use subject to JSTOR Terms and Conditions

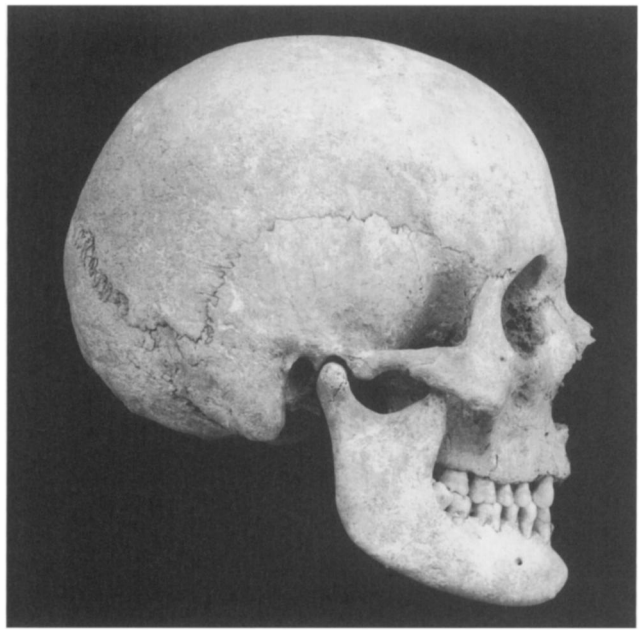

Figure 33. Medium female skull (mesocranic) from grave 40

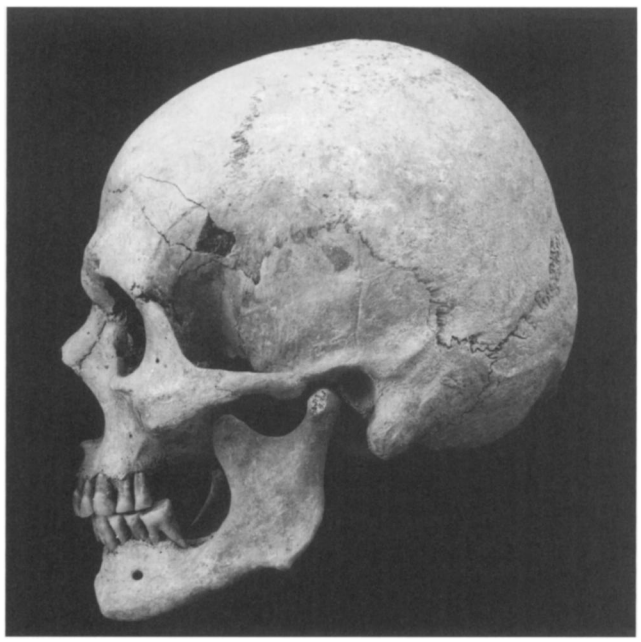

Figure 34. Very broad male skull (hyperbrachycranic) from grave 58

This assessment tells us that most of the women in this population were local, while many of the men came from outside the area and, marrying into the existing population, produced a mixed population.

One adult male from Christian-style grave **23** with a hyperbrachycranic skull displays artificial flattening of the back of his skull (Figs. 35, 36) and ossification of the styloid ligament (Fig. 37). Artificial cranial deformation does not appear in earlier populations at Ancient Corinth, so this individual must have come from outside the area. One other adult male (burial A in grave **81**) shows some flattening with increased height of the back of his mesocranic skull (Fig. 38).

This content downloaded from 78.100.65.226 on Fri, 11 Oct 2013 01:17:53 AM
All use subject to JSTOR Terms and Conditions

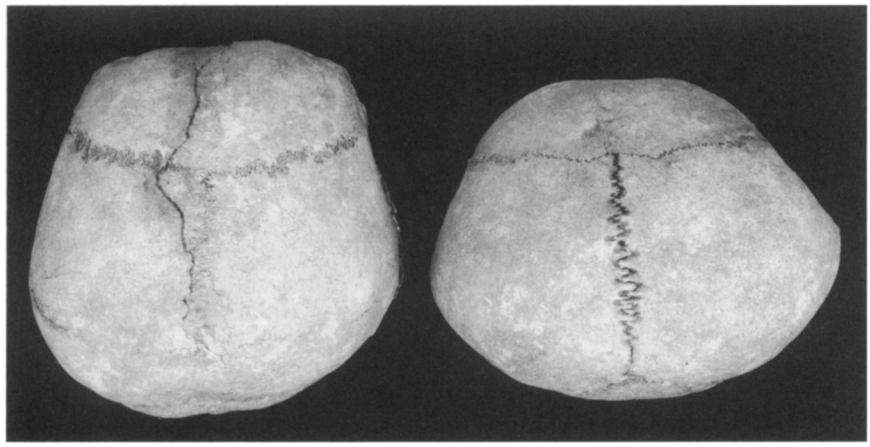

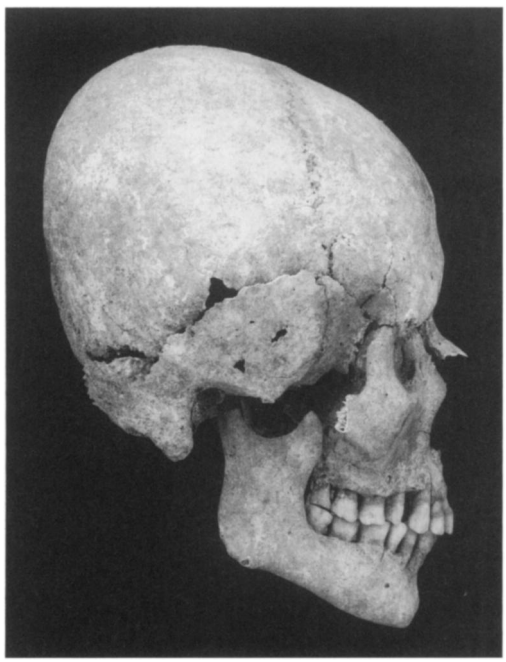

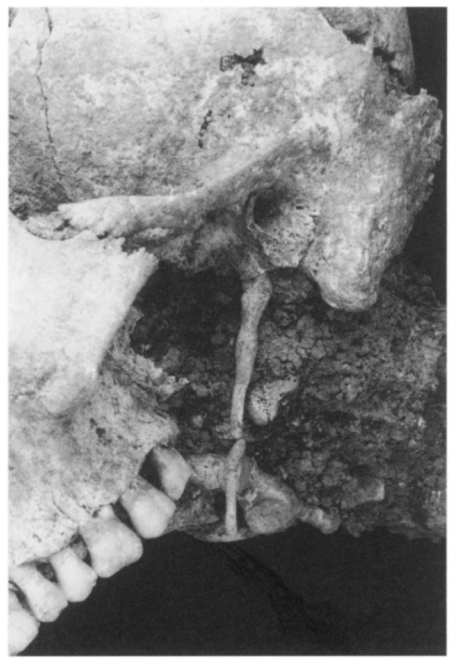

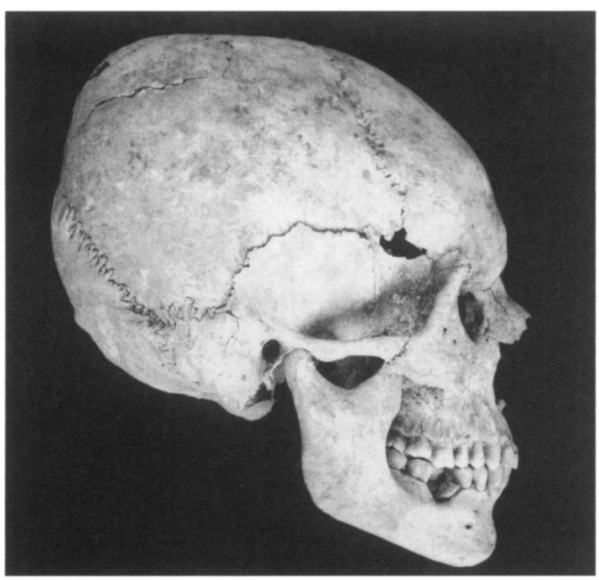

Figure 35 *(top)*. Comparison of undeformed adult male skull (burial A) from grave 25 with deformed adult male skull (right) from grave 23 displaying flattening at the back

Figure 36 *(center left)*. Male adult from grave 23 with a hyperbrachycranic skull displaying artificial flattening at the back

Figure 37 *(center right)*. Ossification of the styloid ligament in adult male from grave 23

Figure 38 *(left)*. Adult male (burial A) from grave 81 showing high back of mesocranic skull

This content downloaded from 78.100.65.226 on Fri, 11 Oct 2013 01:17:53 AM
All use subject to JSTOR Terms and Conditions



Figure 39. "Boat-shaped" skull (scaphocephalic) of preadolescent from grave 43. Cracks from ground pressure.

The skull of the 11–12-year-old preadolescent (burial G) from Christian grave **43** appears "boat-shaped" (scaphocephaly) as a result of the sagittal suture's failure to develop at the top of the skull (Fig. 39). Without this suture the skull cannot grow into its normal configuration. A similar child's skull was excavated in the 13th-century Frankish-period cemetery at Ancient Corinth.[29]

Skeletal Traits

Many of the burials within a given Christian-style grave shared similar skeletal and dental genetic traits as well as skull shapes, and some genetic traits and skull shapes clustered among groups of graves, reflecting family plots. The majority of individuals with hyperbrachycranic skulls clustered in the southeastern part of the cemetery, and most individuals with dolichocranic skulls clustered in the northern part of the cemetery. There is no clear separation of skull shapes and skeletal traits between Muslim and Christian burials.

Genetic shifting of the thoracic–lumbar border upward occurs in 15 individuals clustered in a north–south line in the center of the cemetery.[30] Downward shifting of this vertebral border was found in only five individuals, two of them, both males, buried near one another in graves **23** (Fig. 40) and **32**, while the rest were scattered throughout the cemetery and displayed many other genetic traits, mentioned in the catalogue of burials below. No shifting of the cervical–thoracic border was noted, but three individuals show minor shifting at the base of the skull and cervical border, two with downward-shifting expressions and one with upward expression. Two males and one female show downward shifting of the lumbar–sacral border with complete separation of the first sacral segment, and one female displays upward shifting of this border with the last lumbar as part of the sacrum. The border between the sacrum and coccyx shifts downward in six adults and upward in two individuals.

29. Barnes, in prep.

30. For the thoracic–lumbar border, see Barnes 1994, p. 148. The bones of the vertebral column develop from the pattern set in embryonic tissue, with demarcation of the borders between vertebrae of the head and neck, lower cervical vertebrae of the neck and thoracics of the upper back, last thoracic of the lower back and upper lumbars, lower lumbar and sacrum, and lower sacrum from coccyx. Genetics dictate how these borders form, and some genetics program some or all of the borders to shift upward or downward, leaving genetic markers on the completed vertebral column. See Barnes 1994, pp. 79–81.

This content downloaded from 78.100.65.226 on Fri, 11 Oct 2013 01:17:53 AM
All use subject to JSTOR Terms and Conditions

Figure 40. Lumbar ribs caused by downward shifting of the thoracic-lumbar border in the spine of adult male from grave 23. Scale 3:4

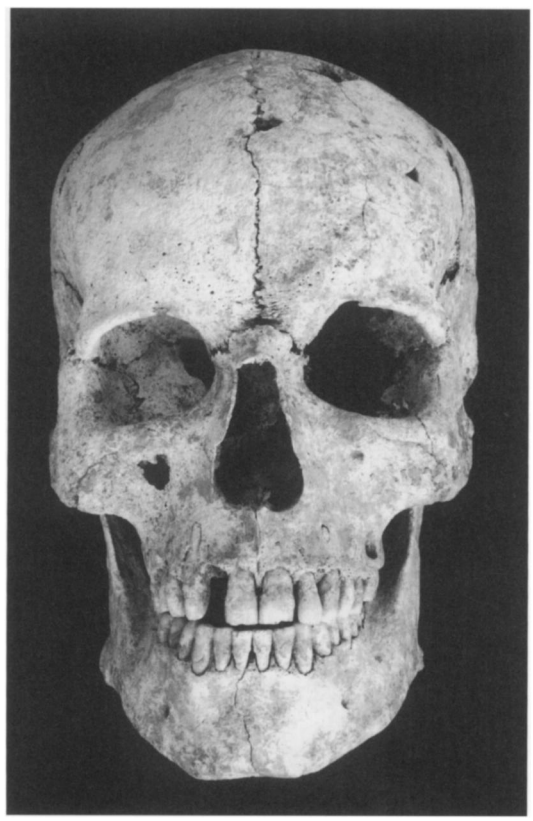

Figure 41. Metopism in adult male skull (burial B) from grave 70

Among the many traits identified, metopism, the retention of the infantile suture on the frontal bone of the forehead into adulthood (Fig. 41),[31] appeared in six individuals (four males, one female, and one child), representing 7.89% of frontal bones (n = 76). Three of these came from a cluster of graves (**34A**, **42C**, and **81B**) in the northwest portion of the cemetery. This trait is not uncommon among European populations, and it occurs frequently in all earlier populations from Ancient Corinth.

Another cranial trait, the mendosa suture, reflects the failure of the fetal occipital bone on the back of the skull to unite.[32] Usually only a small portion of the suture fails to fuse on one or both sides of the skull. This trait occurred in 11 adult skulls, males only, and the skulls of three children, with one adult male from grave **15** showing a complete mendosa suture, often referred to as the "Inca" bone.

31. Barnes 1994, p. 148.
32. Barnes 1994, p. 142.

This content downloaded from 78.100.65.226 on Fri, 11 Oct 2013 01:17:53 AM
All use subject to JSTOR Terms and Conditions

Figure 42. Retromastoid ossicle on right side of adult male skull from grave 17, burial A

Parietal thinning can be seen in an adult female skull from burial C of grave **42**. This rare trait reflects the lack of development of the intermediate diploe space between the inner and outer layers of bone over the back portions of the parietal bones of the skull.[33] Sometimes it appears on only one side of the skull, but in this instance it appears on both sides. This trait has been identified in a few individuals from earlier Corinthian populations.

Another unusual trait, coronoid hyperplasia of the mandible,[34] was found in only one individual, the adult male from grave **74**. This bony process enlarges and prevents the lower jaw from fully opening.

A retromastoid ossicle, an extra bone forming in the suture between the mastoid and occipital bones of the skull (Fig. 42), was observed in two males and two females, two of them buried near each other. Tiny ectodermal cysts above the foramen magnum on the back of the skull were identified in two males and one female; one of the males was buried near the female. Failure of the lower portion of the coronal suture to develop appears in five adults, and one male also lacks sutures between the sphenoid and frontal. Another male lacked a suture between the left temporal bone and occipital. For these examples, see the catalogue entries for graves **26**, **27**, **40**, **45**, and **74**.

Sometimes a bony bridge forms over the blood vessel passing alongside and through the foramen on the sides of the atlas vertebra of the neck, either just posterior to the foramen or crossing it laterally. Posterior bridging is far more common than lateral bridging, and it occurs in seven individuals in this cemetery, five males and two children. Only two individuals with this trait had been buried near each other (graves **23**, **32**). Three males and one female, whose graves lay scattered throughout the cemetery, display lateral bridging of the atlas.

The os acromion (Fig. 43) represents the failure of the epiphyseal end of the acromion jutting out from the scapula over the shoulder joint to fuse in adolescence, thus forming a separate bone. Four adult males (graves **23**, **27**, **57A**, **81A**) and two young adult females (graves **59A**, **62**) display this trait, with all but one male clustered in one area. Other notable traits found in this cemetery include the septal aperture, an opening in the bone above the distal articular end of the humerus, expressed in three females and one male (graves **10**, **46**, **59A**, **66A**); separation of the styloid end of the

33. Barnes 1994, pp. 146–148.
34. Barnes 1994, p. 169.

This content downloaded from 78.100.65.226 on Fri, 11 Oct 2013 01:17:53 AM
All use subject to JSTOR Terms and Conditions

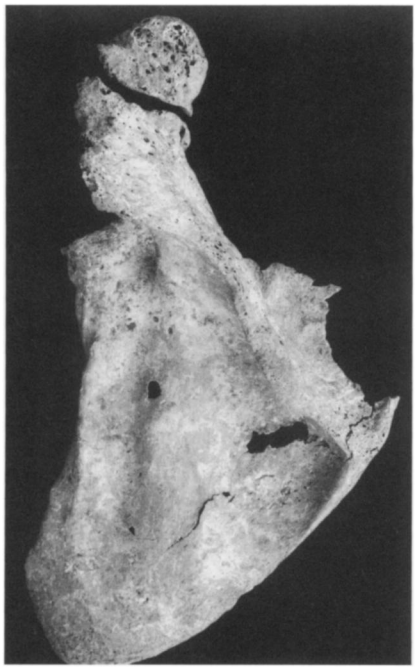

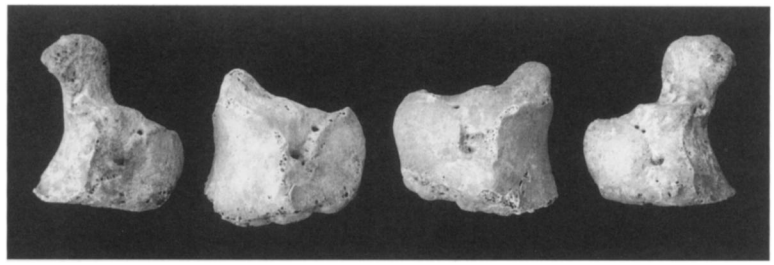

Figure 43 *(far left)*. **Os acromion on left scapula of adult male from grave 57**

Figure 44 *(top)*. **Hypoplasia of the hamulus in the wrists of adult male from grave 42 compared to normal hamate bones**

Figure 45 *(near left)*. **Left os navicular in adult female from grave 9 (lower) compared to a normal left navicular (upper).** Scale 3:4

ulna in two males (graves **16, 70A**); and a very small (hypoplasia) hamulus projecting from the hamate bones in the wrists of an adult male in grave **42** (Fig. 44) and the female in grave **53**, near one another. Separation of the styloid process on the 3rd metacarpal of the hand occurred in three males and one female (graves **14, 17A, 30A, 50**); the male in grave **76** displays an elongated trapezoid from the wrist; and three males and one female exhibit asymmetrical torsion of the femoral necks. Six adults display a small vastus fossa of the patella, two adults show os trigonum (separation of the back of the talus above the heel), and developmental separation of other foot bones in lone individuals include os calcaneus, os navicular (Fig. 45), os 1st cuneiform, and os metatarsal. One adult (grave **83**) shows nonosseous coalition of the 3rd metatarsal and cuneiform on both feet. The common trait symphalangism (fused 5th toes) is present in three females, three males, and one child. This trait often goes unaccounted for when the tiny 5th toe bones are not recovered during excavation.

The young man from grave **32** displays a very rare bifurcation of the neural arches on the 11th and 12th thoracic vertebrae (Fig. 46). This defect generally occurs in the atlas vertebra from the neck, in the last lumbar vertebra, or in the sacrum. Clefting occurs in two atlases (Figs. 47, 48), one 5th lumbar, and seven sacral segments usually involving only the 1st sacral segment.[35] All but two individuals with cleft sacra clustered in the northern quarter of the cemetery.

The child in grave **79** exhibits developmentally enlarged basivertebral foramina on thoracic and lumbar vertebrae (Fig. 49). These blood vessel openings into the bony vertebral bodies usually are not so prominent and generally go unnoticed.

Developmental defects related to Klippel-Feil syndrome[36] were observed in the neck and upper thoracic spine of a mature male, burial B in grave **2** (Fig. 50). The 2nd and 3rd cervical vertebrae had failed to

35. Barnes 1994, pp. 117–122. Bifurcation or clefting of neural arches occurs when the bony templates for the neural arches fail to meet during embryonic development, leaving only soft tissue to connect the two halves. This defect is not related to cleft neural arches associated with neural tube defects, and does not cause any pathology.

36. Barnes 1994, pp. 67–68.

This content downloaded from 78.100.65.226 on Fri, 11 Oct 2013 01:17:53 AM
All use subject to JSTOR Terms and Conditions

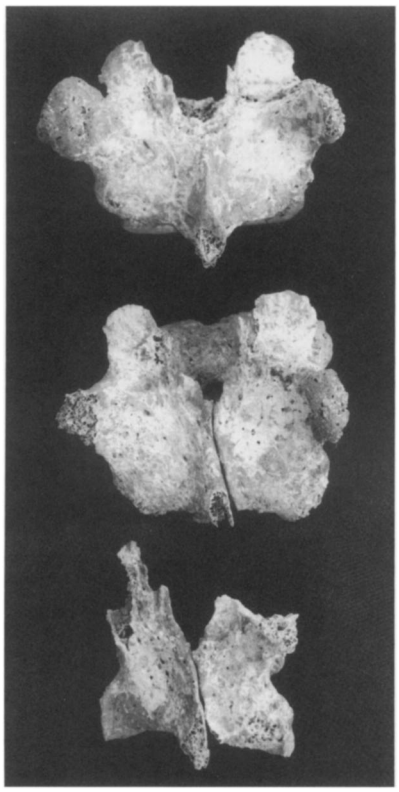

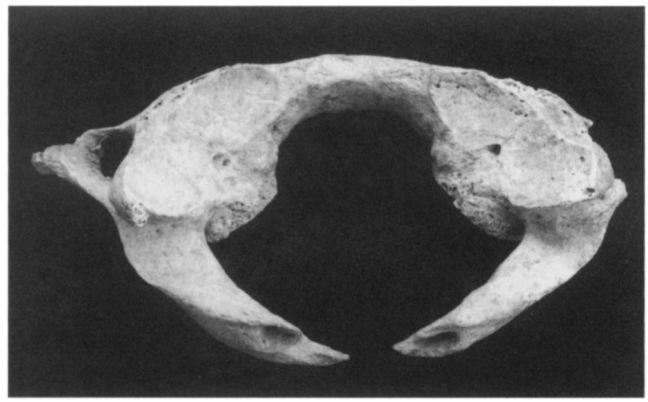

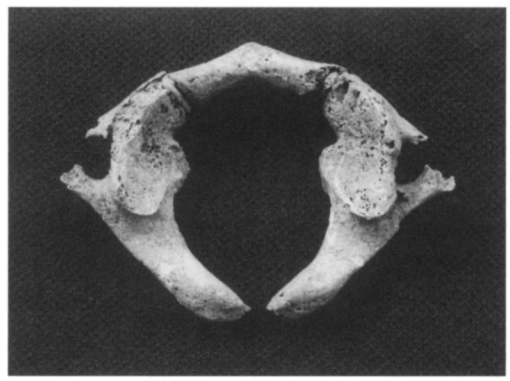



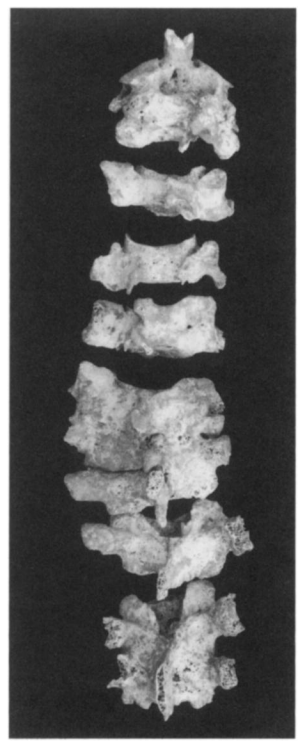

Figure 46 *(above left)*. Adult male from grave 32. Top: normal 10th thoracic vertebra; center and bottom: 11th and 12th thoracic vertebrae showing bifurcated neural arches.

Figure 47 *(above right)*. Cleft posterior arch in atlas of adult male from grave 54, burial B

Figure 48 *(center)*. Cleft posterior arch in atlas of child from grave 56

Figure 49 *(near right)*. Enlarged anterior basivertebral foramina in thoracic and lumbar vertebrae of child in grave 79. Scale 1:1

Figure 50 *(far right)*. Developmental defects related to Klippel-Feil syndrome from 2nd cervical through 5th thoracic vertebra in adult male from grave 2

This content downloaded from 78.100.65.226 on Fri, 11 Oct 2013 01:17:53 AM
All use subject to JSTOR Terms and Conditions

separate during embryonic development, while the last cervical and the 1st and 2nd thoracic vertebrae remained united as a single block with deformities, along with the 4th and 5th thoracic vertebrae, which also formed a block with deformities. The 4th, 5th, and 6th cervical vertebrae and the 3rd thoracic vertebrae are deformed as well. The 6th and 7th thoracic vertebrae appear to have been mildly affected (see the catalogue entry for more details).

Dental Traits

Agenesis, or the absence of development of one or more of the 3rd molar teeth, is a common trait, appearing in 40% (n = 20/50) of the adults and adolescents in the Panayia Field cemetery who could be assessed for dental status. This trait appears mostly within two clusters of graves, one located along the northern edge of the cemetery and one in the southeast area; sometimes it occurs in more than one burial within a single grave. Carabelli's cusp appears in four children, one adolescent, and three adult males, while small protostylid pits are as common as 3rd molar agenesis. Three adult males exhibit micro molars, very small teeth (Fig. 51), and the male from grave **27** shows an extra pointed tooth between his upper central incisors (Fig. 52), while the adolescent from grave **66** shows an extra tooth between the upper right 2nd premolar and molar, and failure to shed deciduous upper canines. Two adult females and one male display impacted molars, while the male from grave **25** has a canine tooth impacted into his palate.

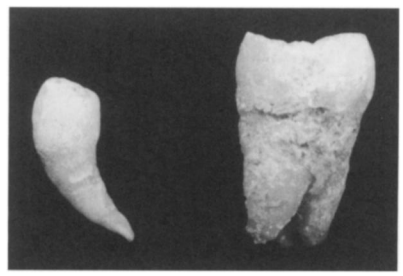

Figure 51. Upper left micro 3rd molar in adult male from grave 21 compared to normal right 3rd molar. Scale ca. 2:1

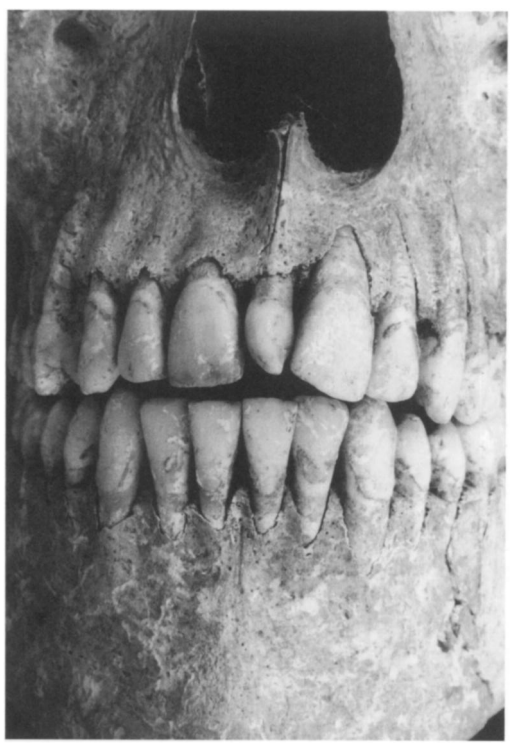

Figure 52. Extra tooth between upper central incisors in adult male from grave 27

This content downloaded from 78.100.65.226 on Fri, 11 Oct 2013 01:17:53 AM
All use subject to JSTOR Terms and Conditions

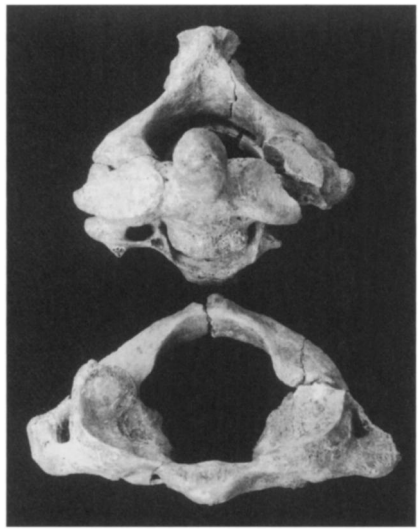

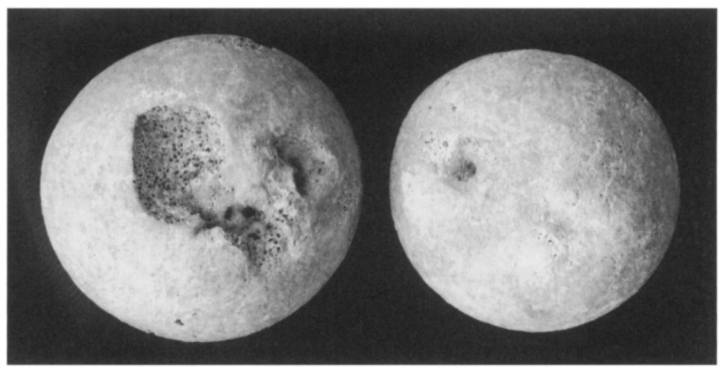

Figure 53 ***(top left)*****. Hanging fractures on atlas and axis vertebrae of adult male from grave 27, seen from above**

Figure 54 ***(top right)*****. Hanging fractures on atlas and axis vertebrae of adult male from grave 27, seen from below**

Figure 55 ***(right)*****. Aseptic necrosis of left femoral head of adult male from grave 27 (left) compared to unaffected right femoral head (right)**

Trauma

Signs of trauma ranging from minor to major injury show up in 39% of males, 22% of females, and one child. Death from violence can be seen in four adult males, including the young man from grave **20** who died hanging from a large metal hook (Figs. 24, 25). The young man from grave **27** also died by hanging, evident from the fractured vertebrae in his neck (Figs. 53, 54). He also had received blows to the left clavicle and left hip when he died. This individual had suffered pain and lameness in his left hip from aseptic necrosis of the femoral head (Fig. 55) caused by disruption of blood supplying the femoral head. The cause may have been earlier trauma to the hip.

Two mature men buried together in grave **70** had received blows to their legs at the time of death; one had smash injuries above both knees, and the other had smash injuries above the left ankle. One of these men also displayed an old healed fractured left ankle and a healed wrist injury, while the other man had suffered from trauma to the neck in the past causing a slipped disc, and had fractured ribs that had healed earlier. Signs of violent trauma can also be seen in a fragment of an extra adult right tibia from grave **30** that bears an unhealed cut mark.

This content downloaded from 78.100.65.226 on Fri, 11 Oct 2013 01:17:53 AM
All use subject to JSTOR Terms and Conditions

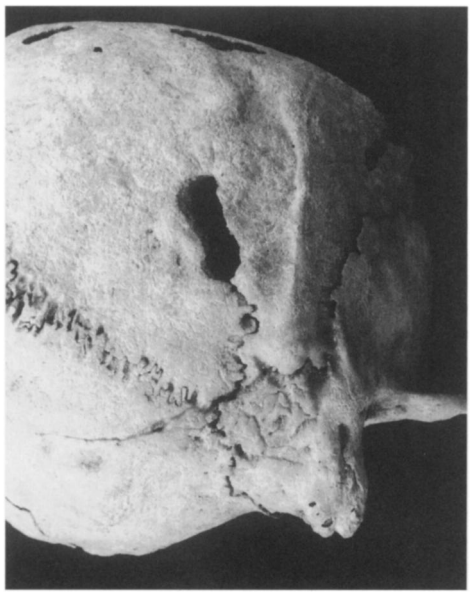

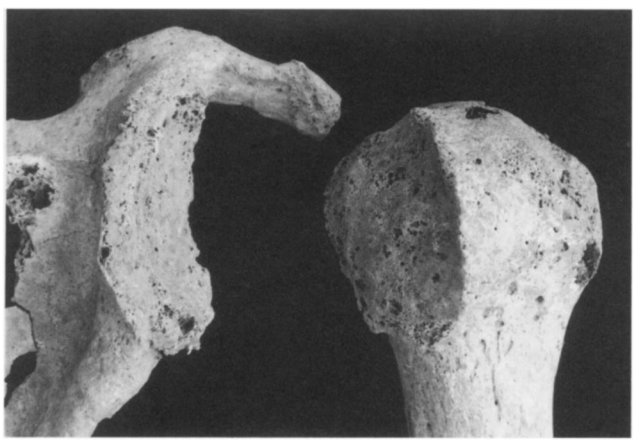

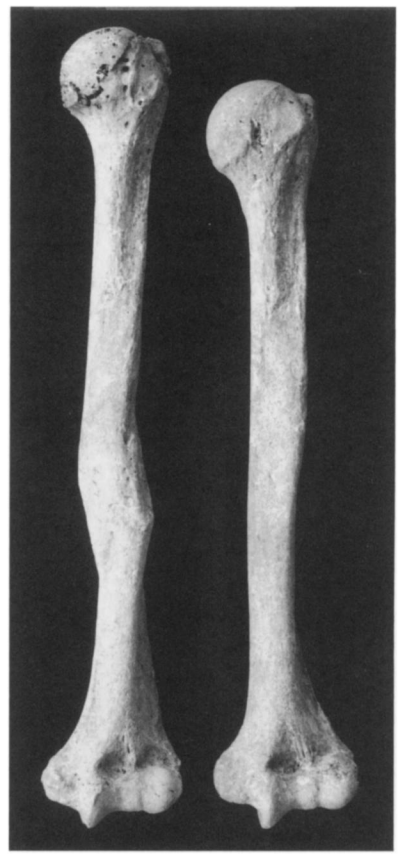

Figure 56 *(top left)*. Large healed cut wound on right side of adult female skull from grave 44

Figure 57 *(top right)*. Healed compound fracture of left humerus in adult female from grave 54 (left) compared to a normal left humerus (right)

Figure 58 *(center)*. Crushing injury of right shoulder in adult male from grave 34, burial A

Figure 59 *(left)*. Slipped epiphysis of the right femoral head (causing lameness) in adult male from grave 16 (left) compared to normal left femoral head of same individual (right)

This content downloaded from 78.100.65.226 on Fri, 11 Oct 2013 01:17:53 AM
All use subject to JSTOR Terms and Conditions

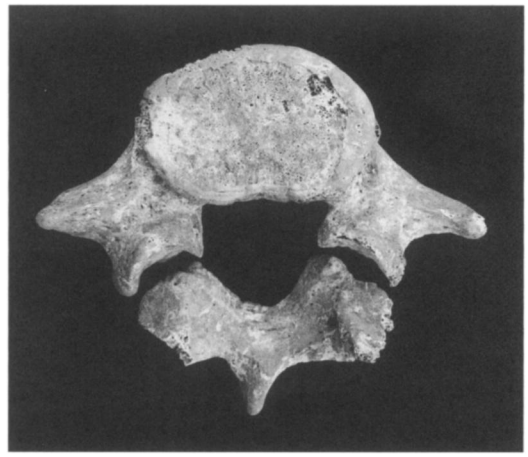

Figure 60. Spondylolysis of the 5th lumbar vertebra in adult male from grave 32

A large portion of the right side of the skull of the old woman buried in grave **44** is covered by a cutting wound that had become infected (Fig. 56); most of it had healed before her death. The middle-aged woman from grave **54** displays a healed compound fracture of the left humerus (Fig. 57) and also of the right tibia, and the young woman buried in grave **9** displays a healed defensive fracture to the ulna of the left forearm along with recent compression fractures to the 2nd and 3rd lumbar vertebrae in her lower back. The old woman from grave **26** had suffered an old injury to her right shoulder, and one of the males from grave **54** displays a similar injury.

Other healed injuries include blows to the head of a child (grave **7**), and to four men (two from grave **17**, one from grave **58**, and another from grave **83**). The man from grave **58** also shows rib injuries, while that from grave **83** has a broken upper tooth and fractured right clavicle. Two men display fractured lunates in their right wrists, one man has a smashed thumb tip, and another man has a smashed middle finger tip. One man had injured the talus of his right foot, and another had a smashed 5th toe. Rib injuries from blows to the back occurred in five men and one woman, and the man from burial A in grave **34** had suffered blows to the chest causing injury to the sternum, a crushing injury to the right shoulder (Fig. 58), and a fracture in his right hand.

The man buried in grave **16** suffered lameness in the right hip from a slipped epiphysis of the femoral head that had occurred during childhood (Fig. 59). Occasionally in cases such as this, the head slips downward before it fuses to the shaft, causing deformity at the hip joint.

A stress fracture of the neural arch, known as spondylolysis, from the body of the 5th lumbar vertebra (Fig. 60), caused by overuse trauma on the lower back, occurred in three young men (graves **27**, **32**, **67**) and one older child (grave **24**). This type of injury is not uncommon, and it often occurs when the affected vertebra's neural arch develops asymmetrically. Usually, as seen in the three young men, both sides of the neural arch break; less frequently, just one side breaks, as with the child from grave **24**. Sometimes the fracture is incomplete.

This content downloaded from 78.100.65.226 on Fri, 11 Oct 2013 01:17:53 AM
All use subject to JSTOR Terms and Conditions

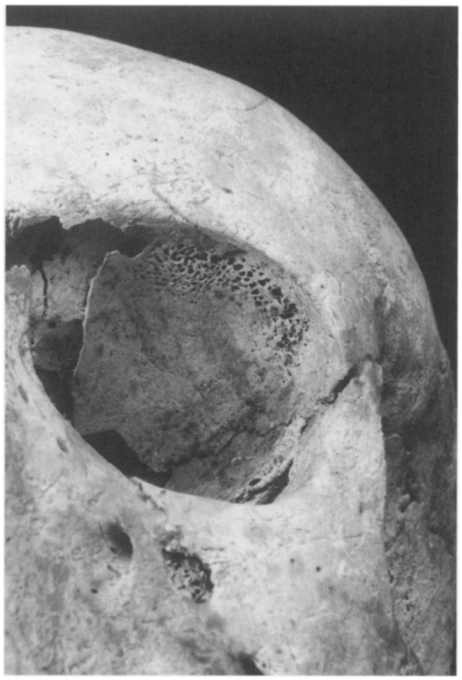

Figure 61. Evidence of childhood anemia in the form of *cribra orbitalia* in left eye orbit of preadolescent from grave 54

Diseases

Nearly half (43.54%) of the individuals with observable eye orbits (n = 62) show signs of childhood anemia in the form of pitting lesions of *cribra orbitalia* (Fig. 61). All six infants and two-thirds of children with eye orbits preserved show signs of anemia, while fewer than a third of adults with eye orbits bear anemia scars. Infection such as childhood malaria frequently causes anemia as the body tries to pull iron out of the system and away from the parasites needing it.[37] We know that malaria was a problem for centuries in and around Corinth, and we often see evidence for high frequencies of childhood anemia at this site.

We also have documented incidences of congenital anemia known as thalassemia, resulting from genetic responses to malaria, in earlier Corinthian populations. The young man from grave **29** shows signs of congenital anemia with greatly thickened parietals with pitting scars (Fig. 62), as well as other signs of anemia. The young woman from grave **30** displays signs suggestive of congenital anemia. Individuals suffering from intermediate forms of thalassemia generally survive into early adulthood before they succumb to the disorder, while infants with more severe forms of the disorder seldom survive into childhood. The toddler from grave **3** displays signs of deadly congenital anemia (Figs. 63, 64), while the toddler from grave **52** shows signs of severe anemia (Fig. 65) that may be from severe infection with malaria.

Other severe pathology includes evidence of metastatic cancer reflected in a punched-out lesion on the left side of the forehead of the young woman buried in grave **8** (Fig. 66). Another severe pathology was expressed as a large brain tumor imprint on the left side of the back of the skull of the middle-aged man from grave **70** who had suffered from both old injuries and from new injuries at the time of his death.

37. Weinberg 1992.

This content downloaded from 78.100.65.226 on Fri, 11 Oct 2013 01:17:53 AM
All use subject to JSTOR Terms and Conditions

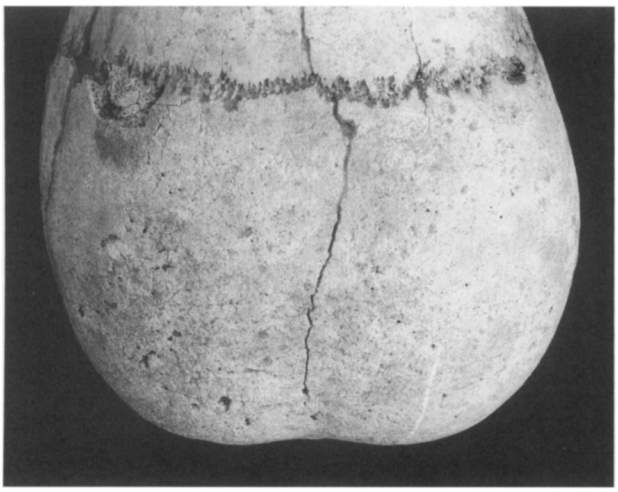

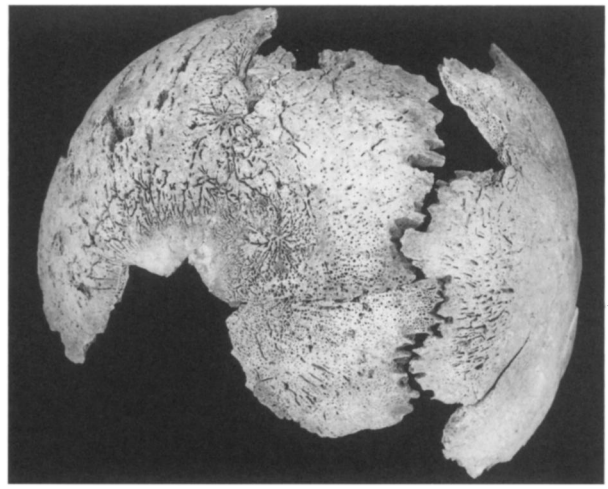

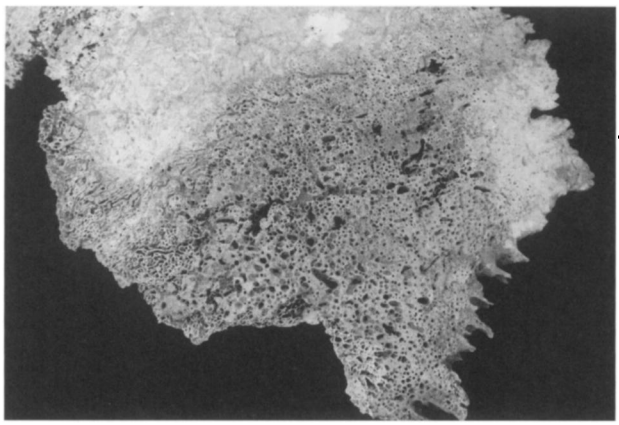

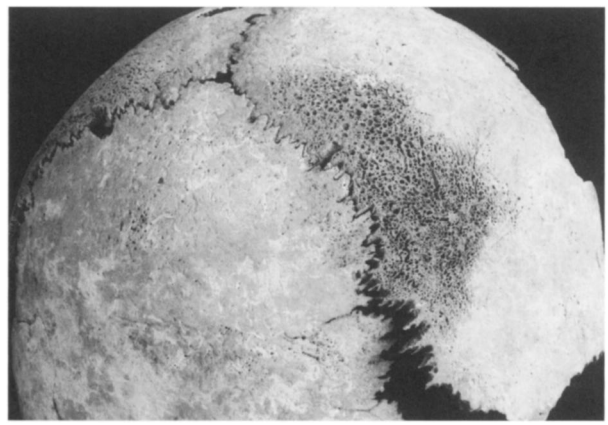

Figure 62 *(top left)*. Evidence of intermediate thalassemia in the form of thickened parietals with pitting scars in adult male from grave 29

Figure 63 *(top right)*. Evidence of fatal congenital anemia in the form of severe porotic hyperostosis on left side of skull of infant from grave 3

Figure 64 *(center left)*. Detail showing lesions on right parietal of skull of infant from grave 3

Figure 65 *(center right)*. Evidence of severe anemia in the form of porotic hyperostosis on skull of infant from grave 52

Figure 66 *(right)*. Punched-out lesion from metastatic cancer on frontal bone of adult female skull from grave 8

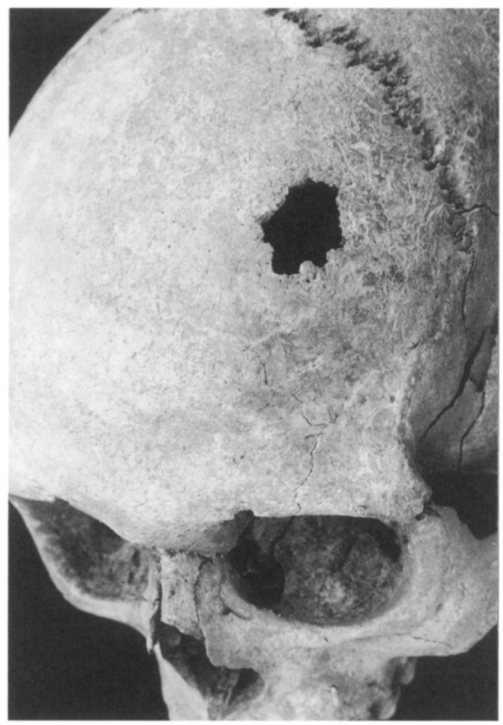

This content downloaded from 78.100.65.226 on Fri, 11 Oct 2013 01:17:53 AM
All use subject to JSTOR Terms and Conditions

Apparent conjoined gallstones (Fig. 67) were retrieved from the lower right thoracic region of the middle-aged man from grave **50**. Signs of infection with brucellosis were reflected in vertebral lesions (Fig. 68) of three men. This disease has been common throughout the Mediterranean world for centuries, carried primarily by goats and transferred to humans through infected milk products or by handling birthing fluids and placentas of infected animals. Signs of lung infection (Figs. 69, 70) are indicated by internal rib lesions found in three men. Goutlike lesions appeared in the wrists of a man in grave **17** (burial A) and a woman in grave **85**; similar gout-like lesions could be seen in foot bones of two men (graves **34A**, **50**).

Figure 67. Conjoined gallstones from thoracic region of adult male from grave 50. Scale 2:1

Signs of infection include a severe mastoid infection of the younger adolescent male from grave **45**, inner skull lesions reflecting meningitis in one man, one child and three infants, and osteitis of leg bones in three men and one child. Severe occlusal dental calculus in the adult male from grave **4** reflects prolonged illness from an unknown cause. There are signs of osteoporosis in the older woman (burial A) from grave **75** and in the middle-aged man in grave **48**.

Dental disease was observed in the teeth of 68 individuals for which there was enough dentition to determine dental status: 32 adult males and 19 adult females of all ages, 6 adolescents, and 11 children. Signs of dental disease, including periodontal disease, caries, abscesses, and tooth loss, show progressive increases with age. Only one preadolescent, 11–12 years old (grave **42**), shows signs of dental disease resulting in the loss of permanent upper central incisors. One male adolescent (grave **74**) has a large abscess, and another male adolescent (grave **66**) shows signs of periodontal disease.

Dental problems often begin with signs of periodontal disease reflected in bone resorption around the teeth by the mid- to late 20s, and caries

Figure 68. Evidence of brucellosis infection in 11th thoracic vertebra of adult male from grave 54

This content downloaded from 78.100.65.226 on Fri, 11 Oct 2013 01:17:53 AM
All use subject to JSTOR Terms and Conditions

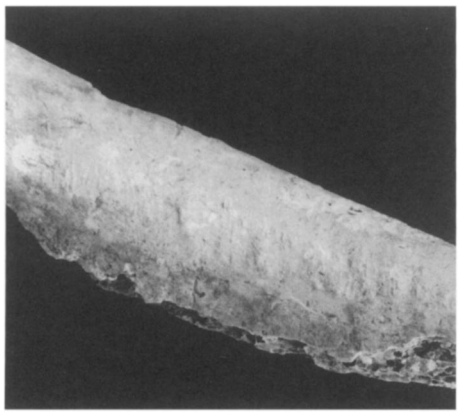

Figure 69 ***(left)*****. Rib of adult male from grave 25, showing raised internal lesions**

Figure 70 ***(right)*****. Ribs of adult male from grave 54, showing internal plaque lesions**

begin to appear in the early 20s. Tooth loss from severe periodontal disease and caries begins to appear in the mid-30s, increasing in severity with age. The majority of adults in the Panayia Field cemetery exhibit some dental disease, ranging from mild to severe, with 81% of men and 79% of women affected. Older adults bear most of the severe dental disease. Most of these older adults are women, while the majority of middle-aged and younger adults with dental disease are men.

Functional Stress

Signs of functional stress appear when muscles and joints have been repetitively overused. Such signs generally show up in irritated joint surfaces and at attachment sites for ligaments and tendons. Degenerative joint disease often reflects overuse as well as injury to a joint. Signs of functional stress increase with age, usually reflecting a lifetime of habitual activities related to daily life and work.

Assessment for signs of functional stress on 48 adult males and 17 adult females of all age groups, four adolescents (three male and one female), and three children show that the majority of this population had been hard-working people. Most, however, do not show evidence of intense hard labor.

Only two men between 25 and 35 years of age, representing 4% of the 48 adult males, and two young women, representing 12% of the 17 adult females, lack signs of functional stress. Most individuals from childhood to old age had been engaged in activities involving lifting and/or pulling. Men show more evidence of stressful activities than do women. The youngest child to exhibit functional stress from lifting was a 6–7-year-old (grave **28A**), showing that children had been pressed into daily work activities at a young age.

Wear facets on the 1st metatarsal of the feet, seen only in four adult males, reflect habitual kneeling positions. Wear facets between the tibia and talus of the ankle resulting from a habitual squatting posture appear in three women and three men. Poirier's wear facet shows on the neck of the femur and is caused by habitually sitting on the ground with hips extended and knees flexed. Only two men (graves **54, 57A**) have these wear facets.

This content downloaded from 78.100.65.226 on Fri, 11 Oct 2013 01:17:53 AM
All use subject to JSTOR Terms and Conditions

FUNERARY BEHAVIOR

Preparation of the Body

We possess very little direct evidence from the excavations for how the mourners might have prepared the body of a recently deceased person for burial. Twentieth-century practice suggests the body was washed with both oil and wine,[38] then dressed, and finally laid out in the position in which it would be buried. All of this would have had to take place within the first four hours after death, before rigor mortis set in and while the arms and legs could still be moved into the desired position.[39] Very few of the bodies in the Panayia Field cemetery had feet and ankles lying close enough together to suggest that the feet may once have been tied for burial, a common modern practice. Where hands were found together over the stomach or lower abdomen, they may very well have been tied together in the modern manner. This same modern practice entails both hands and feet being untied during interment of the body. It has also been a common funerary practice in modern Corinth to tie the mouth shut using a cloth band until the body stiffened during rigor mortis. Once rigor takes over, the body's position, or attitude, cannot be altered for at least three days.

Some evidence indicating that the dead in the Panayia Field cemetery had been dressed for burial is suggested by the rare occurrence of clothing attachments in the graves. Pins, hooks and eyelets, a belt buckle, ornamental trouser rings, and the more frequent boot-heel cleats, all of which have been described above, involve clothing. Several persons obviously wore their boots to the grave. In one case, grave **33**, one of the three Nuremberg jetons that probably hung from the necklace accompanying the body retained a very small fragment of textile adhering to one surface. Most likely, this fragment represents a garment worn by the deceased at the time of interment. A minority of individuals had also been adorned in elements of their jewelry such as the rings, beads, necklaces, and pendants described above.

One final decision to be made during preparation of the body involved whether the corpse would be placed inside a coffin or simply wrapped in a cloth shroud. We have already noted how infrequently coffins (one certain case and two probable ones) had been employed in this cemetery; most individuals are likely to have been placed in shrouds. One other coffin appears to have been employed for grave **82** in the far eastern section of the Panayia Field excavations (Fig. 2). To allow mourners to observe the deceased's face during the funeral, the coffin lid could be removed or the shroud pulled back.

Preparation and Reuse of Graves

All the graves in this cemetery represent simple oblong or ovoid pits dug into the available earth (Fig. 71), usually to depths of around half a meter for adults and somewhat less for infants and small children (see above, p. 511). None had been lined with either stones or tiles. Such simple grave pits would only need to have been dug an hour or so before actual

38. Kurtz and Boardman 1971, pp. 103, 144, 149; Danforth 1982, p. 39, pl. 3.

39. Ludwig (1972, p. 17) and Spitz and Fisher (1993, pp. 26–28) indicate that rigor mortis would appear within the first three to four hours following death and would begin to relax after two to four days depending on temperature conditions.

This content downloaded from 78.100.65.226 on Fri, 11 Oct 2013 01:17:53 AM
All use subject to JSTOR Terms and Conditions

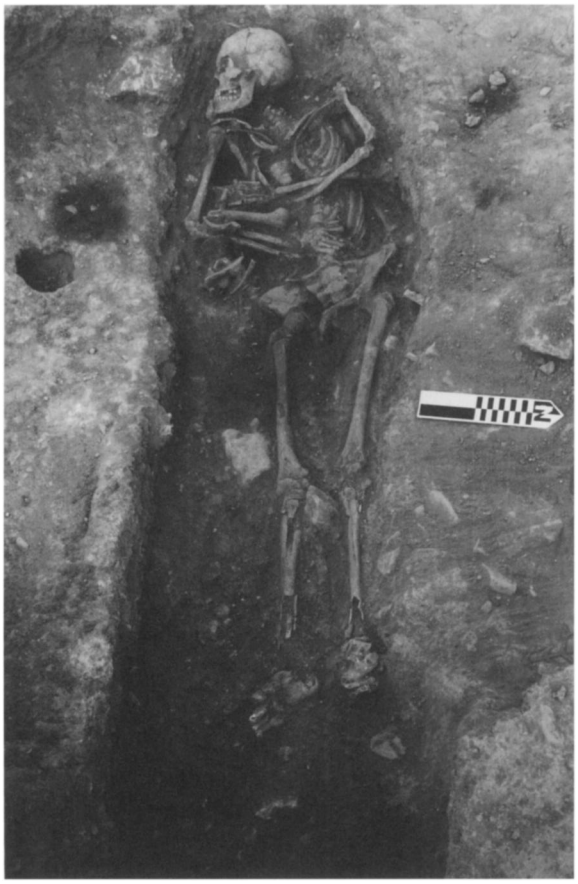

Figure 71 *(left)*. **Burial A in Grave 66, a simple pit grave in Christian style (except for head position)**

Figure 72 *(right)*. **Redeposited bones of adult male on top of primary adult male burial in Christian-style grave 17**

interment. Whether the mourners accomplished this task themselves or arranged for professional gravediggers, as people do today, we cannot know. When stones would be required to frame the deceased's head, these would most likely be assembled near the grave edge or even placed into approximate position prior to interment.

When the gravediggers selected an older grave to open for the interment of a recently deceased person, presumably following the mourning family's wishes, they could operate in several different ways. In the first fashion, they could exhume the skeletal parts of a previous burial or burials to be redeposited on top of the corpse of the latest burial. Graves **17** (Fig. 72), **24**, **36**, and **75** provide excellent examples of graves reused once after the original interment. While most such graves held two individuals, some contained more; grave **34**, for example, contained three adult males (Fig. 73). In all these cases, the persons within each grave had strong genetic links to one another, indicating a familial relationship.

In the case of grave **26**, where the bones of a 30–35-year-old man had been redeposited on top of an articulated skeleton of a woman over 60 (see Fig. 14, above), one wonders if they had been married and the husband died first, joined later by his wife after she had outlived him for many years. Genetically, they differed markedly from each other, as one would expect of a married couple. Grave **30** might provide a second such case since it too contained the skeletal remains of both a man and a woman, the 27–30-year-old

This content downloaded from 78.100.65.226 on Fri, 11 Oct 2013 01:17:53 AM
All use subject to JSTOR Terms and Conditions

Figure 73 ***(left)*****. Redeposited bones of two adult males on top of another adult male primary burial in Christian-style grave 34**

Figure 74 ***(right)*****. Redeposited bones of adult male on top of adult female primary burial in Christian-style grave 30**

male having been buried first, followed by the 30–40-year-old woman, with his exhumed remains reburied on top of her corpse (Fig. 74). These two people also bore no genetic relationship to one another. Grave **59** may represent a third instance, while several graves (**3**, **35**, **54**, **80**, and **81**) contained one male, one female, and one or more children.

In a second approach, the gravediggers could also simply open an old grave's fill down to or slightly above the skeleton of a previous occupant, disturbing it only slightly or not at all. The newest burial would then be placed on top of the older one. In some instances both practices had been employed. For example, grave **79** had intruded into the fill of grave **80** (Fig. 75), where it had caused the exhumation of bone piles from grave **80**, burials B and C, that were then redeposited on top of this latest burial. One unusual example may be seen in grave **76** where the older infant grave **77** had been "reconstructed" on top of the later burial of the 25–35-year-old adult male below (Figs. 76, 77). The genetic relationships among the people in each of these graves are somewhat unclear.

Third, some graves, either accidentally or intentionally, intersected older ones, leading to the redeposition of bones from the older burials on top of the later ones. Two grave sets illustrate this practice well. Grave **42** clearly had intersected the western two-thirds of grave **43** (Fig. 78). For this reason the eastern grave had to have been dug first for the interment of grave **43**, burial G. This child was next exhumed for the burial of

This content downloaded from 78.100.65.226 on Fri, 11 Oct 2013 01:17:53 AM
All use subject to JSTOR Terms and Conditions





Figure 75 ***(top left)*****. Primary burial 79 "intruding" into (resting on top of) primary burial in Christian-style grave 80**

Figure 76 ***(top right)*****. Redeposited burial 77 above primary Christian-style burial 76**

Figure 77 ***(right)*****. Primary Christian-style burial 76 beneath redeposited burial 77**

This content downloaded from 78.100.65.226 on Fri, 11 Oct 2013 01:17:53 AM
All use subject to JSTOR Terms and Conditions

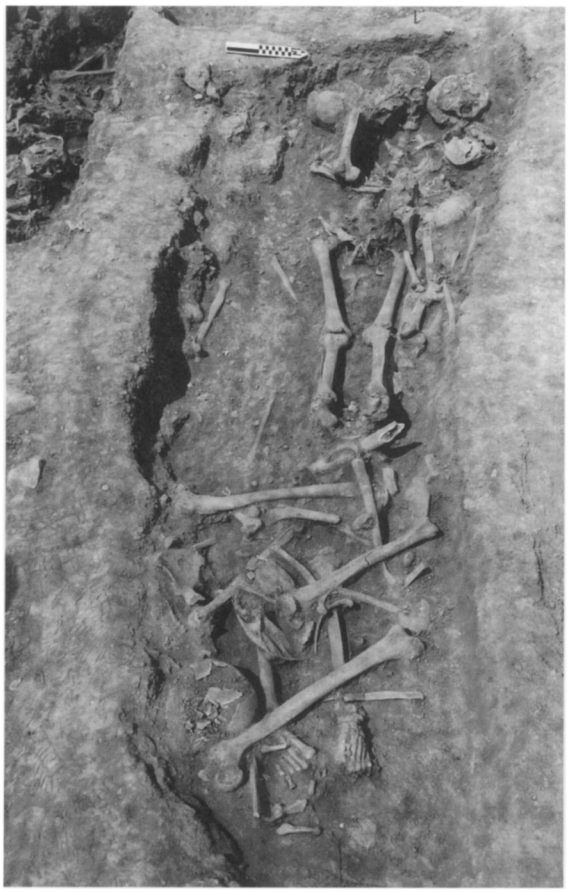

Figure 78 ***(left)*****. Primary burial 42 dug into Christian-style grave 43**

Figure 79 ***(right)*****. Primary burial in Christian-style grave 42**

adult F and its bones piled on top of the new corpse's legs. When digging of the western grave at some later time cut into the eastern one and removed the head and torso of burial F in grave **43**, elements from all of the older burials were redeposited on top of the newly interred person each time a new individual came to occupy the western grave. Burial A in grave **42** thus became the focus of the final funeral event for this grave set (Fig. 79). While we cannot rule out the possibility that this intersection of one grave by another occurred accidentally, we strongly suspect that the diggers of the later western grave intended to cut into the earlier grave, perhaps because it had contained relatives. Combined, intersecting graves **42** and **43** held the remains of seven individuals. Of these, at least two of the males showed strong genetic linkages, but the only female differed markedly from them, as if she had been a spouse.

The burial of three individuals in graves **38**, **48**, and **49** illustrates the intentional lengthening of one grave into a grave trench during two subsequent burial episodes (Fig. 80). A woman over 50 had first been interred in grave **38** with her head between a pair of framing stones. Next, her bones had been exhumed and redeposited in a pile with her skull still between the two framing stones. At this time, her original grave was extended eastward to accommodate the 39–44-year-old body of the male in grave **48**. Finally, the grave had to be lengthened still further toward the east

This content downloaded from 78.100.65.226 on Fri, 11 Oct 2013 01:17:53 AM
All use subject to JSTOR Terms and Conditions

Figure 80. Intentional lengthening of Christian-style graves 38, 48, and 49

for the placement of another burial, a man over 50 years old, in grave **49**. Neither of the males had their heads flanked by stones. Other grave trenches in early stages may be indicated by graves **28** and **31** and by graves **46** and **52**. Intriguingly, none of the occupants in each of these apparent grave trenches show any genetic relationships to one another.

Such successive actions had to have been intentional, because each set of gravediggers obviously knew where the older graves were located. Thus, the heads of the three individuals in graves **38**, **48**, and **49** were all arranged in an east-facing position. Such a grave trench calls to mind the series of trenches that initiated the burial usage in the Frankish occupation of Corinth in the late 13th century.[40] Similar long grave trenches may still be seen in cemeteries in northeastern France.

One last form of grave reuse seems to occur only in two Muslim-style graves, graves **2** and **70**. In both cases, the later burial disturbed an earlier one whose bones were merely pushed to one side, to the left, or north, to make room for the new burial. In grave **2**, the burial of a 30–35-year-old male had disturbed the bones of an adult woman (a married pair since their genetics differed markedly?), while in grave **70**, burial B, a 39–44-year-old male, had displaced the remains of burial A, a male 30–35 years of age (see Fig. 12, above). These two males also differed markedly from one another in genetic markers.

40. Barnes 2003, pp. 436–437; Barnes, in prep.

This content downloaded from 78.100.65.226 on Fri, 11 Oct 2013 01:17:53 AM
All use subject to JSTOR Terms and Conditions

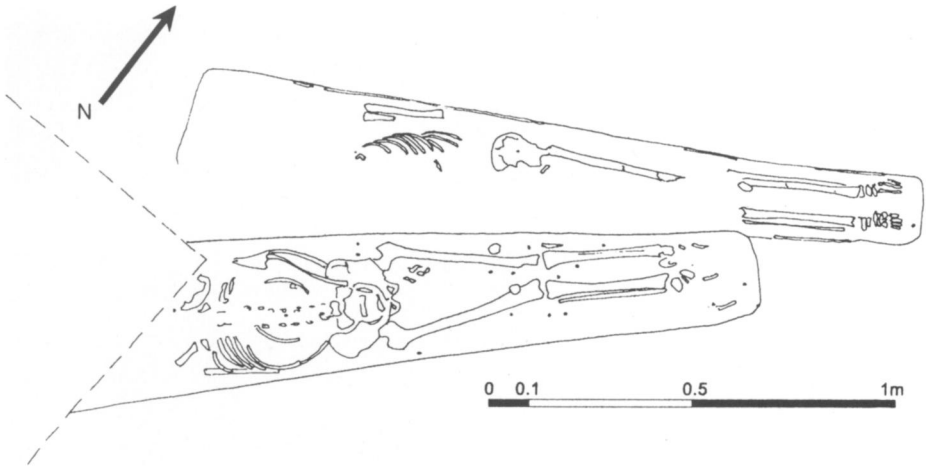

Figure 81. Muslim-style grave 14 (bottom) cutting into Christian-style grave 11 (top). Field drawing D. Al Maini

Of course, some gravediggers must have accidentally encountered parts of older graves as they readied a new one. Such accidental intersection of one grave by another does not constitute the reuse of a grave. The clearest case for such an accident can be seen where grave **14** cuts into grave **11**, disturbing both the right leg of the deceased and the wooden coffin remains in the older grave (Fig. 81).

Interment and Grave Filling

Both modern observations and ancient texts argue that some sort of ritual took place at the graveside as part of the funeral. Unfortunately, we have not found direct evidence for such ritual at the Panayia Field cemetery, although we can be reasonably certain some such activity occurred there with each interment.

We can say that several of the interred bodies were arranged with their heads between stones that framed them but that were not intended to prevent the heads from lolling to one side or the other once rigor relaxed (see above). In about half of those cases, a third stone had been placed across the tops of the two framing stones, covering the headspace between them and forming a niche for the head. This third stone could not have been put in place until the corpse had been interred. Some grave accompaniments that did not form part of the clothing or jewelry, especially coins, the iron knife blade in grave **41**, and the miniature terracotta head in grave **70**, seem to have been added at this time.

When earlier grave occupants had been exhumed to make space for the newly deceased, their disarticulated bones were next redeposited on top of the newest grave occupant, most commonly over the lower legs and feet (see Fig. 73, above). In some instances, most notably in grave **42**, burial A, skulls belonging to previous grave occupants might be set beside the newest person's head to frame it or even help to prop it upright (see Fig. 79, above). This redeposition of bones often would include material items from the older burials such as coins or iron boot-heel cleats.

Once the body of the deceased had been placed in position in the grave, the earth taken out during the grave digging could be put back in. First, however, any exhumed skeletal parts from previous grave occupants had to be redeposited on top of the newest corpse, usually above the feet and lower legs, and sometimes partially distributed along the left side,

This content downloaded from 78.100.65.226 on Fri, 11 Oct 2013 01:17:53 AM
All use subject to JSTOR Terms and Conditions

although occasionally some skulls would be placed at the head end. As the grave began filling up, some mourners seem to have thrown coins, usually of little value or even obsolete, into the fill. Inevitably, some scattered small bones and bone fragments from the general cemetery deposits would often end up in the grave fill. The grave was probably mounded up to allow for subsequent settling of the loose fill.

Post-Funeral Commemoration

The destructive activities of farming, beginning early in the 19th century and continuing until the purchase of the Panayia Field for excavation at the end of the 20th century, have erased all traces of any grave markers and possible commemorative features such as lamp boxes. Very few pieces of glass have been recovered from the cemetery area, and perhaps only one or two of those could represent votive lamps.

We suspect that this destruction may have occurred before the 19th century as well, perhaps during the times when inhabitants of Corinth's lower town feared the unsettling conflicts among Venetians, Turks, and other contestants for the citadel of Acrocorinth and its control of commerce by land and sea through the Isthmus. Even during pirate raids, the inhabitants would withdraw to the fortress above, abandoning the lower town. Any lengthy stay on Acrocorinth could help erase memories of, and practice in, the Panayia Field cemetery of the early 17th century.

CONCLUSIONS

Excavation of the Panayia Field cemetery has provided several surprises. We had originally expected to remove some scattered graves of 18th-, 19th-, or even 20th-century age associated with the now relocated Panayia Church in order to clear ground for excavations into Roman and earlier levels. Instead we encountered the dense concentration of graves discussed in this article, dating to the end of the earlier Ottoman period at Ancient Corinth, and most likely belonging to the early 17th century. We have identified this cluster as the "Panayia Field" cemetery to differentiate it from the later "Panayia Church" cemetery. It is likely that the location of the 17th-century Panayia Field cemetery had been forgotten by the time that the large Panayia Church cemetery was established. As noted, all evidence of the earlier cemetery must have been obliterated by later farming and residential activities, leaving no grave markers, and damaging many of these graves.

It is unusual to see so many more men than women in this large a mortuary sample, and the number of infant burials is also relatively small. Assuming the excavated sample is representative of the population, the proportions suggest that more men lived in the area than women. Functional stress patterns present a picture one would expect to see in a working-class population or one dominated by military activities. High frequencies of childhood anemia suggest that seasonal malaria haunted these people. Violent punishment for misdeeds is reflected in the evidence for a young man's death by hanging (grave **27**) and by another young man who had been left to die hanging from a hook (grave **20**). The pattern of traumatic injuries resulted from blows inflicted by others and from occupation-related

This content downloaded from 78.100.65.226 on Fri, 11 Oct 2013 01:17:53 AM
All use subject to JSTOR Terms and Conditions

injuries. Only a small percentage of the population lived to old age, with most dying during their prime years.

All of these characteristics suggest that this cemetery possibly served the members of a garrison population and their families. The paucity of infants and very young children and the common occurrence in the graves of iron boot-heel reinforcement cleats offer additional support for such an interpretation. This view could also help explain the mixing of Christian- and Muslim-style burial patterns, since both Christians and Muslims would have been working for their Ottoman rulers during this time of instability at Corinth and in the Peloponnese.

The very density of the graves makes it difficult to define possible family groupings. Many of the reused graves, such as **34**, **41**, **45**, **54**, and **80**, yielded strong evidence for family ties among the individuals whose remains have been found in them. Sequential burials in the grave trenches, however, held persons showing no familial relationships. The man and woman buried in grave **30**, with the remains of a genetically unrelated male redeposited on top of the female burial, possibly represent one of several marital pairs. Since the man's earlier burial there had intruded into grave **63**, containing a 5–6-year-old child, one can suspect the child could have belonged to the couple.

The juxtaposition, or even mingling, of Christian- and Muslim-style graves is also unusual. Previously investigated cemeteries at Ancient Corinth have contained one style or the other, but not both. Does this indicate that no functioning Christian church stood nearby at the time of the interments? Or does this reflect the relative looseness of the early Ottoman administration? Evliya Çelebi's description of the settlement on top of Acrocorinth during the 17th century mentions a Christian town between the outer gates and a Muslim town inside, but some Christian women who had married Muslim men had access to both towns.[41] Would Muslims and Christians who had intermarried have been buried in the same cemetery in the Panayia Field during the early 17th century?

While religion appears to have played a major role in the earlier 16th-century cemetery next to the old Frankish town, where most if not all the graves follow Muslim-style burial,[42] religion does not separate burials in this later Panayia Field cemetery containing both Christian and Muslim burials. Genetic traits are frequently shared across burial types, and many uncommon genetic markers are widely scattered throughout the cemetery. These data suggest the presence of a mixed population that had changed from the earlier, 16th-century, Ottoman occupation.

Mixed populations were common throughout the history of Ancient Corinth, with shifts in overall composition and the retention of some local genes sharing the general gene pool with newcomers. The earlier 16th-century Ottoman cemetery from the Frankish area contained a different genetic mix of cranial shapes and overall genetic traits from this later 17th-century Panayia Field cemetery, filled under Ottoman rule. The stature range for 16th-century males covers the whole spectrum, with some much taller than the 17th-century males, and none as short as the shortest males in the 17th-century cemetery. None of the earlier females were shorter than 157 cm (5′2″).

The few historical documents that refer to this time frame at Ancient Corinth paint only a very sketchy picture of the lower town (see Fig. 6).

41. MacKay 1968, p. 393; MacKay n.d., Evliya Çelebi, book 8, line 258a: "Inside this third gate, in the settled quarter within the castle, there are altogether two hundred multi-storeyed Muslim houses built of masonry and roofed all over with tiles. There are no infidel houses, and if it were not that some Muslims have infidel wives, no infidels at all could enter here." We are grateful to Pierre MacKay for allowing us to reproduce his translation here.

42. Blackman 1999, p. 32.

This content downloaded from 78.100.65.226 on Fri, 11 Oct 2013 01:17:53 AM
All use subject to JSTOR Terms and Conditions

TABLE 5. GRIMANI'S POPULATION CENSUS OF CORINTH IN 1700 BY AGE GROUP AND SEX

	Age Group					
Village	*1–16*	*16–30*	*30–40*	*40–50*	*>50*	*Total*
MALES						
Kalyvia	12 (43%)	5 (18%)	2 (7%)	5 (18%)	4 (14%)	28
Borgo	36 (19%)	54 (29%)	35 (19%)	29 (16%)	31 (17%)	185
Acrocorinth	48 (34%)	34 (24%)	35 (24%)	15 (10%)	11 (8%)	143
Subtotal	96 (27%)	93 (26%)	72 (20%)	49 (14%)	46 (13%)	356
FEMALES						
Kalyvia	8 (42%)	4 (21%)	3 (16%)	3 (16%)	1 (0.5%)	19
Borgo	23 (26%)	17 (19%)	22 (24%)	20 (22%)	8 (9%)	90
Acrocorinth	52 (40%)	32 (23%)	23 (17%)	19 (14%)	11 (8%)	137
Subtotal	83 (33%)	53 (21%)	48 (19%)	42 (17%)	20 (8%)	246
Total	179 (30%)	146 (24%)	120 (20%)	91 (15%)	66 (11%)	602

After Panayiotopoulos 1985, p. 242.
Borgo = village of Corinth; Kalyvia ("below Acrocorinth") = Anaploga.

Most attention focuses on Acrocorinth, where residents had the protection of the fortified castle. In 1676, near the end of this cemetery's use period, the British traveler Wheler and his French doctor companion, Jacob Spon, placed three mosques and five or six small churches with attendant residences on Acrocorinth. Wheler further mentions knots of six, 10, and more than 20 houses surrounded by orchards of orange and lemon trees, set about by cypress trees, with corn (grain) fields in between. These produced good oil and wine and much grain. As noted earlier, the main village consisted of 80–100 houses surrounding a marketplace, as well as a church dedicated to the Panayia and two mosques.[43]

The Venetians captured Acrocorinth without resistance from the Turkish garrison on August 9, 1687. During their short period of governance, in addition to strengthening the walls of Acrocorinth, the Venetians constructed defensive walls on either side of the avenue for communication between Corinth and its port of Lechaion. Despite the added protections, population seems to have declined under Venetian control. The population that Evliya had estimated at 900 houses (400 on Acrocorinth and 500 below) in 1668, even though greatly exaggerated,[44] had shrunk considerably. Grimani's census of 1700 enumerates a total of only 192 households: 79 families on Acrocorinth consisting of 280 individuals, 102 families of 275 individuals in the Borgo, and 11 families of 47 individuals in Kalyvia, a hamlet below Acrocorinth (Table 5).[45]

Because the sample of graves and individuals from the 17th-century Panayia Field cemetery published in this article is relatively large, it has already allowed comparison with other cemeteries both at Ancient Corinth and elsewhere. These comparisons have revealed several unusual qualities, probably closely related to the relatively small population living in the lower town at Ancient Corinth and to the troubled times during which they lived. As additional cemeteries are investigated as social behavioral units, the possibilities for revealing new patterns through such comparative research will become even greater.

43. Wheler 1682, p. 439.
44. MacKay 1968, p. 387.
45. Panayiotopoulos 1985, pp. 240, 242.

This content downloaded from 78.100.65.226 on Fri, 11 Oct 2013 01:17:53 AM
All use subject to JSTOR Terms and Conditions

CATALOGUE

Graves in the Panayia Field Cemetery

1 Grave 1996-7 Fig. 82

Muslim-style grave, oriented S 80° W, >1.00 × ca. 0.60 × 0.49 m. Located 7 m southeast from the southeast edge of the early-17th-century cemetery, dug into the northeastern ruins of Late Roman bath. Eastern end cut away by a subsequent wall-robbing trench.

Female, 35–45 years. Extended on back with head to west, facing upward and slightly toward the right (south); upper thighs extended far apart; arms extended along sides with left palm down and right palm up.

Ovoid-shaped skull within brachycrany range, cranial index 80.55, missing face. Skeleton damaged with bones missing from below mid-thighs. Lower front teeth and some upper front teeth lost before death; evidence for severe caries and periodontal disease. Large amount of torsion for deltoid muscles on both humeri of upper arms indicate that individual had been accustomed to heavy lifting during her life. Sex determined by gracile bones. Age range based on dental wear and evidence of some spinal degenerative joint disease (hereafter, DJD).

2 Grave 1997-1 Figs. 50, 82

Muslim-style grave, oriented W, 1.70 × 0.80 × 0.37 m. Two individuals represented. Articulated skeleton B displaced remains of earlier burial A.

A. Disarticulated burial. Female, older adult, age unknown. Portion of rhomboid-shaped skull reconstructed. Disarticulated remains include rib and vertebral fragments, portions of right scapula, left humerus, some finger bones, pieces of left pelvis and femur. Lower front teeth lost shortly before death. Sex determined by gracile bones and wide sciatic notch of pelvis. Older age indicated from signs of degenerative wear in joints of right shoulder, left hip, and knee.

B. Articulated burial. Male, 30–35 years; stature 165.23 cm (5′4″). Extended on back with head to west resting on its right side, facing south; legs extended with right knee bent outward from left but with feet together; right elbow bent outward with right forearm crossed over left hand near pelvis. Spheroid-shaped skull within brachycrany range, cranial index 80.87, narrow face with some alveolar prognathism, broad chin, and flaring gonials. Upper limbs missing. Mild periodontal disease and loss of both lower 2nd molars before death. Pitting scars of *cribra orbitalia* from childhood anemia and pitting scars above each ear opening from childhood ear infections. Chronic brucellosis infection represented by lesions in lower thoracic and lumbar spine. Lesions for costoclavicular ligaments on both clavicles, greater on right side, suggest individual used shoulders for heavy lifting. Pulling stress on the median head of gastrocnemius attachment on lower femora from overuse of thighs with knees flexed, with left knee also stressed.

Multiple developmental defects of the spine. The 2nd–3rd cervical block vertebra in the neck along with 4th cervical's left neural arch is smaller than the right side; and the right side of 5th cervical's widely cleft neural arch is incorporated into right side of 6th cervical's neural arch, making the right side much larger than the left side. The 7th and last cervical in the neck combined with the 1st and 2nd thoracics to form a block vertebra; right side of 2nd thoracic neural arch slightly smaller than left side with adjacent right rib facets for both affected thoracics, smaller than left side. Slightly smaller left side of neural arch than right side for 3rd thoracic, while 4th and 5th thoracics formed another block vertebra. The 6th thoracic is normal except for left horizontal apophyseal facet (instead of normal vertical) with matching adjacent facet on 7th thoracic, and left side of neural arch of 7th thoracic smaller than right side. The rest of the spine is normal. The number of block vertebrae indicates that this man suffered from

This content downloaded from 78.100.65.226 on Fri, 11 Oct 2013 01:17:53 AM
All use subject to JSTOR Terms and Conditions

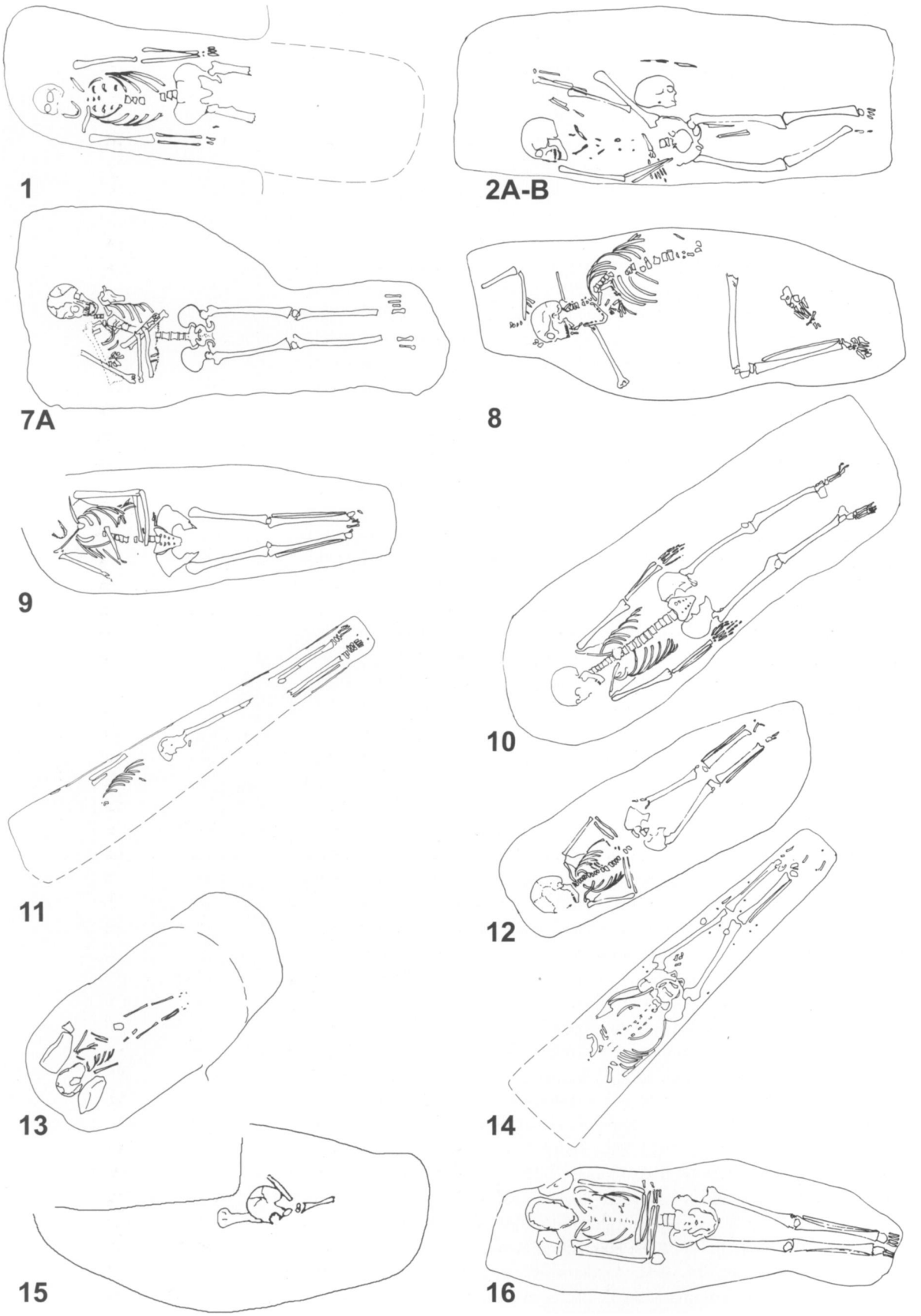

Figure 82. Graves 1, 2, 7–16

This content downloaded from 78.100.65.226 on Fri, 11 Oct 2013 01:17:53 AM
All use subject to JSTOR Terms and Conditions

Klippel-Feil syndrome type I (Fig. 50), causing right-sided scoliosis and stiffness of the neck.

Sex determined by robust bones, ossified thyroid cartilage, narrow pubic arch and sciatic notch of pelvis. Age based on pubic symphysis. Stature estimated based on combined lengths of femur (43.0 cm) and tibia (34.4 cm).

3 Grave 2000-4 Figs. 63, 64

Grave of unassigned style, ca. 1.80 × 0.70 × 0.21 m. Secondary deposit of bones one layer deep. Minimum of six individuals represented. Coin 2000-139 found in fill.

A–C. Adults: (A) a young female, (B) a male, (C) a young male. Skulls missing, remaining skeletal remains commingled with three sets of humeri and ulnae from three adults. One set gracile female, and two sets robust male. One complete robust mandible with dental wear suggestive of young adult age. Several other skeletal elements and bone fragments represented, with some rodent gnawing. Cupric stain on one finger bone. The arms of both men reflect heavy use flexing and extending arms outward with great force on right sides.

D. Adolescent, 16–17 years. Skull fragments, mandible, left humerus, and pubic bone fragment. Age determined by development of unerupted 3rd molars.

E. Child, 8.5–9.5 years. Skull fragments, left femur, and vertebral fragments. Active pitting lesions of *cribra orbitalia* in both eye orbits indicate anemia at time of death (cf. Fig. 61). Fine pitting lesions with periosteal plaque formation on glabella above nose and finely raised lesions on inside of frontal reflect infection accompanying the anemia. Fine pitting lesions above left ear opening indicate past ear infection. Age estimated from diaphyseal length of femur (30.3 cm).

F. Infant, 24–36 months. Fragments of skull, ribs, vertebrae, femur, and complete left humerus. Severe porotic hyperostosis with raised lesions and thickened skull typical of thalassemia (Figs. 63, 64), accompanied by active *cribra orbitalia* lesions in eye orbits. Age determined from diaphyseal length of humerus (12.5 cm).

4 Grave 2000-5

Grave of unassigned style, ca. 1.00 × 0.80 × 0.08 m. Secondary deposit of bones one layer deep.

Male, older adult. Reconstructed portion of cranial vault with fragments of mandible, fragments of some ribs and scapula, shafts of both humeri, and proximal ends of ulna and radius from left forearm. Thick layer of calculus covering bite surface and sides of molar tooth indicated that individual suffered prolonged illness prior to death. He was accustomed to heavy work raising and rotating his arms outward as reflected by large torsion of deltoid areas and stress on pectoralis major.

5 Grave 2000-6

Grave of unassigned style, ca. 1.70 × 0.60 × 0.23 m. Secondary deposit of bones three layers thick surrounding three skulls.

Commingled remains of four adults: (A) male, ca. 25 years; (B) male, 30–35 years; (C) male, 35–39 years; (D) adult, sex unknown, 30–39 years. Some bones with rodent gnawing. Three reconstructed cranial vaults, two with matching maxillae, and fragments of one mandible. Individual A's skull spheroid-shaped within hyperbrachycrany range, cranial index 91.07, and very fine pitting lesions cover top of skull, suggestive of overlying scalp infection. B's skull long ovoid-shaped with pronounced occipital protuberance. C's skull ovoid-shaped within mesocrany range, cranial index 79.23. Four different sizes of humeri. Fragments of other upper limb bones, ribs, vertebrae, damaged sacrum. Left pelvis with narrow sciatic notch, pubic symphysis age 35–39 years; right pelvic piece with pubic symphysis age 30–35 years. Several pieces of lower limb bones, right patella with

This content downloaded from 78.100.65.226 on Fri, 11 Oct 2013 01:17:53 AM
All use subject to JSTOR Terms and Conditions

vastus fossa, and some robust foot bones. Evidence of heavy use of arms for all three males, and one femur shows stress on gastrocnemius. Dental wear used to estimate younger male age.

Metacarpals from left hand and damaged ilium belonging to child from grave **7** mixed with adult bones.

6 Grave 2000-7

Grave of unassigned style, ca. 0.70 × 0.30 × 0.13 m. Secondary deposit of a skull and a few other bones.

Adult male. Portion of right side and back of skull vault with thickened diploe and right interparietal ossicle. Two rib fragments, damaged left clavicle, proximal right ulna, left 4th metatarsal. Pitting lesions for costoclavicular ligament on clavicle indicate heavy use of left shoulder. Sex determined by very robust bones and large occipital protuberance.

7 Grave 2000-8 Fig. 82

Christian-style grave, oriented essentially W, 1.91 × 0.50–0.91 × 0.20 m. Intruded into fill of grave **8** causing elements of previously displaced individuals to be redeposited above it. Four individuals represented. B–D are disarticulated burials in jumble of bones above articulated burial A. Associated are two iron nails.

A. Articulated burial. Male, 45–50 years; stature 165.29 cm (5′4″). Extended on back with head to west tilted slightly upward to face feet (east) and to left, with jaw open; legs fully extended with both knees and ankles separated somewhat; both arms folded at acute angle over chest, right over left, with left hand near center of right humerus and right hand over sternum.

Most of skeleton represented, with matching left humerus from **8**. Partially reconstructed skull appears ovoid-shaped. Severe dental wear and periodontal disease with interproximal caries in lower left 3rd molar, abscesses associated with upper 1st molars, and loss of lower left 2nd molar before death. Fine pitting scars above both ear openings reflect childhood ear infections. Healing injury to talus of right ankle, and fine linear lesions on inner aspect of some rib fragments indicate lung infection. Patellae show vastus fossa developmental trait. Individual was accustomed to lifting and carrying heavy objects, indicated by deep lytic lesions for costoclavicular ligaments and stress on muscle attachments of both clavicles, scapulae, humeri, and radii, greater on right side. Sex determined by robust bones, fragments of ossified thyroid cartilage, and narrow sciatic notch of pelvis. Age based on pubic symphysis. Stature estimated from field measurement of maximum length of femur (43 cm).

B, C. Children, 4.5–5.5 years and 7.5–9.5 years, respectively. Skull fragments, loose teeth, several rib fragments, several vertebrae, two sizes of upper and lower limb bones, matching pair of older child's foot bones. Ages estimated on diaphyseal lengths of long bones and dental development for older child. B suffered severe active anemia at time of death, indicated by severe active pitting lesions of *cribra orbitalia* in left eye orbit, along with fine pitting lesions above both ear openings from ear infections. Large flattened oval area (2.4 × 2.7 cm) on right side of C's head reflects blow to the head that pushed the bone inward; wound healed with some infection.

D. Adult, unknown sex and age. Fragments of upper and lower limb bones that do not match those from any other burials.

8 Grave 2000-9 Figs. 22, 66, 82

Grave of unassigned style, oriented WSW (pelvis–head), 1.65 × 0.65 × >0.12 m. Obviously disrupted an earlier grave in which the remains of three earlier burials had once rested. Grave **7** intruded into its fill.

This content downloaded from 78.100.65.226 on Fri, 11 Oct 2013 01:17:53 AM
All use subject to JSTOR Terms and Conditions

Female, 25–27 years. Pelvis, lower left leg, some hand and foot bones missing. Semiflexed on right side with head to west facing south, mandible displaced ca. 14 cm east of skull, and torso twisted on right side of back; right thigh projects southward ca. 85° from spine, with right lower leg at right angle pointing east; articulated left foot lay midway between pelvis and extended right foot; right hand lay under mouth, the left over right rib cage.

Intact broad sphenoid-shaped skull within brachycrany range, cranial index 83.13, narrow straight nose, small mandible with rounded chin. Complete hyoid and mesosternum. Matching left humerus, radius, and femur shaft from grave 7. Pelvis, lower left leg, some hand and foot bones missing. Metastatic cancer lesion suggested by lytic lesion, 1.2 cm × 1.8 cm, penetrating left side of frontal with ragged, sharp border surrounded by fine pitting lesions (Fig. 66). Individual had suffered from periodontal disease and the loss of one lower molar before death. Evidence of tendonitis of long head of biceps on humerus of right arm from overuse lifting arm overhead (unknown for left side). Individual was accustomed to rotating arms inward with some force, with greater stress on right arm. Sex determined by gracile bones. Age based on dental wear and fusion of clavicular sternal ends.

9 Grave 2001-2 Figs. 45, 82

Christian-style grave, oriented S 78° W (feet–pelvis) and S 90° W (pelvis–neck), 1.49 × 0.58 × >0.11 m.

Female, 23–24 years, stature 158.32 cm (5′2″). Skull missing, only chin piece remains. Extended on back with head area to west, with mandible displaced ca. 40° off line; legs fully extended with knees separated by 0.07 m and ankles by 0.04 m and feet standing straight up on heels; upper arms flared outward from shoulders to elbows, with left forearm folded across abdomen at L1–L3 at right angle to spine and right forearm bent back across chest toward left shoulder with right hand over left ribs. Tiny leg bones of fetal newborn in grave fill.

Left forearm displays healed mid-shaft fracture to ulna; evidence for recent compression fractures to 2nd and 3rd lumbars in lower back. No signs of functional stress. Developmental variants include last lumbar sacralized, transitional facets moved up to 11th thoracic, and 12th ribs did not develop as part of cranial shifting of vertebral borders during embryonic development. Os navicular (bony separation of this tarsal) (Fig. 45) on left foot (unknown for right foot). Sex determined by wide sciatic notch and small femoral head diameter. Age based on incomplete fusion of sternal end of clavicle and dental wear on few teeth present. Stature estimated on combined lengths of femur (42.4 cm) and tibia (33.2 cm).

10 Grave 2001-3 Figs. 11, 82

Muslim-style grave, oriented S 51° W, 2.15 × 0.70 × >0.25 m.

Female, 50+ years, stature 157.07 cm (5′2″). Extended on back with head to southwest and turned on right side to face southeast and mouth agape; legs fully extended with knees and ankles widely separated and left leg turned slightly outward; arms fully extended along sides with hands at hips, palms down.

Ellipsoid-shaped skull within mesocrany (medium) range, cranial index 79.10, narrow lower jaw and chin (upper face missing). Skull bones abnormally thick (1 cm). Front teeth chipped. One lower molar associated with abscess lost before death, and two other molars destroyed by caries. Small protostylid pit on lower 3rd molars. Signs of functional stress in both shoulders and arms, and both hands show hyperextension of fingers. Individual's neck reflects rotation stress and the back shows repetitive loading stress throughout life, along with stress on both knees. Developmental variants include type II sternum, tiny septal aperture on both humeri, small vastus fossa on both patellae, and symphalangism (fusion of phalanges) in 5th toes. Sex determined by wide sciatic notch and pubic arch.

This content downloaded from 78.100.65.226 on Fri, 11 Oct 2013 01:17:53 AM
All use subject to JSTOR Terms and Conditions

Age based on spinal DJD and pubic symphysis. Stature estimated on combined lengths of femur (40.8 cm) and tibia (33.7 cm).

11 Grave 2001-4 Figs. 8, 28, 81, 82

Christian-style grave, oriented S 51° W, 1.94 × 0.30 (at feet) × >0.18 m (coffin depth). Coffin indicated by plentiful remains of wood and iron nails indicating the coffin fit closely inside the grave with only 4 cm to spare on northwest side. Shape mirrored grave outline with straight sides tapering toward a squared foot end.

Male, 15–16 years, stature 174.57 cm (5′7″). Skull and most of body damaged. Extended on back with head area to southwest; legs fully extended with both knees and ankles separated by 4 cm while feet turned very slightly toward left; left upper arm lies alongside rib cage with all other arms parts cut away by intrusion of grave **14**. Pair of iron boot-heel cleats (Fig. 28) found standing vertically between individual's heels.

No apparent pathology or functional stress. No dental pathology except for some calculus. Large ossicle with two smaller ones at lambda on back of skull. Protostylid pits on lower 1st molars. Faint enamel hypoplasia band on canine reflects past metabolic disturbance during infancy around 34 months. Sex determined by large femoral head diameter, narrow sciatic notch, and large teeth. Age based on lack of epiphyseal closure of hands, feet, and leg bones, and on dental development. Stature estimated in situ on length of femur (47 cm).

12 Grave 2001-5 Fig. 82

Muslim-style grave, oriented S 45° W, 1.57 × 0.56 × 0.34 m.

Child, 7–8 years. Extended on back with head to southwest and turned ca. 60° onto right side to face southeast with mouth closed; legs fully extended with knees and ankles quite close together and feet turned slightly to right; upper arms flared outward from shoulders to elbows with both forearms bent back toward lumbar region with both hands mingled over lower abdomen. Young child with no signs of pathology, but evidence of functional stress from heavy lifting or pulling on costoclavicular ligament of right clavicle (absent on left clavicle). Carabelli's cusp on deciduous and permanent 1st molars. Age determined by dental development.

13 Grave 2001-6 Fig. 82

Christian-style grave, oriented S 51° W, 1.30 × 0.55 × 0.38 m at foot. Probably dug 0.25 m deep from top of reddish 7th-century level. Body too small (0.75 m long) for size of grave. Two limestone blocks (18 × 15 × 6 cm, 18 × 12 × 7 cm) flank head.

Infant, 9–10 months. Extended on back with head to southwest and propped up and turned slightly to left to face over left rib cage; legs fully extended with knees and ankles somewhat close together; upper arms flare outward from shoulders to elbows, with left forearm bent at right angle back toward spine so left hand rests over left abdomen while right forearm appears disarticulated alongside right hip. No apparent signs of pathology. Bilateral remnant of mendosa suture on back of skull. Age determined by dental development and in situ diaphyseal long bone lengths.

14 Grave 2001-7 Figs. 81, 82

Muslim-style grave, oriented S 44° W, 1.71 × 0.42 × >0.25 m.

Male, 30–35 years, stature 160.72 cm (5′3″). Skull and most of upper body missing. Extended on back with head area to southwest; legs fully extended with ankles separated by 3 cm; upper arms lie parallel to rib cage, with left forearm slightly bent to place left hand over genital region and right forearm slightly bent

This content downloaded from 78.100.65.226 on Fri, 11 Oct 2013 01:17:53 AM
All use subject to JSTOR Terms and Conditions

to pass beneath right ilium; right hand beneath pelvis palm down. Evidence for functional stress from overuse extending ankle with knee rotated inward on lower right femur; absent on left side. Developmental variants include 3rd metastyloideum with separate ossicle (separation of styloid on 3rd metatarsal) on left hand (right hand not affected) and 1st caudal of coccyx sacralized (fused to sacrum during development). Sex determined by narrow pubic arch and robust bones. Age based on pubic symphysis and lack of spinal DJD. Stature estimated on combined lengths of femur (41.4 cm) and tibia (32.2 cm).

15 Grave 2001-8 Fig. 82

Grave of unassigned style, 1.77 × 0.80 × >0.10 m. Intruded into south portion of underlying grave **18**. Five complete iron nails in fill possibly from intrusion.

Male, 30–35 years, stature 163.43 cm (5′4″). Disarticulated heap of bones trending east–west. Mostly skull pieces, bones from right arm, right hip and thigh. Rest of skeleton missing. Fetal mendosa suture failed to fuse before birth leaving a large "Inca" ossicle on back of skull; right humerus displays small septal aperture. Sex determined by narrow pubic arch and sciatic notch; age based on pubic symphysis. Stature estimated on femur length (42.2 cm).

16 Grave 2001-9 Figs. 59, 82

Christian-style grave, oriented S 86° W, 1.90 × 0.64 × >0.25 m. Two rough limestone blocks frame head; small stone props up right elbow; stone props up head.

Male, 25–30 years, stature 170.23 cm (5′6″). Extended on back with head to west, propped up on stone to face feet (east); legs fully extended with knees separated by 4 cm and ankles together; feet extend further and turn toward right while resting against grave end; arms folded across abdomen at L1–L3 at right angles to spine, with hands at opposing elbows and left closer to head than right. Damaged skull ovoid in shape. Somewhat pointed chin. No dental pathology. Lower 3rd molars did not develop, and lower 1st molars show protostylid pits. Spaces between lower central incisors, right lateral incisor and canine, and functional stress on joint of left side lower jaw.

Individual's right leg rendered lame during childhood when the femoral head slipped downward before fusing to the shaft, known as slipped epiphysis (Fig. 59). Functional stress from heavy lifting or pulling reflected on costoclavicular ligament attached to right clavicle, absent on left side. Developmental variants include right remnant mendosa suture back of skull, facet for missing small ossicle that separated from right side of posterior process of axis vertebra in neck, and separate ossicles for both ulnar styloids. Sex determined by robust bones and narrow sciatic notch and pubic arch. Age based on dental wear and lack of spinal DJD. Stature estimated from combined lengths of femur (44.7 cm) and tibia (36.9 cm).

17 Grave 2001-10 Figs. 42, 72, 83, 98

Christian-style grave, oriented S 87° W, 2.04 × 0.67 × >0.23 m. Two individuals represented.

A. Articulated burial. Male, 30–35 years, stature 170.23 cm (5′6″). Extended on back with head to west, propped up ca. 35° and turned ca. 45° to right to look over right shoulder; legs fully extended with knees and ankles separated by 7 cm and feet extended further east and slightly upward; arms folded across abdomen at right angles to spine from slightly outward flaring right elbow, with hands in middle of opposite forearm and right arm closer to head than left. A coin (2001-197) of Mehmed III (A.D. 1595–1603) above A's right shoulder (Fig. 98:21).

This individual has an ovoid-shaped skull within brachycrany (round) range, cranial index 82.66, slightly bulging occipital, medium face with projecting narrow nose, medium square chin, and fine pitting of brow ridges and glabella.

This content downloaded from 78.100.65.226 on Fri, 11 Oct 2013 01:17:53 AM
All use subject to JSTOR Terms and Conditions

No dental pathology except for some calculus on lower front teeth. Upper and lower left 3rd molars did not develop, and lower molars show small protostylid pits. Small round lesion approximately 0.6 cm diameter with beveled inner border and sharp outer border near bregma on parietal from left side of skull. Old severe compression fracture on 1st lumbar in lower spine, and goutlike lesion on scaphoid from left wrist.

Functional stress from lifting or pulling with forceful repetitive rotation of left forearm with palm of hand downward; right forearm not affected. Signs of habitual overuse extending legs, and kneeling on right leg reflected in wear facet on 1st metatarsal; absent on left side. Developmental variants include bilateral retromastoid ossicles on skull (Fig. 42), incomplete left transverse foramen on atlas vertebra. Sex determined by large femoral head diameter and narrow sciatic notch and pubic arch. Age based on dental wear and pubic symphysis. Stature estimated from combined lengths of femur (44.4 cm) and tibia (37.4 cm).

B. Disarticulated burial. Male, 35–45 years. Jumble of bones lying over and alongside right leg of A, with skull standing upright facing east at right ankle. Fairly intact skull, but missing several parts of skeleton. Ovoid-shaped skull within brachycrany (round) range, cranial index 80.56, wide face, broad nose, and square chin. Evidence for periodontal disease, large abscess associated with upper left 1st molar, while upper right 1st molar was lost before death. None of the 3rd molars developed. Linear enamel hypoplasia on canine reflects metabolic stress during infancy between 24 and 36 months. Pathology includes healed, round depression fracture ca. 1.0 cm diameter on forehead above left eye, and osteitis (bone infection) in both fibulae from lower legs. Unable to determine functional stress. Sex determined by robust skull markings and age based on dental wear.

18 Grave 2001-11 Fig. 83

Christian-style grave, oriented S 81° W, 0.85 × 0.40 × >0.12 m. Possible coffin suggested by seven iron nails, but no wood present.

Infant, 18–20 months. Extended on back with head to west and propped up ca. 60° to face feet with chin resting on vertebrae; left leg fully extended; right leg and feet missing; left upper arm angles downward across torso; forearms and right humerus missing. Fragmented remains with no apparent signs of pathology. Age determined by dental development.

19 Grave 2001-12 Fig. 83

Christian-style grave, oriented S 83° W, 1.15 × 0.43 × >0.14 m. Possible coffin (ca. 1.03 m long) suggested by 12 iron nails, seven in situ with points up, flanking head and along left side, but no wood present.

Child, 4–5 years. Extended on back with head to west; legs fully extended with knees and ankles separated ca. 3 cm; upper left arm lies alongside left rib cage; both forearms folded across torso, with left running diagonally toward right shoulder and right at right angle to spine (right humerus missing). Fragmented remains with no apparent pathology. Age determined by dental development.

20 Grave 2001-13 Figs. 24–26, 83

Grave of unassigned style, oriented S 84° W, 1.90 × 0.47 × >0.21 m.

Male, 20–21 years, stature 167.35 cm (5′5″). Extended face down with head to west; legs fully extended parallel to one another with knees and feet equally apart; upper right arm parallels rib cage with forearm bent beneath upper chest to place right clenched fist at left shoulder; left hand on dorsal surface at point where left elbow would fall if it paralleled left rib cage, indicating left elbow flared widely from body. Iron hook (MF-2001-26) penetrating left shoulder below left clavicle (Fig. 24). Bronze D-shaped ring under chest; rhomboidal polished bone ornament

This content downloaded from 78.100.65.226 on Fri, 11 Oct 2013 01:17:53 AM
All use subject to JSTOR Terms and Conditions

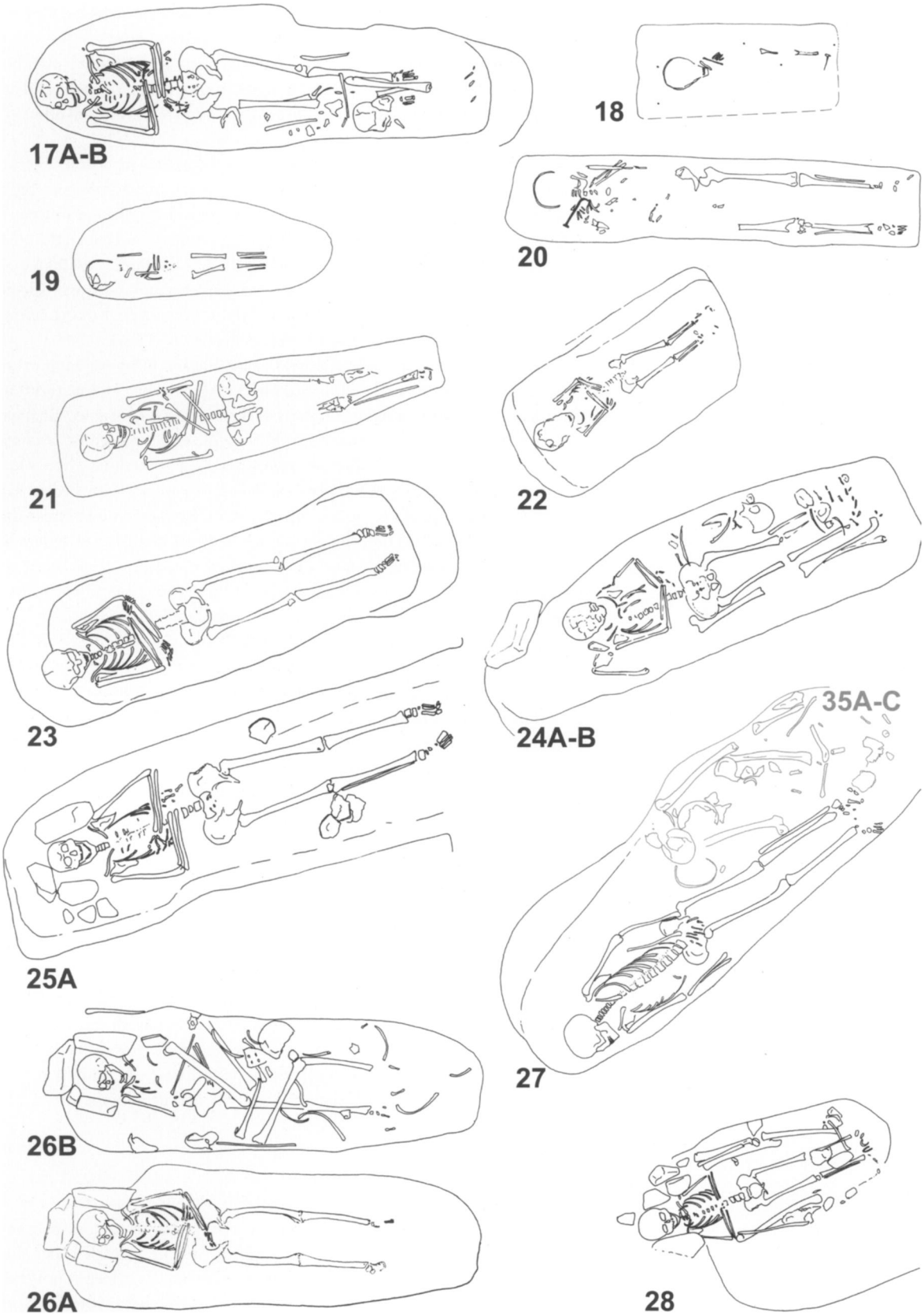

Figure 83. Graves 17–28

This content downloaded from 78.100.65.226 on Fri, 11 Oct 2013 01:17:53 AM
All use subject to JSTOR Terms and Conditions

with perforation in center under chest; small bronze wire loop with two ends not quite meeting under chest. Stack of five Turkish *akches* (coins 2001-189, 2001-190, 2001-191, 2001-192, 2001-193); three dated A.D. 1595–1603, one A.D. 1603–1617 (holed), and one, under chest, of uncertain date (Fig. 26).

This young man obviously died while impaled by the iron hook, which had most likely penetrated the upper portion of the lung. Death was probably slow in coming as he writhed on the hook. Placement of the body in the grave suggests rigor mortis had set in while the man hung from the hook before being lowered into the grave with the hook in place (Fig. 25). The hook's curve was found resting against the angle of the left side of his jaw.

Unfortunately most of the skeleton had eroded away, leaving pieces of the left clavicle with perimortem (around the time of death) fractures and three rib fragments from that area with perimortem fractures associated with damage caused by hanging from the hook. His lower jaw shows a broad square chin, crowded lower teeth, and molars with protostylid pits. No dental pathology except for some calculus on lower front teeth. Pitting scars of *cribra orbitalia* in left eye orbit from childhood anemia. Functional stress on costoclavicular ligament of right clavicle (unknown for left side) from heavy lifting or from pulling; habitual kneeling on right leg reflected by wear facet on 1st metatarsal of right foot, absent on left side. Sex determined by large femoral head diameter, ossified thyroid cartilage, large teeth, broad chin, and vertical ramus of mandible. Age based on dental wear and incomplete fusion of sternal ends of clavicles. Stature estimated from radius length (23.2 cm).

21 Grave 2001-14 Figs. 9, 51, 83

Christian-style grave, oriented S 74° W, 1.78 × 0.27–0.42 × >0.17 m. Possible coffin deduced from shape and size of grave and recovery of six iron nails (Fig. 9) outlining head, left shoulder, left hip, and right lower leg. No wood found.

Male, 30–40 years. Extended on back with head to WSW, facing essentially upward and turned ca. 25° to left, with mouth slightly open; legs fully extended with knees separated by ca. 8 cm and right foot extended beyond ankle; arms folded across chest, right over left to place right hand over middle of left humerus and left hand over lower and middle right rib cage.

Ovoid-shaped skull within brachycrany (round) range, cranial index 82.08, wide face, medium chin with flaring gonials. Periodontal disease with caries destroying upper left 3rd molar and affecting two lower right molars; lower right 3rd molar impacted while upper left 3rd molar micro-tooth with crown diameter only 0.5 cm (Fig. 51). Linear enamel hypoplasia of canine reflects metabolic disturbance in infancy between 24 and 34 months. Signs of pathology include small pitting scars of *cribra orbitalia* in eye orbits from childhood anemia, osteitis (bone infection) in fibula and tibia of right lower leg. Functional stress for costoclavicular ligament attached to right clavicle from heavy lifting or pulling; absent on left side. Transitional facets moved up to 11th thoracic during embryonic development. Sex determined by robust skull markings, very narrow sciatic notch, and large femoral head diameter. Age based on dental wear and lack of spinal DJD.

22 Grave 2001-15 Figs. 7, 83

Christian-style grave, oriented S 54° W, 0.70 × 0.58 × ca. 0.30 m. Skeleton is clearly too small for size of grave.

Child, 3.5–4.5 years. Extended on back with head to southwest and propped up on earth to face feet (east); legs fully extended with knees and ankles quite close together; arms folded across abdomen at right angles to spine with left hand closer to pelvis, neither hand reaching the opposing elbow. Small amount of *cribra orbitalia* pitting scars in eye orbits from anemia. No other apparent pathology. Carabelli's

This content downloaded from 78.100.65.226 on Fri, 11 Oct 2013 01:17:53 AM
All use subject to JSTOR Terms and Conditions

cusp on upper deciduous and permanent 1st molars, and cleft transverse foramina of atlas and axis vertebrae in neck. Age determined by dental development.

23 Grave 2001-16 Figs. 13, 35–37, 40, 83

Christian-style grave, oriented S 64° W, 1.75 × 0.50 × 0.45–0.50 m. Coin 2001-185 of Valentinian I–II in fill near left ilium.

Male, 27–30 years, stature 167.84 cm (5′5″). Extended on back with head to WSW and propped up on the sloping west grave end to face feet (east), with mouth slightly open by 2 cm between two rows of teeth; legs fully extended with knees separated by 5 cm and ankles by 11 cm with feet extended beyond ankles and toes curled back toward body almost at right angles to metatarsals; arms folded across abdomen at right angles to spine from slightly outward flaring elbows, with right hand closed around left forearm immediately below elbow and left hand between right forearm and right ilium.

Unusual artificial flattening of back of skull, exaggerated by ground pressure deformation (Figs. 35, 36). Individual's skull would have been very broad without the cranial deformation. Either way, it remains within the hyperbrachycrany range, with large cranial index of 112.99 resulting from the deformation. Medium face with broad, slightly hooked nose, some alveolar prognathism, narrow jaw with flaring gonials, and small square chin. Evidence for periodontal disease with large amounts of calculus and loss of upper right 1st molar before death. Some teeth are chipped. Protostylid pit on lower molars. Linear enamel hypoplasia bands on canine reflect three separate instances of metabolic stress during infancy between 18 and 34 months.

Pathology includes periosteal disturbances from overlying skin irritations on lower ends of fibulae and tibiae of lower legs, and bony irritation and lesion above distal condyles on back side of femur above right knee. Functional stress left deep lesions on both clavicles for costoclavicular ligaments, greater on right side, from heavy lifting or from pulling. The normal raised ridge of linea aspera on the backside of the femora that usually appears more pronounced on males is not present on legs. Developmental variants include os acromion (separate bone for end of acromion) on both scapulae, small nonpenetrating ectodermal cyst above foramen magnum on back of skull, ossification of large portion of both styloid ligaments (Fig. 37), maxillary palatine cyst, unilateral fusion of hyoid, and unilateral right incomplete posterior bridge on atlas vertebra in neck. Shifting of vertebral borders during embryonic development produced additional small ribs on the 1st lumbar vertebra known as lumbar ribs (Fig. 40), along with the downward placement of transitional facets from 12th thoracic, separation of the 1st sacral segment (lumbarization) to become an additional lumbar vertebra, and incorporation of the first segment of the coccyx (tailbone) into the sacrum. Sex determined by large femoral head diameter and narrow sciatic notch and pubic arch. Age based on dental wear, lack of spinal DJD, and pubic symphysis. Stature estimated from length of femur (44.1 cm).

24 Grave 2001-17 Fig. 83

Christian-style grave, oriented S 63° W (pelvis–skull) and S 57° W (feet–pelvis), 2.00 × 0.61 × 0.32–0.44 m. Two individuals represented. Two small limestone chunks (the larger 9 × 6 × 5 cm) frame articulated burial A's head. Remnants of earthen shelves visible on both sides of grave. Late Roman (5th–6th century A.D.) coin 2001-186 in fill.

A. Articulated burial. Preadolescent, 11–12 years. Extended on back with head to WSW and propped up to face feet (east) and tilted and turned slightly to left; legs fully extended with knees separated by 5 cm and ankles by 7 cm, with

This content downloaded from 78.100.65.226 on Fri, 11 Oct 2013 01:17:53 AM
All use subject to JSTOR Terms and Conditions

feet turned to left at a higher level than torso; arms folded ca. 75° from outwardly flaring elbows across abdomen with both hands together, right above left, on left side of spine.

Fine pitting scars of *cribra orbitalia* in eye orbits from earlier anemia. Unilateral stress fracture (spondylolysis) through left side of 5th lumbar asymmetrical neural arch. Developmental variants include unilateral right mendosa suture remnant on back of skull, small bilateral tympanic apertures in floors of bony ear canals, transitional facets moved upward from 12th to 11th thoracic vertebra, and Allen's fossae on both femoral necks. Age determined by dental development and long bone diaphyseal lengths.

B. Disarticulated burial. Male, 25–35 years, stature 161.58 cm (5′3″). Jumble of disarticulated skeletal elements resting mostly on top and to the left (north) side of legs of A plus one or two leg bones beneath A's legs (in original interred position?).

Skull missing and erosion damage to remaining skeleton. Portions of lower thoracics from spine show apparent compression fracture. Signs of functional stress on arms and right clavicle from repetitive overuse flexing and rotating forearms along with heavy lifting or pulling. Developmental variants include lumbar asymmetrical neural arch and right patella with vastus fossa (unknown for left side). Sex determined by narrow sciatic notch, and age based on fusion of clavicle sternal end, lack of spinal DJD. Stature estimated from combined lengths of femur (41.0 cm) and tibia (33.3 cm).

25 Grave 2001-18 Figs. 15, 35, 69, 83

Christian-style grave, oriented S 69° W, >2.00 × 0.55 × 0.36–0.50 m. Two individuals represented. Three rough limestone blocks frame articulated burial A's head, one on either side and the third behind to the right (southwest); two smaller limestone blocks lie between the right side framing stone and the grave side wall. Remnants of earthen shelves on both sides of grave.

A. Articulated burial. Male, 30–35 years, stature 176.43 cm (5′8″). Extended on back with head to WSW on occiput facing up with mouth agape; legs fully extended parallel to one another with knees separated by 10 cm and ankles by 12 cm and feet extended beyond ankles, with left toes bent back toward ankle at 90°; arms folded across abdomen from outwardly flaring elbows at right angles to spine with left hand on right rib cage closer to head and right hand east of left forearm closer to pelvis.

Very robust man with broad sphenoid-shaped skull (Fig. 35) within hyperbrachycrany range, cranial index 97.53, medium face, narrow nose, wide jaw with flaring gonials, and medium chin. Periodontal disease with large amount of calculus, chipped teeth, and two teeth with caries and related abscess. Upper right and lower 3rd molars did not develop while upper left 3rd molar is quite small. Upper left canine impacted sideways into palate.

Benign button osteoma on left side of skull, and bones from both lower legs display periosteal irritation. Old smash injury to tip of middle finger from left hand. Raised linear lesions on inner surface of rib fragments (Fig. 69) reflect lung infection that may have caused death. Signs of functional stress on arms from overextending and flexing forearms with palms up. Right thumb also stressed and left leg shows stress from rotating the thigh inward with hip extended and knee flexed. Third trochanters on both femora. Sex determined by very robust bones and narrow sciatic notch. Age based on dental wear, rib ends, and lack of spinal DJD. Stature estimated from length of femur (47.8 cm).

B. Disarticulated burial. Child, unknown age. Only skull fragments and some damaged postcranial elements preserved; bones located near right knee of A. Fine pitting scars of *cribra orbitalia* in eye orbit from past anemia.

This content downloaded from 78.100.65.226 on Fri, 11 Oct 2013 01:17:53 AM
All use subject to JSTOR Terms and Conditions

26 Grave 2001-19 Figs. 14, 27, 83

Christian-style grave, oriented S 85° W, 1.96 × 0.63 × 0.37 m. Two individuals represented. Two limestone blocks (26 × 18 × 9 cm, 20 × 18 × 7 cm) frame articulated burial A's head, with a third stone standing vertically behind head. Complete bronze "nail" with square shank (MF-2001-38) in fill (Fig. 27).

A. Articulated burial. Female, 60+ years, stature 146.84 cm (4′8″). Extended on back with head to west resting on occiput and turned ca. 30° to right (south) with mouth agape; legs fully extended with knees separated by 11 cm and ankles by 14 cm, with feet turned outward ca. 45° on lateral sides; arms folded over abdomen from outwardly flaring elbows with left hand on pelvis and right hand near inside left elbow. Skeleton falls 35 cm short of grave's east end.

Very small, childlike skeleton with rhomboid-shaped skull within mesocrany (medium) range, cranial index 78.41, high vertical forehead, bulging occipital, medium face and nose, small jaw and chin. Mandible had shrunk with loss of several teeth and resorption of alveolar bone with temporomandibular joint dysfunction. Large caries in upper left 1st molar. Pathology includes old healed fracture of scapular acromion with dislocation of right shoulder, and large bony scar on crest of tibia from left lower leg. Both femur shafts bowed outward. Functional stress on costoclavicular ligament of right clavicle from heavy pulling or from lifting (not present on left side), right elbow joint and both forearms stressed from excessive rotation with palms down. Bending stress on spine and stressful neck rotation. Developmental variants include unilateral left humeral septal aperture, and transitional facets on 11th thoracic vertebra. Sex determined by very gracile bones and wide sciatic notch. Age based on dental wear and tooth loss, and severe spinal DJD. Stature estimated from combined lengths of femur (37.8 cm) and tibia (29.2 cm).

B. Disarticulated burial. Male, 30–35 years, stature 171.3 cm (5′6″). Bone elements scattered across and alongside A from chest to knees and beyond feet. Very broad sphenoid-shaped skull within hyperbrachycrany range, cranial index 103.73, rounded flat occipital, medium face, narrow, slightly curved nose, and broad bifurcated mastoids. Fine pitting brow ridges and glabella. Lower jaw missing. Enlarged incisive canal on palate. Only dental pathology is severe calculus covering occlusal surfaces of molars, indicative of long-term illness. Lateral incisors are chipped and upper 3rd molars never developed.

Some signs of periosteal disturbance on tibiae from both lower legs. Signs of functional stress from heavy lifting or from pulling, and left arm stressed from repetitive raising overhead (unknown for right side) along with stress on right thumb. Bony spicules on left heel of calcaneus reflect pulling stress on Achilles tendon from overextending and rotating foot (unknown for right side). Sex determined by robust bones and narrow pubic arch. Age based on dental wear, lack of spinal DJD, and pubic symphysis. Stature estimated from combined lengths of tibia (37.2 cm) and fibula (36.5 cm).

27 Grave 2001-20 Figs. 10, 52–55, 83

Muslim-style grave, oriented S 44° W, ca. 2.00 × ca. 0.60 × 0.38 m.

Male, 20–21 years, stature 171.24 cm (5′6″). Extended on right side of back with head to southwest and turned on right side to face southeast, mouth closed; legs extended with knees very slightly bent toward right and both feet turned to the right; arms extended along sides, palms down, left hand atop left hip and right hand beside right femoral head.

Birsoid-shaped skull within mesocrany (medium) range, cranial index 76.40. Low forehead, bifurcated mastoids, fairly straight, narrow nose, medium upper face with narrow mandible and small square chin. Slight dental prognathism and fine pitting of brow ridges and glabella. Large caries on upper left 2nd premolar, some

This content downloaded from 78.100.65.226 on Fri, 11 Oct 2013 01:17:53 AM
All use subject to JSTOR Terms and Conditions

dental chipping and calculus. Tiny protostylid pit in lower molars and Carabelli's cusp on upper right 1st molar. Dental developmental disturbances include extra (ectopic) narrow pointed tooth between upper central incisors (Fig. 52), while upper left 1st molar failed to develop, and upper right premolars rotated and crowded inward out of tooth row.

Individual died from a broken neck caused by hanging as reflected in characteristic "hangman's" fractures of upper cervical vertebrae in the neck (Figs. 53, 54). He also received blows to the left clavicle and left hip that resulted in perimortem fractures. His left hip was affected by painful and crippling aseptic necrosis of the femoral head (Fig. 55). He also shows old stress fractures through the neural arch (bilateral spondylolysis) of the 5th lumbar of the lower spine, associated with asymmetry of the inferior apophyseal facets and wedge-shaped vertebral body that left the 5th lumbar vulnerable to this kind of fracture.

Other developmental variants include type II sternum, bilateral remnant mendosa suture at back of skull, bilateral agenesis of lower portions of coronal suture on both sides of skull, small palatine torus, incomplete right lateral bridge on atlas, and unilateral left transitional facet on 10th thoracic vertebra. Left scapular os acromion, absent on right side. Signs of functional stress with deep lesions for costoclavicular ligaments and stress on both upper arms from heavy lifting or from pulling inward and overhead. Pronounced adductor tubercle on distal right femur (unknown for left side) from repetitive inward rotation of thigh with hip extended and knee flexed, while lower left leg shows overuse stretching left leg with foot dorsiflexed (unknown for right lower leg). Small wear facets on both 1st metatarsals of feet from habitual kneeling. Sex determined by robust bones and narrow sciatic notch and pubic arch. Age based on lack of fusion of sternal ends of clavicles, dental wear, and pubic symphysis. Stature estimated from combined lengths of femur (43.9 cm) and tibia (38.5 cm).

28 Grave 2001-21 Figs. 29, 83

Christian-style grave, oriented S 72° W for lumbars and S 66° W for cervicals, 1.32 × 0.49 × >0.26 m. Truncated east half of grave **31**.Three individuals represented. Head of articulated burial (A) placed in niche formed by rough limestone blocks, one framing each side with a third resting atop the other two. B and C are disarticulated bone elements redeposited from grave **31** disruption.

A. Articulated burial. Child, 6–7 years. Extended on back with head to WSW and propped up against western end of grave to face feet (east), with mouth open and chin resting on cervical vertebrae; legs fully extended with knees bowed inward slightly separated by 6 cm and heels by 8 cm with feet turned outward; arms folded over abdomen from outwardly flaring elbows at right angles to spine with hands together over spine. Associated artifacts are a Late Roman (4th–6th century A.D.) coin 2001-188 and a pair of iron boot-heel cleats (MF-2001-30A, B) standing upright at both heels (Fig. 29).

Ovoid-shaped skull with pitting scars from *cribra orbitalia* in eye orbits from earlier anemia. Both clavicles show functional stress on median head of deltoid from lifting arms repetitively to fixed level with left arm extended and rotated inward. Medium head of gastrocnemius stressed on both distal femora from excessive rotation of knees inward with ankles extended. Age determined by dental development and diaphyseal long bone lengths.

B. Disarticulated burial. Female, 17–18 years, stature 159.11 cm (5′2″). Left arm bones lying among other disarticulated bones. Left humerus, ulna, and radius showing functional stress on pectoralis major of upper arm from pulling action on fixed arm. Septal aperture on humerus. Sex determined by gracile bones and age based on recent fusion of distal ends of ulna and radius. Stature estimated on length of humerus (30.1 cm).

This content downloaded from 78.100.65.226 on Fri, 11 Oct 2013 01:17:53 AM
All use subject to JSTOR Terms and Conditions

C. Disarticulated burial. Infant, age unknown. Some postcranial bones among other disarticulated bones. Skull fragments with fine pitting lesions of *cribra orbitalia* in eye orbits from anemia, and some postcranial bones.

29 Grave 2001-22 Figs. 30, 62, 84, 85

Christian-style grave, oriented S 73° W, >1.30 × 0.51 × at least 0.40 m. Eastern (foot) end truncated by digging of grave **63**. Rough blocks of limestone frame the head of the deceased, one framing each side and the third (19 × 17 × 13 cm) resting atop the other two and covering the head. Coin (2001-195) of the 10th–11th century A.D. from fill.

Male, 19–20 years, stature 164.51 cm (5′4″). Extended on back with head to WSW and propped up ca. 45° and turned ca. 20° toward the left to look over left shoulder, with mouth agape and chin resting on vertebrae; upper legs fully extended with knees separated by 5 cm (lower legs missing); upper arms flare outward from shoulders to elbows with right forearm folded over abdomen at T10–T11 and right hand over left ribs, and with left forearm bent sharply back toward face with left hand over manubrium. Turkish *akche* (2001-216) of Osman II (A.D. 1618–1622) under jaw. Bone melon-bead pendant (MF-2001-39) from north of lower legs (Fig. 30). Diamond-shaped tile over right arm.

Broad sphenoid-shaped skull within hyperbrachycrany (very broad) range, cranial index 92.26, some dental prognathism, medium face with wide mandible and small chin. Squarish vertical forehead with bossing, flat skull top, pitting scars of *cribra orbitalia* in eye orbits, raised pitting scars of porotic hyperostosis on both sides and back of skull (Fig. 62) with internal lesions typical of intermediate thalassemia, a chronic congenital anemia. Other signs of thalassemia represented

Figure 84. Christian-style grave 29

This content downloaded from 78.100.65.226 on Fri, 11 Oct 2013 01:17:53 AM
All use subject to JSTOR Terms and Conditions

by squared and cupped lower lumbar vertebrae. Individuals affected by this form of thalassemia generally did not survive past young adulthood, thus the disorder most likely caused his death. He must have belonged to a local population carrying genes for the disorder, since other cases of thalassemia have been found in earlier populations of ancient Corinth.

None of the 3rd molars developed. Large protostylid pits on lower molars and large Carabelli's cusp on upper 1st molars. Upper right 2nd premolar rotated with space between it and 1st premolar. Some caries and calculus on teeth. Signs of functional stress on clavicles from repetitive raising of arms to fixed level. Developmental Allen's fossa on both femoral necks. Sex determined by very narrow sciatic notch, very large teeth, and robust skull markings. Age based on dental wear, lack of fusion of clavicular sternal ends, and recent fusion of distal radius and ulna. Stature estimated from length of humerus (29.9 cm).

30 Grave 2001-23 Figs. 29, 74, 85

Christian-style grave, oriented S 87° W, 1.85 × 0.54 × 0.45 m. Intruded into fill of child's grave **63**. At least two individuals represented.

A. Articulated burial. Female, 30–40 years, stature 153.56 cm (5′0″). Extended on back with head to west apparently facing upward; legs fully extended with knees and ankles separated by 19 cm and feet extended parallel to tibiae on exterior edges; arms folded over abdomen from outwardly flaring elbows at right angles to spine, with hands mingled over spine. Late Roman coin (2001-207) of ca. A.D. 378–383 found north of A's legs. Iron boot-heel cleat found upright next to A's right heel.

Damaged skull appears ovoid in shape. Severe periodontal disease with three caries. Upper front teeth finely chipped, tiny protostylid pit on lower left 2nd molar, and lower right 3rd molar failed to develop. Parietal fragments from both sides of skull abnormally thick up to 0.8 cm, with pitting scars and enlarged diploe, all signs of porotic hyperostosis reflecting chronic anemia during childhood.

Evidence of overlying skin irritation where left clavicle joins shoulder joint. Signs of functional stress on left arm from pulling with inward rotation of fixed arm (unknown for right side). Signs of repetitive overuse extending and rotating flexed thighs inward with knees flexed with extension and rotation of feet. Tibiotalar wear facets from habitual squatting on ankles. Developmental variants include small communicating ectodermal cyst above foramen magnum at base of skull, 3rd metastyloideum (separate ossicle for styloid) on left hand (unknown for right side). Sex determined by gracile bones, small femoral head diameter, and small teeth. Age based on dental wear and lack of spinal DJD. Stature estimated from combined lengths of femur (39.6 cm) and tibia (32.3 cm).

B. Disarticulated burial. Male, 27–30 years, stature 170.58 cm (5′6″). Bone stack over legs of A includes child's skull belonging to grave **63**. Damaged skeletal remains with some extra adult foot bones and tibia fragment with perimortem cut mark. Three iron boot-heel cleats and part of thick iron boot-heel cleat all found in extreme east end of grave and probably associated with disarticulated bones (Fig. 29, lower right). Large cube-shaped blue faience bead also found at eastern end of grave. Broad rhomboid-shaped skull within mesocrany (medium) range, cranial index 79.89, low forehead and broad square chin. Chipped front teeth, severe caries on premolar and molar, while upper left 1st molar lost just prior to death. Upper right 3rd molar failed to develop.

Signs of functional stress on both upper arms from pulling with inward rotation of fixed arms, and stress on both thighs. Developmental vastus fossa on patellae. Sex determined by robust bones, large femoral head diameter, and narrow sciatic notch and pubic arch. Age based on pubic symphysis and lack of spinal DJD. Stature estimated from length of humerus (32.0 cm).

This content downloaded from 78.100.65.226 on Fri, 11 Oct 2013 01:17:53 AM
All use subject to JSTOR Terms and Conditions

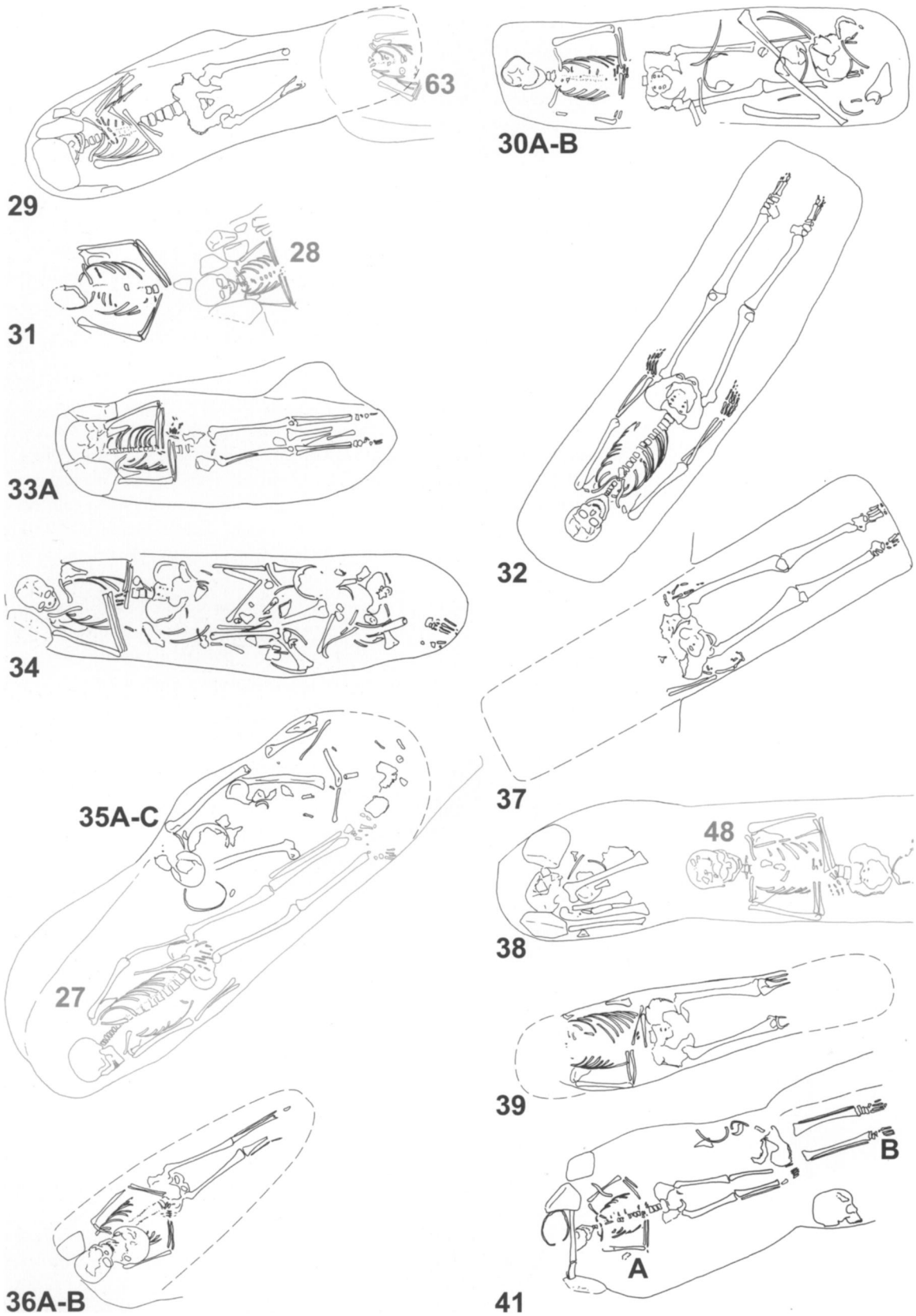

Figure 85. Graves 29–39, 41

This content downloaded from 78.100.65.226 on Fri, 11 Oct 2013 01:17:53 AM
All use subject to JSTOR Terms and Conditions

31 Grave 2001-24 Fig. 85

Christian-style grave, oriented N 85° W, >0.54 × 0.48 m × unknown depth.

Male, 27–30 years, stature 165.87 cm (5′4″). Torso and head extended on back with head to west and apparently lying face up with mouth agape and mandible resting on right clavicle; pelves and legs removed by digging of **28** and redeposited along sides of child in that grave; upper arms flare outward from shoulders to elbows, with forearms folded at ca. 110° across abdomen; both hands meet at spine above pelvis.

Most of skull destroyed by ground erosion, leaving only back portion with osteophyte protruding above occipital nuchal ridge from functional stress on trapezius muscle with repetitive forceful and prolonged suspension of arms and shoulders with neck extended backward. Upper arms, left clavicle, and radius from left forearm show pulling on fixed arms while left forearm flexed with palm upward. Mandible fragment shows broad square chin and gonial flaring, large caries, and loss of both 2nd molars and right premolar before death. Tiny protostylid pits on 1st molars. Developmental variants include right lateral bridge on atlas, left lateral hypoplasia on 5th lumbar vertebral body, and femoral 3rd trochanters. Sex determined by narrow pubic arch, robust jaw, and large teeth. Age based on dental wear and pubic symphysis. Stature estimated from combined lengths of femur (42.4 cm) and tibia (35.5 cm).

32 Grave 2001-25 Figs. 46, 60, 85

Muslim-style grave, oriented S 34° W, 2.13 × 0.60 × 0.45 m.

Male, 25–26 years, stature 173.87 cm (5′7″). Extended on back with head to southwest and facing up with mouth agape; legs extended with knees bowing very slightly upward and ankles turned outward; arms extended along sides with downward-facing palms, resting beside femoral heads.

Broad skull, nearly spheroid in shape, within hyperbrachycrany range, cranial index 90.96. Low forehead, some pitting on glabella and brow ridges, straight nose, medium face, and broad squarish chin. Ossified arytenoids cartilage. Very large teeth with crowding of lower incisors, periodontal disease, four caries, and one abscess. Large protostylid pit on lower 2nd molars and small pit on 1st molars.

Bilateral spondylolysis (stress fracture of neural arch) on 5th lumbar vertebra (Fig. 60) associated with asymmetrical development of neural arch and wedge-shaped vertebral body. Developmental variants include multiple lambdoid ossicles and bilateral remnant mendosa suture on back of skull, transitional facets moving down from 12th thoracic to 1st lumbar vertebra, bilateral incomplete posterior bridging on atlas, bifurcated neural arch with right-sided hypoplasia on 11th and 12th thoracic vertebrae (Fig. 46), and right-sided hypoplasia on 1st sacral segment, resulting in cleft neural arch. Sex determined by narrow pubic arch, large femoral head diameter, robust skull markings, and large teeth. Stature estimated from combined lengths of femur (49.0 cm) and tibia (39.5 cm).

33 Grave 2001-26 Figs. 31, 85, 86

Christian-style grave, oriented N 90° W, 1.48 × 0.51 × >0.26 m. Two individuals represented. Two rough limestone blocks (20 × 17 × 7 cm, 23 × 14 × 9 cm) frame head of articulated burial.

A. Articulated burial. Child, 10–11 years. Extended on back with head to west and propped up ca. 30° and turned to left ca. 35–40°; legs fully extended with knees separated by 6 cm and ankles by 8 cm with feet extending beyond ankles parallel to legs; arms folded across abdomen at right angles to spine from slightly flaring left elbow with left hand over spine closer to head and right hand below middle of left forearm. Associated objects were all found around neck and must represent a necklace (Fig. 31). Coins are Nuremberg jetons 2001-196, 2001-199

This content downloaded from 78.100.65.226 on Fri, 11 Oct 2013 01:17:53 AM
All use subject to JSTOR Terms and Conditions

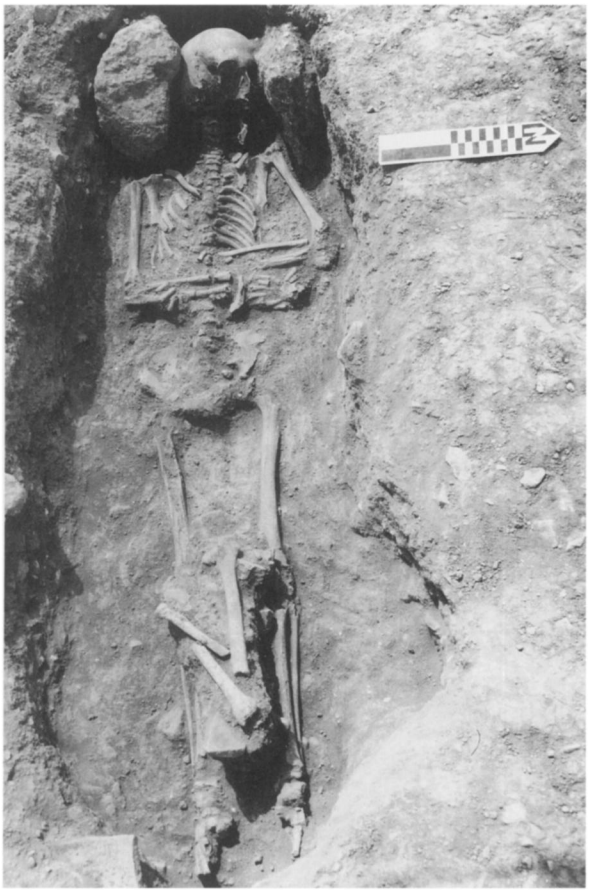

Figure 86. Christian-style grave 33

(Wolf Lauffer II, A.D. 1612–1651), and 2001-200 (H. Krauwinckel II, A.D. 1586–1635). There are also 135 small globular glass beads (MF-2001-40), alternating white and dark blue, with textile fragment adhering.

Ellipsoid-shaped skull. Cupric stains on right clavicle, right side of last cervical and 1st thoracic vertebrae along with right 1st rib indicate right side of chest area in contact with bronze or copper jetons. Another cupric stain on heel of calcaneus from left foot. Lower left deciduous 2nd molar in place with large occlusal caries. Large pitting scars of *cribra orbitalia* in eye orbits from past anemia, and pitting scars on skull base, greater wings of sphenoids extending to temporals, and fine pitting around left ear opening. Functional stress on conoid ligaments of both clavicles. Developmental variants include transitional facets moved upward from 12th to 11th thoracic vertebra, unilateral left lateral bridge and bilateral posterior bridging on atlas, and partially caudalized 5th sacral segment. Age determined by dental development and long bone diaphyseal lengths.

B. Disarticulated burial. Redeposited adult hand bones only. Scattered disarticulated bones above and beside lower legs of burial A.

34 Grave 2001-27 Figs. 58, 73, 85

Christian-style grave, oriented S 85° W, 2.00 × 0.48 × ca. 0.30 m. Three individuals represented. Head of articulated burial A placed in niche formed by two upright framing limestone blocks (23 × 19 × 10 cm, 17 × 13 × 9 cm) covered by a third rough limestone block.

A. Articulated burial. Male, 30–35 years, stature 170.35 cm (5′6″). Extended on back with head to west and propped up ca. 50° and turned to face ca. 20° to right of spine; legs fully extended with knees separated by 8 cm and ankles by 10 cm, with feet extended and ankles resting on outer edges of grave; upper arms

This content downloaded from 78.100.65.226 on Fri, 11 Oct 2013 01:17:53 AM
All use subject to JSTOR Terms and Conditions

flared outward from shoulders to elbows, with left forearm folded across abdomen at right angle to spine and hand below (east of) right forearm, and right forearm bent diagonally across chest toward middle of left humerus and hand atop left forearm. Yellowish orange glass gem (L. ca. 0.8 cm) found under right ribs to right of thoracic vertebrae.

Ovoid-shaped skull with metopism, medium face, slightly curved nose, medium rounded chin, and flaring gonials. Evidence for severe periodontal disease and one small caries. Upper left canine crowded toward premolar, leaving space between it and central incisor. Space also between upper right incisors; lower right canine rotated and crowded toward lateral incisor. Protostylid pits on lower 1st molars.

Cupric stain on distal backside of radius above right wrist, and another cupric stain on anterior upper end of tibia just below right knee. Old crushing injury to right shoulder (Fig. 58) and chest reflected by flattened and eroded shoulder joint and healed depression lesion on sternum. Old healed fracture with shortening bone deformity on 3rd metacarpal from center of right hand. Probable gout lesion with raised sharp border on 3rd cuneiform of left foot. Signs of functional stress on both clavicles and arms from heavy lifting or from pulling with arms rotated inward, down and back with forearms rotating with palms upward, and right wrist showing overuse grasping or clenching (absent on left side). Vertebral burst fractures and Schmorl's nodes on mid- and lower back reflect heavy loading stress on spine, and both thighs show stress with knees flexed. Large osteophyte from tendon of short head of biceps on the left femur from trauma to this muscle when knee was flexed and rotated outward. Developmental variants include enlarged incisive canal of palate, anterior cleft between 1st and 2nd sacral segments, and sacralized caudal of coccyx. Sex determined by robust bones, large femoral head diameter, and narrow sciatic notch and pubic arch. Age based on dental wear, lack of spinal DJD, and pubic symphysis. Stature estimated from combined lengths of femur (44.7 cm) and tibia (37.0 cm).

B, C. Disarticulated burials in a jumble of bones above and to right of A's legs; one skull rests on its right side facing ESE above and to left of A's left tibia; second skull lies to lower right side between A's lower legs facing left leg. A pair of articulated feet presses against southeast corner of grave cut and probably belongs to the taller B. B is a male, 30–35 years, stature 176.05 cm (5′8″), and C is a male, 30–35 years, stature 169.42 cm (5′6″).

Both males with narrow ovoid-shaped skulls within dolichocrany (long-headed) range, one (B) with cranial index 74.05. Both with low foreheads, slightly curved narrow noses, narrow faces. One with more pronounced nuchal ridge on back of skull than the other one. Only one mandible, with broad chin and flaring gonials; matching skull shows that upper and lower 3rd molars failed to develop, both upper 1st molars were lost before death, and some caries existed. Cupric stain on right side of other skull, with slightly asymmetrical nose, and evidence for periodontal disease, some caries, and loss of two upper molars just before death.

Fragment of lower thoracic vertebra displays signs of brucellosis. Three lower left ribs show healed fractures, and a left 5th toe displays old smash injury. Signs of functional stress on one pair of humeri from heavy lifting, and one pair of femora shows overuse rotating thighs inward with hips extended and knees flexed. Developmental variants include remnant mendosa suture on one skull, unilateral left retromastoid ossicle on other skull, unilateral left supracondylar process on one pair of humeri, matching atlas and axis vertebrae with incomplete transverse foramina, and a sacrum with cleft 1st segment. Sexes determined by two sets of robust bones, large femoral head diameters, and narrow sciatic notches and pubic arches. Ages based on two sets of pubic symphyses and dental wear. B's and C's stature estimated from combined lengths of matching set of femora (46.8 cm and 43.9 cm, respectively) and tibiae (39.7 cm and 37.0 cm, respectively).

This content downloaded from 78.100.65.226 on Fri, 11 Oct 2013 01:17:53 AM
All use subject to JSTOR Terms and Conditions

35 Grave 2001-28 Fig. 85

Grave of unassigned style, oriented roughly S 53° W, >1.90 × >0.58 × >0.22 m. Secondary reburial of commingled skeletal elements representing five disarticulated individuals stacked on top of grave **50** and remnant graves **64** and **68**.

A is a male, 30–35 years, stature 171.23 cm (5′6″); B is a male, 45–50 years, stature 170.74 cm (5′6″); C is a female, 20–21 years, stature 151.42 cm (4′10″), probably deriving from remnant grave **64**; D is an older child of unknown age; E is an infant, 30–36 months. (An extra male skull, sacrum, and lower arm bones belonging to grave **50** removed and placed with that burial.)

Ovoid-shaped male skull (A) within mesocrany range, cranial index 75.54, slightly bulging occipital, low forehead, bifurcated mastoids, and pitting scars of *cribra orbitalia* in eye orbits from childhood anemia. Damaged male skull (B) missing face and most of right side, with prominent nuchal ridge on back of skull, mild hypoplasia of basioccipital and unilateral left mendosa suture remnant. Adult proximal phalange from thumb shows healed smash injury. Set of arms from a male, with evidence for functional stress from heavy lifting. Female skull (C), small ovoid shape within mesocrany range, cranial index 75.84. Large pitting scars of *cribra orbitalia* in eye orbits; atlas with unilateral left posterior bridge; femora with 3rd trochanters and Allen's fossa. Infant skull (E) shows pitting lesions of *cribra orbitalia* from anemia in eye orbits and internal lesions on left parietal and frontal. Adult sexes determined by two sets of robust bones, one set of gracile bones with wide sciatic notch on pelvis. Male ages based on pubic symphysis, and female age based on incomplete fusion of iliac crest. Infant age based on dental development. Statures estimated on lengths of female tibia (39.4 cm), and two sets of male tibiae (36.7 cm and 36.9 cm).

36 Grave 2001-29 Figs. 85, 87

Christian-style grave, oriented S 47° W, >1.17 × >0.34 × >0.20 m. Two individuals represented.

Figure 87. Christian-style grave 36

This content downloaded from 78.100.65.226 on Fri, 11 Oct 2013 01:17:53 AM
All use subject to JSTOR Terms and Conditions

A. Articulated burial. Child, 8–9 years. Extended on back with head to southwest and propped up ca. 30° toward feet and tilted slightly toward right; legs fully extended with knees separated by 2.5 cm and ankles no closer; arms bent toward pelvis from outwardly flaring elbows so both hands rest on pelvis. Appears tall for dental age with no signs of pathology. Damaged skull. Carabelli's cusps on upper deciduous molars, small ossicle at lambda on skull, and Allen's fossa on femora. Age determined by dental development.

B. Skull of a child, 8–9 years, resting on right side mouth to mouth with skull of burial A. Head snuggled against a rounded cobble fragment (15 × 10 × 9 cm) on left side with B's skull touching mouth on right side—both could have served as head props. Rhomboid-shaped skull. No apparent pathology. Age based on dental development.

37 Grave 2001-30 Fig. 85

Muslim-style grave, oriented S 57° W, >1.19 × 0.54 × 0.46 m.

Male, 30–35 years, stature 174.24 cm (5′7″). Pelvis and legs extended on back with head to southwest; both hands alongside hips with palms to hips. Only right forearm and hands remain from disturbed upper body. Osteochondritis affected distal end of left femur (absent on right side) from trauma and stress on knee joint, and signs of Achilles tendonitis on heels and patellae with stress on knees along with signs of stress on thighs from overuse extending legs with knees and thighs rotated inward. Bony scars of Osgood-Schlatter disorder caused by overuse extending right lower leg (absent on left side) during adolescence. Fifth metacarpal from left hand bowed and thickened with small osteophyte below distal head from forceful overuse during growing years; thumbs and fingers from both hands show heavy pulling actions. Sex determined by very robust bones, large femoral head diameter, and narrow sciatic notch and pubic arch. Age based on pubic symphysis and lack of spinal DJD. Stature estimated from combined lengths of femur (46.9 cm) and tibia (38.1 cm).

38 Grave 2001-31 Figs. 80, 85

Christian-style grave, oriented W, >0.79 × 0.56 × >0.27 m. Head framed between two rough limestone blocks as if it had been returned to its original position after disturbance by grave **48**.

Female, 50+ years, stature 156.84 cm (5′1″). Redeposited secondary burial of bones arranged in an apparent bundle running eastward from skull that stood on left side of face. Narrow, birsoid-shaped skull within mesocrany range, cranial index 75.70, high vertical forehead, slightly angular nose, medium face, and narrow pointed chin with shrinking maxilla and mandible from severe alveolar bone resorption, with the loss of most teeth long before death. Two severe caries in remaining teeth. Large shallow erosive lesion with scalloped border on left side of forehead above and behind left eye most likely postmortem defect, possibly due to rodent gnawing. Signs of functional stress on arms from repetitive lifting of left arm upward and out while flexing and rotating forearm (unknown for right humerus, but radius shows similar stress flexing and rotating right forearm). Bending stress on neck and thoracic spine reflected by erosive lesions on apophyseal facets. Asymmetrical lumbarization of 1st sacral segment with unstable joint affected by arthritis. Sex determined by gracile bones and wide sciatic notch and pubic arch. Age based on dental status, spinal DJD, and pubic symphysis. Stature estimated from combined lengths of femur (40.5 cm) and tibia (33.8 cm).

39 Grave 2001-32 Fig. 85

Christian-style grave, oriented S 75° W, >1.22 × 0.45 m × unknown depth.

Female, 30–40 years, stature 157.59 cm (5′2″). Skull, upper chest, and feet missing; most of preserved bones damaged. Extended on back with head area to

This content downloaded from 78.100.65.226 on Fri, 11 Oct 2013 01:17:53 AM
All use subject to JSTOR Terms and Conditions

west; legs fully extended with knees separated by 10 cm; arms folded across abdomen at right angles to spine with right hand over spine and closer to head area than left hand that overlies right forearm.

Signs of functional stress on arms from forceful flexing of right elbow while rotating hand back and forth with thumb and wrist rotated outward while only bone from left arm shows forceful flexion of forearm with palm upward. Both femora show stress from extending flexed thighs in line with trunk, as with repetitive rising from stooped position. Sex determined by gracile bones, small femoral head diameter, and wide sciatic notch. Age based on rib ends and lack of spinal DJD. Stature estimated from length of femur (41.9 cm).

40 Grave 2001-33 Fig. 33

Grave of unassigned style, with no outline discernible.

Female, 25–35 years. Isolated skull and mandible plus parts of an additional skull and one finger bone. Ovoid-shaped skull within mesocrany (medium) range, index 79.07, vertical forehead, fairly straight narrow nose, narrow upper face, small narrow chin. Lower central incisors lost before death, slight periodontal disease around lower 1st molars, calculus on all teeth, upper and lower left 3rd molars not developed, right lower 3rd molar impacted, tiny protostylid pits on lower 1st and 2nd molars. Developmental variants include small palatine torus and failure of lower right side of coronal suture to develop (unknown for left side). Sex determined by gracile markings on skull, and age based on dental wear and endocranial suture closure.

41 Grave 2001-34 Figs. 85, 88

Christian-style grave, oriented S 72° W, ca. 1.77 × 0.62 × >0.23 m. Three individuals represented. A's head framed by two stones well apart from the skull.

A. Articulated burial. Child, 5.5–6.5 years. Extended on back with head to WSW and propped up ca. 30° to face feet (east) and tilted to right ca. 15° with

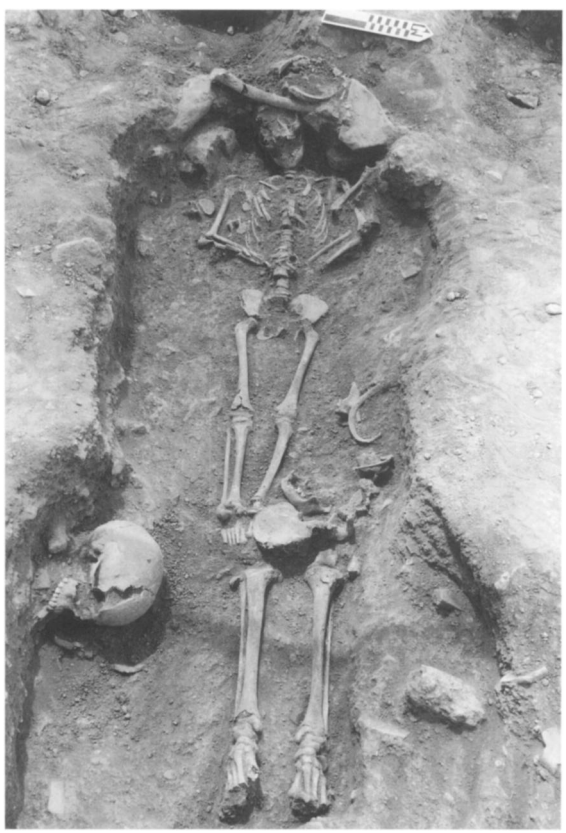

Figure 88. Christian-style grave 41, burial A, with legs from burial B

This content downloaded from 78.100.65.226 on Fri, 11 Oct 2013 01:17:53 AM
All use subject to JSTOR Terms and Conditions

mouth agape and chin resting on spine; legs fully extended with knees separated by 4 cm and ankles touching; arms folded over abdomen from flaring elbows with both hands over 2nd lumbar. Damaged skull. No obvious signs of pathology. Developmental variants include two interparietal bones back of skull, small Carabelli's cusp on upper deciduous 2nd molar, tip of dens for axis vertebra divided into two ossicles, transitional facets moved up from 12th to 11th thoracic vertebra, unilateral right incomplete bridging of atlas, and Allen's fossa on both femoral necks. Age based on dental development and diaphyseal lengths of long bones.

B. Remnant burial. Preadolescent male, 12–13 years. Both lower legs and feet, left femur and innominate, with part of ribs and spine in original position, extended on back with head area to WSW; legs fully extended with knees separated by 4 cm and ankles by 6 cm. Iron knife fragment found inside left upper femur.

Missing most of skull and upper body. Canine tooth with linear enamel hypoplasia reflects metabolic stress during infancy around 34 months. Left clavicle shows functional stress for costoclavicular ligament from heavy lifting or from pulling (unknown for right side). Developmental variants include transitional facets moving up from 12th to 11th thoracic vertebra and cleft 1st sacral segment associated with hypoplasia of left side. Age determined by dental development and epiphyseal fusions. Sex based on narrow sciatic notch and large teeth.

C. Adult skull belonging to grave **67**.

42 Grave 2001-35 west Figs. 44, 78, 79, 89

Christian-style grave, oriented S 86° W, 1.75 × 0.66 × >0.25 m. Five individuals represented in grave plus bones from two individuals in grave **43**. Coin (2001-208) of the Corinthian *duoviri* (2–1 B.C.) found in fill.

A. Articulated burial. Male, 35–40 years, stature 167.71 cm (5′5″). Extended on back with head to west and propped up to face feet (east) with mouth closed and chin resting on cervical vertebrae; head framed by skulls of burials B and C to prevent it from lolling to left side; legs fully extended and turned to left ca. 20° from body with knees separated by 3 cm and ankles by 5 cm; arms with slightly flaring elbows folded across abdomen, left arm closer to face than right, left hand on right side of spine, right hand left of spine, about midway up left forearm.

Top of ovoid skull missing, pronounced nuchal ridge, medium face, narrow straight nose, and broad chin. Agenesis of upper right 3rd molar, large protostylid pits on lower 3rd molars, upper left 1st molar leaning outward, and mild shoveling of chipped upper front teeth. Some fine pitting scars of *cribra orbitalia* in eye orbits from childhood anemia, and old healed injury to lunate of right wrist. Developmental variants include asymmetrical nasal bones, small palatine torus, hamulus hypoplasia of both hamates on wrists (Fig. 44), moderate asymmetrical torsion of the femoral necks with slight Allen's fossa. Evidence of functional stress on right clavicle and on arms from lifting with arms rotated outward, right arm also rotated backward, with elbows forcefully flexed while grasping and clenching hands. Right leg shows signs of repetitive rotation inward with foot extended more than left. Cupric stains on left side of mandible and on 4th metatarsal of right foot. Sex determined by robust bones, large teeth, large femoral head diameter, and narrow sciatic notch and pubic arch. Age based on rib ends and lack of DJD. Stature estimated from combined lengths of femur (44.3 cm) and tibia (35.2 cm). Two iron boot cleats found between legs.

B. Disarticulated skull on left side of burial A's head. Male, 40+ years, plus many other disarticulated bones from pile in grave. Robust skull, spheroid shape, within hyperbrachycrany (very broad) range, cranial index 86.34, with some fine pitting on brow ridges, small amount of pitting scars of *cribra orbitalia* in eye orbits along with fine pitting scars on occipital from childhood anemia. Unilateral left mendosa suture remnant at back of skull, and multiple frontal inner lesions reflect meningitis.

This content downloaded from 78.100.65.226 on Fri, 11 Oct 2013 01:17:53 AM
All use subject to JSTOR Terms and Conditions

C. Disarticulated damaged skull on right side of burial A's head. Female, 50+ years. Gracile skull nearly ellipsoid in shape with bulging occipital, metopism, bilateral parietal thinning, and high vertical forehead.

D. Disarticulated skull from left side of burial A's pelvis. Male, 40+ years, plus disarticulated bones from pile in grave. Robust skull ovoid-round in shape, within hyperbrachycrany (very broad) range, cranial index 87.15, low sloping forehead, slightly curved nose, some fine pitting on brow ridges, some fine pitting scars of *cribra orbitalia* in eye orbits, and pitting scars on occipital from childhood anemia.

E. Face of an adult of indeterminate gender facing upward inside and on top of burial A's left humerus.

Commingled postcranial bones, most of which could not be specifically assigned to any one individual. One pair of male femora with stature of 173.64 cm (5′7″) exhibit DJD of the knees, and matching tibiae show tibiotalar wear facets from habitual squatting. Old smash injury on humerus head of male left shoulder. Hyperextension facet on proximal phalange of robust right thumb. Developmental variants include unilateral left os trigonum from matching pair of tali. Large type II sternum with fused xyphoid, large septal aperture on gracile left humerus, male sacrum with sacralized caudal of coccyx. Adult sexes determined by robust and gracile bones, narrow and wide sciatic notches, large and small femoral head diameters. Ages based on endocranial suture closures and spinal DJD. B's stature estimated on combined lengths of femur (46.7 cm) and tibia (37.8 cm).

43 Grave 2001-35 east Figs. 39, 78, 89, 98

Christian-style grave, oriented S 74° W. Two graves intersect one another, the later grave **42** having cut away ca. 60% of the earlier grave **43**. Original grave dimensions are 1.90 × 0.65 × >0.20 m. Two individuals represented. Coin (2001-206) of Valentinian II (A.D. 375–392) found near skull (Fig. 98:7).

F. Remnant burial. Male, 40+ years, stature 173.16 cm (5′7″). Articulated lower legs and feet and right humerus of adult male lying on backsides with head area toward WSW; skull and many other elements found among disarticulated bones in grave **42**. Tibiotalar wear facets from habitual squatting. Vastus fossa on both patellae. Sex determined by robust bones; stature estimated from tibia length (37.7 cm).

G. Disarticulated burial. Preadolescent, 11–12 years. Jumble of bones clustered over legs and feet of burial F; many elements cross-matched with others in grave **42**. Skull exhibits boat-shaped scaphocephaly (Fig. 39) from agenesis (lack of development) of sagittal suture, small amount of pitting scars of *cribra orbitalia* in eye orbits from past anemia, Carabelli's cusp on upper permanent 1st molars, and tiny protostylid pit on lower permanent 2nd molar; slight Allen's fossa on right femur. Age based on dental development.

44 Grave 2001-36 Figs. 18, 30, 56, 89

Christian-style grave, oriented N 84° W, 1.80 × 0.57 × >0.30 m.

Female, 60+ years, stature 157.52 cm (5′2″). Extended on back with head to west and propped up ca. 50° and turned right ca. 75° to face over right shoulder; legs fully extended with knees separated by 6 cm and ankles by 4 cm, with feet pressed upright at end of grave; arms folded across abdomen from outwardly flaring elbows at 90° and 85° angles to spine with hands together over lumbar vertebrae. Bronze ring (MF-2001-37) along with cupric stain on 4th finger of right hand (Fig. 30).

Damaged skull and rib cage. Most teeth lost long before death with severe alveolar bone resorption. Large caries in remaining left premolars and one chipped tooth. All bones light weight from osteoporosis. Scars of severe crescent-shaped

This content downloaded from 78.100.65.226 on Fri, 11 Oct 2013 01:17:53 AM
All use subject to JSTOR Terms and Conditions

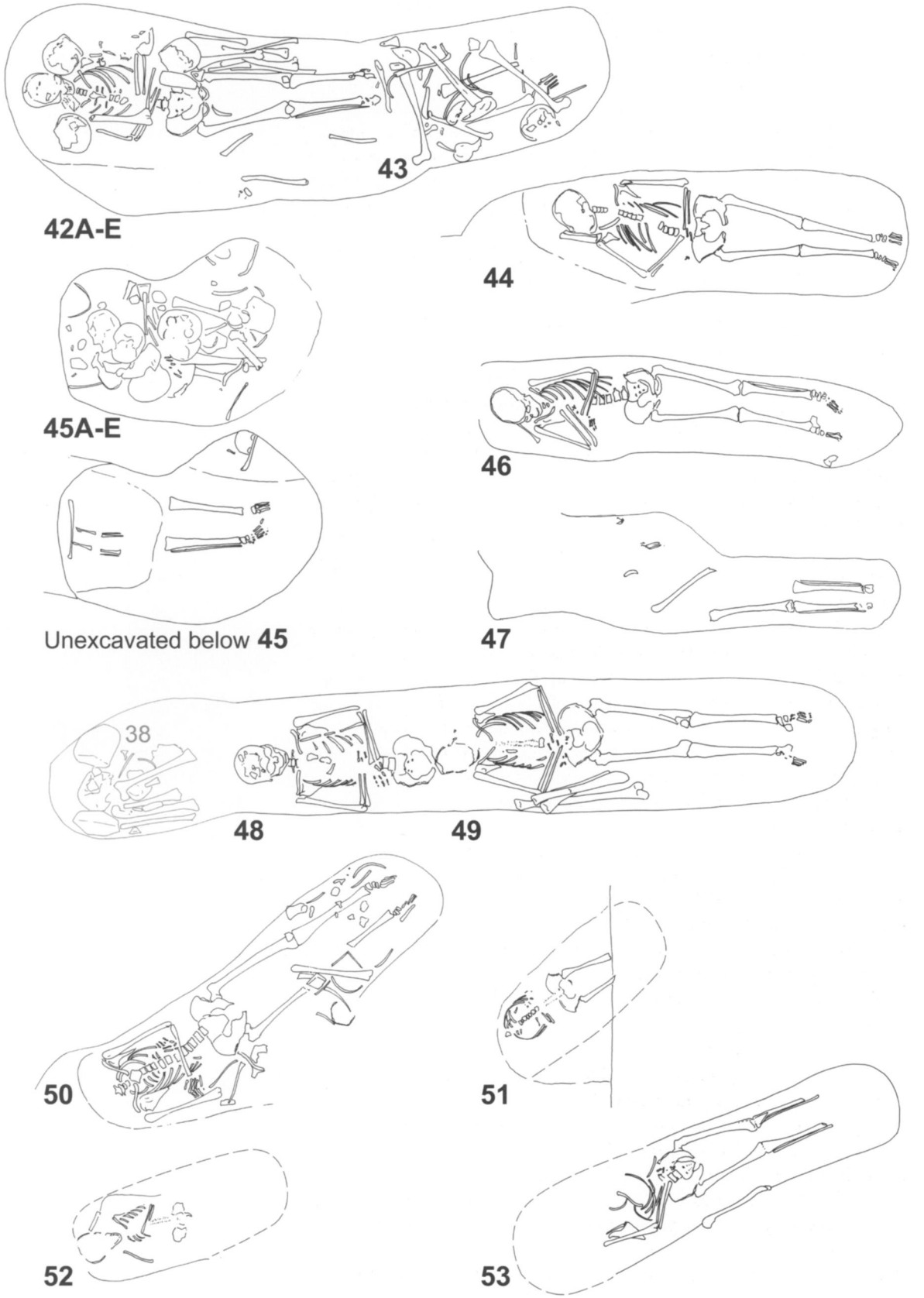

Figure 89. Graves 42–53

This content downloaded from 78.100.65.226 on Fri, 11 Oct 2013 01:17:53 AM
All use subject to JSTOR Terms and Conditions

head wound that became infected on right side of head above mastoid (Fig. 56). Signs of lifelong functional stress from repetitive rotation of arms in, out, and downward. Left knee shows some arthritis, both thighs stressed from extending them in line with the trunk; individual habitually squatted on her ankles as reflected in tibiotalar wear facets. Fingers of both hands show arthritis. Developmental variants include interparietal ossicle on back of skull, bipartite 1st cuneiform from left foot, and large Allen's fossa on left femur (unknown for right side). Sex determined by very gracile bones and wide sciatic notch. Age based on thin bones, spinal DJD, and dental status. Stature estimated from length of tibia (33.1 cm).

45 Grave 2001-37 Figs. 19, 89

Christian-style grave, trending E–W, >1.04 × 0.70 × 0.20 m. Five individuals represented.

A jumble of bones with four skulls on top of long bones, pelves, ribs, vertebrae, and other bones stacked above the feet and lower legs of an adult whose burial extended westward under the excavation area limit and could not be excavated. This unexcavated articulated burial extended on its back with head area to west and feet to east.

Commingled skeletal remains included an adolescent male (A), 15–16 years; a second adolescent male (B), 17–18 years; an adult male (C), 40–45 years, stature 168.08 cm (5′5″); an infant (D), 18–30 months; and a child (E), yielding only fragments of ulna, lumbar vertebra, and foot bones.

Younger adolescent A's skull nearly spheroid in shape within hyperbrachycrany (very broad) range, cranial index 85.14, slightly protruding occipital, wide mandible with medium chin. Fine pitting lesions around ear openings from ear infections, and left ear infection severe, causing large lytic lesion. Some calculus on front teeth, lower canines with double roots, and protostylid pits on lower molars.

Older adolescent B's skull ovoid in shape within mesocrany (medium) range, cranial index 75.28, medium chin, unilateral left lower coronal suture absent, and cupric spots on left side of skull. Tiny protostylid pits on lower molars, and enamel hypoplasia band on canine from metabolic disturbance in infancy around 34 months.

C's skull nearly spheroid in shape within mesocrany (medium) range, cranial index 77.59, metopism, pronounced nuchal ridge on occipital, absence of frontosphenoid suture on both sides, and small double precondylar tubercle at base.

Toddler D's skull ovoid–round with lambdoid ossicles, fine pitting scars of *cribra orbitalia* in eye orbits, and similar lesions on parietals from back of skull.

Individual A shows Allen's fossa on femora. Signs of functional stress on arms of B and C from pulling inward with arms in fixed position, more pronounced on right side. C's arms also show stress on rotator cuffs and repetitive flexion of forearms at right angle, greater on left side, as well as tibiotalar wear facets from habitual squatting and loading stress on his back. Sex determined by robust bones and narrow sciatic notches and pubic arches. Adult C's age based on spinal DJD and endocranial suture closure. Adolescent ages based on dental development and epiphyseal closures. Infant age based on long bone diaphyseal lengths. Adult stature estimated on combined lengths of femur (44.1 cm) and tibia (35.7 cm).

46 Grave 2001-38 Fig. 30, 89

Christian-style grave, oriented N 86° W, 1.61 × 0.58 × 0.50 m.

Female, 35–39 years, stature 157.13 cm (5′2″). Extended on back with head to west and propped up ca. 60° and turned ca. 30° to right to look over right shoulder and mouth closed with chin resting on spine; legs fully extended with knees separated by 5 cm and ankles by 19 cm, with feet extended beyond ankles parallel to tibiae and resting on their outer sides; upper arms flare outward from shoulders to elbows, with right forearm bent directly toward left shoulder placing

This content downloaded from 78.100.65.226 on Fri, 11 Oct 2013 01:17:53 AM
All use subject to JSTOR Terms and Conditions

right hand in front of face and left forearm folded across abdomen at T11–T12 at ca. 80° to spine with left hand at bottom of right rib cage.

Plain bronze ring (MF-2001-36) found among finger bones of right hand (Fig. 30); green cupric stain on 4th proximal phalange indicates its former location. Turkish *akche* (2001-210) found on right scapula although green cupric stain on exterior of mandible at lower left lateral incisor shows original placement. Fragment of bronze wire found at south edge of grave south of pelvis, six iron nails with square shanks in fill.

Damaged skull. Evidence of periodontal disease, two abscesses associated with lower right lateral incisor that was lost before death, and 1st molar about to be lost at time of death. Lower 2nd molar also lost before death. Upper 3rd molars failed to develop. No signs of pathology. Signs of functional stress from repetitive flexing of forearms with palms partially turned down. Large osteophyte projecting from upper end soleus attachment on fibula of left lower leg from overuse injury when muscle was stretched with foot rotated and extended downward. Developmental variants include type II sternum, nearly bifid mandibular condyle with large pit in center, unilateral right incomplete posterior bridge on atlas, large septal apertures on humeri, and unilateral left large os calcaneus secondaris (separate bone) on calcaneus. Sex determined by gracile bones and wide sciatic notch and pubic arch. Age based on lack of spinal DJD, dental wear, and pubic symphysis. Stature estimated from combined lengths of femur (41.2 cm) and tibia (33.4 cm).

47 Grave 2001-39 Figs. 20, 89

Grave of unassigned style, oriented W, ca. 0.37 m wide.

Female, adult, stature 151.72 cm (4′10″). Lower legs and right femur extended on backsides with feet pointed toward east (head area to west) with knees separated by 4 cm and ankles by 5 cm and feet pointed upward. Disarticulated left femur lay to west. Mature lower limbs represent a small woman. Sex determined by very small gracile bones and very small femoral head diameter. Stature estimated on tibia length (31.1 cm).

48 Grave 2001-40A Figs. 80, 89

Christian-style grave, oriented N 89° W, representing an extension of grave **38** to roughly 2.70 × ca. 0.73 × probably 0.54 m.

Male, 39–44 years, stature 167.73 cm (5′5″). Extended on back with head to west and propped up ca. 30° to face directly toward feet (east) with mouth slightly ajar and chin resting on vertebrae; legs removed by later grave **49**; arms folded across abdomen at nearly right angles to spine, with both hands resting on opposite sides of the spine from their respective elbows, right hand closer to head than left.

Damaged skull is asymmetrical pentagonoid in shape with bulging occipital and asymmetrical squarish chin. Lower right molars affected by periodontal disease, calculus on front teeth. Canine with enamel hypoplasia bands representing five episodes of metabolic disturbances during infancy between 12 and 34 months. Unusually small teeth for male with spaces between lower canines and 1st premolars, and upper right 3rd molar represented by micro-tooth with "mulberry" crown, projecting above occlusal level. Both lower 3rd molars failed to develop. All bones light in weight, indicative of osteoporosis most likely from prolonged illness that kept individual inactive. Signs of functional stress from frequent use of arms with heavy loading stress on lower spine. Developmental variants include unusually small proximal ends of ulnae, movement of transitional facets up from 12th to 11th thoracic vertebra, left complete and right incomplete posterior bridging on atlas, 5th lumbar cleft neural arch caused by hypoplasia of left side, cleft 1st sacral segment with high hiatus and flat neural crest. Sex determined by robust bones and narrow sciatic notch and pubic arch. Age based on dental wear and pubic symphysis. Stature estimated from combined lengths of femur (43.9 cm) and tibia (35.6 cm).

This content downloaded from 78.100.65.226 on Fri, 11 Oct 2013 01:17:53 AM
All use subject to JSTOR Terms and Conditions

49 Grave 2001-40B Figs. 80, 89

Christian-style grave, oriented S 83° W. Extension of graves **38** and **48** to 3.67 × 0.73 × 0.54 m. Amphora lid with Λ in raised relief from fill.

Male, 50+ years, stature 172.39 cm (5′7″). Extended on back with head to west lying on its occiput face up, with mouth apparently virtually closed without a chin prop; legs fully extended with knees separated by 7 cm and ankles by 10 cm, with feet extended upward to the outside; arms folded across abdomen at ca. 75° to spine from outward flaring elbows with hands together above lumbar vertebrae. Bones of two legs (2 femora, 2 tibiae, 2 fibulae) from grave **48** lay lengthwise along right side from just above right elbow to middle of right femur.

Damaged skull appears ovoid–round in shape. Evidence of severe periodontal disease, lower lateral incisor reduced to root stub, and protostylid pits on lower molars. Severe DJD of spine from lifelong heavy lifting and bending. Left upper arm shorter than right by 0.8 cm, while left arm more robust than right with arthritis of shoulder joint from overuse. Both arms show signs of functional stress from repetitive pulling that stressed both elbow joints. Destruction of left elbow joint (unknown for right side) from repetitive extreme flexion with forearms partially rotated. Large osteophyte projecting from common flexor muscle attachment on distal left humerus from overuse injury while flexing wrist inward. Right wrist also stressed with breakdown of carpal joints on both sides of wrist. Stress shows on both thighs, greater on left side. Developmental variants include bilateral os acromion, complete sacral cleft containing bony island, sacralized 1st caudal of coccyx, and unilateral left 5th toe symphalangism. Sex determined by robust bones, large femoral head diameter, and narrow sciatic notch and pubic arch. Age based on endocranial suture closure and severe spinal DJD. Stature estimated from combined lengths of femur (45.1 cm) and tibia (38.3 cm).

50 Grave 2001-41 Figs. 27, 67, 89, 90

Christian-style grave, oriented S 54° W, 1.75 × 0.56 × 0.40 m.

Male, 40–50 years, stature 177.28 cm (5′8″). Extended on back with head (skull and upper cervicals found among disarticulated bones in overlying grave **35**) to WSW, once propped up nearly vertically to face feet (east); legs fully extended with knees separated by 12 cm and ankles by 9 cm, with feet curled inward from outer sides; left upper arm parallels spine with forearm folded across abdomen at T12 at right angle to spine, with left hand over outer right rib cage; right upper arm flares away from torso from shoulder to elbow but forearm is disturbed, right hand found above left rib cage next to spine. Ornamental bronze rings with flanking floral decoration (MF-2001-34, MF-2001-35) found against left tibia 11 cm below left knee, and attached to back of right fibula 3 cm below its head (Fig. 27).

Skull, upper cervicals, sacrum, and lower arms found in grave **35**. Skull ovoid in shape. Severe periodontal disease. Large chip on upper left canine, upper left 1st molar above occlusal level with space between it and 2nd molar, small caries on lower right 2nd molar with tiny protostylid pit. Small lower right 3rd molar not completely erupted. Cupric stain on upper end of fibula from lower right leg.

Pathology includes apparent gallstones (Fig. 67), two reddish-brown globular hard substances, 1.0 × 1.2 cm in size and joined together, from the lower thoracic region. Healed fractures of lower right and left ribs. Lower end of tibia from right leg swollen with osteitis, and goutlike lesion on head of 1st metatarsal leading to big toe. Signs of functional stress on both shoulders and upper arms from repetitive overuse raising and pulling upward and out with elbows forcefully extended, and fingers of both hands used with forceful gripping. Tendonitis reflected on both patellae of knees and on heels from straining extended knees with lower legs slightly rotated and feet extended and rotated. Developmental variants include mandibular mylohyoid bridge, bilateral incomplete transverse foramen of the axis vertebra,

This content downloaded from 78.100.65.226 on Fri, 11 Oct 2013 01:17:53 AM
All use subject to JSTOR Terms and Conditions

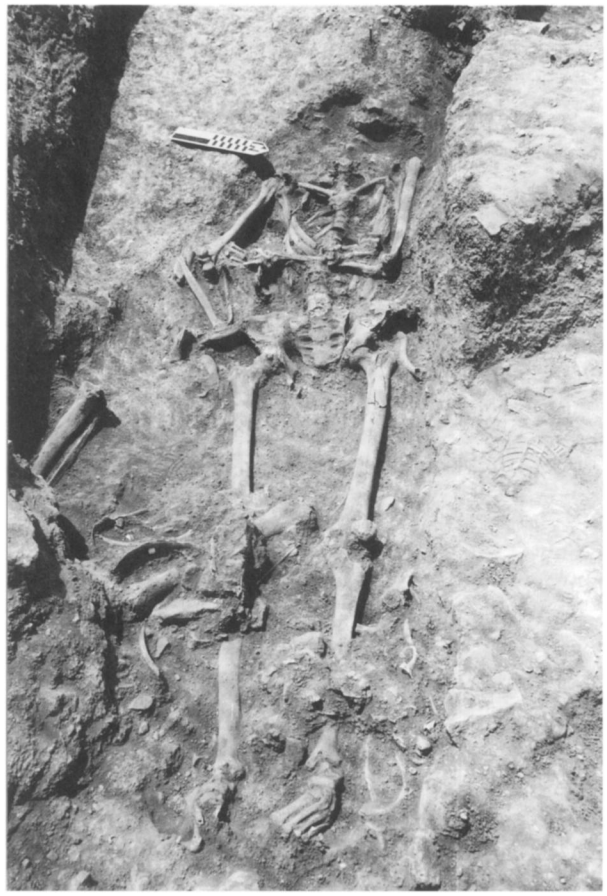

Figure 90. Christian-style grave 50

unilateral left os metastyloideum (separate ossicle for styloid of 3rd metacarpal) with ossicle fused to capitate, and bilateral suprascapular foramina. Sex determined by robust bones, large femoral head diameter, and narrow sciatic notch and pubic arch. Age based on dental wear, rib ends, endocranial suture closure, and spinal DJD. Stature estimated from length of tibia (39.4 cm).

51 Grave 2001-42 Fig. 89

Christian-style grave, oriented S 54° W, dimensions unobtainable.

Child, 3.5–5.5 years. Extended on back with head area to southwest; upper legs extended with knees separated by ca. 4 cm, lower legs missing; right forearm bent over abdomen ca. 65° to spine with right hand over spine, suggesting that elbow had flared outward from torso. Small number of bones preserved. Age estimated from fusion of neural arches on vertebrae and in situ long bone diaphyseal lengths.

52 Grave 2001-43 Figs. 65, 89

Christian-style grave, oriented S 64° W, >0.66 × 0.28+ × >0.15 m.

Infant, 30–36 months. Extended on back with head to WSW; legs and feet missing; elbows flare outward from torso with forearms bent across abdomen and hands over spine. Bones damaged. Severe pitting lesions and thickening of parietals (porotic hyperostosis) near lambdoid suture on both sides of skull with some lesions on upper occipital (Fig. 65). Most likely from severe anemia associated with malaria. Enlarged foramina on middle finger phalanges also indicative of severe anemia. Pitting lesions around mental foramina on both sides of mandible, caused by infection. Bilateral mendosa suture remnant on back of skull. Age determined by dental development and diaphyseal length of radius.

This content downloaded from 78.100.65.226 on Fri, 11 Oct 2013 01:17:53 AM
All use subject to JSTOR Terms and Conditions

53 Grave 2001-44 Fig. 89

Christian-style grave, oriented S 64° W, ca. 1.56 × ca. 0.46 m × unknown depth.

Female, 17–18 years, stature 155.27 cm (5′1″). Extended on back with head area to WSW. Skull, most of upper body, and feet missing. Legs fully extended with knees separated by 6 cm and ankles by 8 cm; right upper arm lies alongside rib cage with forearm bent toward pelvis and hand over lower lumbars, some left metacarpals found at top of left ilium. No signs of pathology, and only developmental variant is hypoplasia of the hamulus of the hamate from the right wrist (unknown for left side). Sex determined by very small gracile bones, small femoral head diameter, and wide sciatic notch. Age based on epiphyseal fusion. Stature estimated by combined lengths of radius (21.1 cm) and ulna (22.8 cm).

54 Grave 2001-45 Figs. 16, 32, 47, 57, 61, 68, 70, 91, 98

Christian-style grave, oriented S 69° W, 2.07 × 0.46 × 0.62–0.67 m. Four individuals represented. Disarticulated bones (B–D) stacked mostly over articulated burial A's lower legs and feet, with some above the stone that covers the head.

A. Articulated burial. Preadolescent, 12–13 years. Extended on back with head to WSW and propped up almost vertically to face toward feet (east), mouth agape with chin resting on vertebrae; although middle of skeleton has been destroyed, legs had been extended with ankles separated by 7 cm and feet extended outward; left humerus flares outward from torso at 45° with rest of arms missing. Head placed in niche formed by two rough limestone blocks flanking the head and spaced 17.5 cm apart with a third block (32 × 14 × 13 cm) resting on top of them and covering the head.

Right arm, hands, torso, hips, and thighs missing. Dark stain on left 2nd rib. Intact ellipsoid-shaped skull with medium square chin, ossicle at lambda on back of skull, and enlarged incisive canal on palate. Discolored greenish brown upper left 2nd premolar, small protostylid pits on lower 1st molars, and chipped front teeth. Enamel hypoplasia bands on canine reflect metabolic disturbances around 24 and 34 months during infancy. Severe active lesions of *cribra orbitalia* in eye orbits (Fig. 61) from anemia. Developmental unilateral left symphalangism of 5th toe. Age based on dental development and epiphyseal fusions.

Most of the objects associated with burial A probably made up a single necklace (Fig. 32). Perforated Nuremberg jeton (2001-211) of W. Lauffer II (A.D. 1612–1651) above right clavicle (Fig. 98:36A). Fluted globular faience or glass paste melon bead with bronze caps (MF-2001-27), three worked cowrie shells (MF-2001-28A–C), and 186 round glass beads (MF-2001-27), 0.5 cm in diameter, in white, yellow, black, and blue, found around the neck. In addition, a plain iron ring (MF-2001-43), mended from three fragments, was found.

B–D. Commingled skeletal remains of two men and an older woman: a male (B), 25–35 years, stature 169.70 cm (5′6″); a second male (C), 21–24 years, stature 167.61 cm (5′5″); and a female (D), 40+ years, stature 164.76 cm (5′4″). B's skull is ellipsoid in shape within brachycrany (broad) range, cranial index 83.15, low forehead, fairly straight nose, medium face, and mild palatine torus. No apparent dental pathology on upper teeth. Atlas vertebra matching this skull displays cleft posterior arch (Fig. 47). Mandible of C shows square chin with dimple, and large cupric stain on right side. Lower 3rd molars failed to develop. D's mandible exhibits small chin and tooth loss before death, accompanied by severe alveolar bone resorption.

Pathologies include several right and left ribs from same individual showing severe chronic pleural infection of lungs with buildup of fine periosteal plaque (Fig. 70) that most likely caused death. Individual D's left upper arm exhibited a healed compound fracture with deformation and osteomyelitis (Fig. 57). Tibia from right leg also shows healed overriding mid-shaft compound fracture with

This content downloaded from 78.100.65.226 on Fri, 11 Oct 2013 01:17:53 AM
All use subject to JSTOR Terms and Conditions

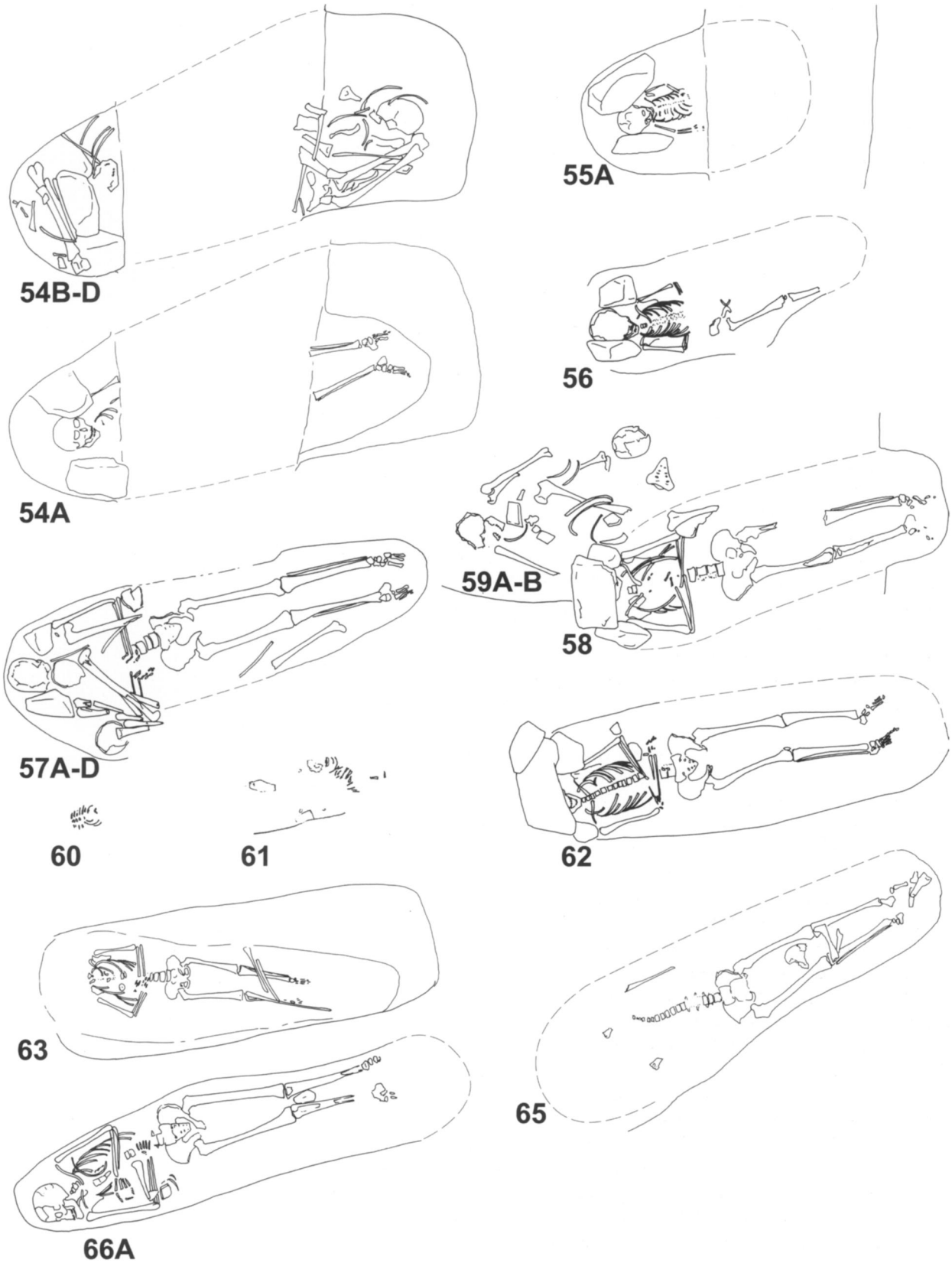

Figure 91. Graves 54–63, 65, 66

This content downloaded from 78.100.65.226 on Fri, 11 Oct 2013 01:17:53 AM
All use subject to JSTOR Terms and Conditions

osteomyelitis. Pair of adult male legs display periosteal irritations. Acromion end of scapula from a right shoulder has old crush injury. Evidence of chronic brucellosis reflected in lesion on robust male 11th thoracic vertebra (Fig. 68). Younger man's forearms show signs of irritation with fine periosteal plaque formation. Signs of functional stress on woman's hands reflected by severe arthritis at base of thumbs and finger joints. She also shows stress on both thighs while knees were extended. Younger man shows stress for right costoclavicular ligament, and left upper arm from matching pair of male arms shows stress rotation inward, down, and back. Ulna from older man's left forearm shows stressful rotation of wrist with palm of hand down. One man's right femur displays stressful extension with inward rotation of the knee, and Poirier's wear facet from habitually sitting on ground with hip extended and knee flexed.

Sexes determined by gracile and robust bones, narrow and wide sciatic notches. Ages based on female dental status and degenerative arthritis, lack of fusion of sternal ends of clavicles, dental wear for younger male, and dental wear and endocranial suture closure for older male. Statures estimated on femur lengths: female 44.8 cm; males 44.9 cm and 44.0 cm.

55 Grave 2001-46 Figs. 91, 92

Christian-style grave, oriented WSW, >0.49 × 0.41 (bottom)–0.73 (top) × 0.33 m. Two individuals represented. Head of individual A framed snugly by two limestone blocks (26 × 16 × 16 cm, 23 × 14 × 6 cm).

A. Truncated articulated burial. Infant, 12–14 months. Torso extended on back with head to WSW and propped slightly to face direction of feet, mouth open and head tilted slightly to right; left arm bent to place left hand over spine while right arm extends beside torso and 7 cm away from it. Lower portion of body missing. Signs of infection that left fine fibrous new bone covering mastoids and extending over base of occipital and posterior portions of temporals, most likely causing death. Age based on anterior fontanelle, dental development, and long bone diaphyseal lengths.

B. Single bone only. Infant, 1–3 months. Left femur only from wall trench that cut off lower half of this grave.

56 Grave 2001-47 Figs. 48, 91

Christian-style grave, oriented S 78° W, >1.06 × 0.40 × >0.21 m. Head framed snugly between two limestone blocks (16 × 14 × 9 cm, 21 × 11 × 8 cm).

Child, 9–10 years. Damaged skull and missing left hip and leg, and both feet. Extended on back with head to WSW and propped up ca. 60° to face feet (ENE), mouth partially agape and chin resting on spine; right leg fully extended but left leg has been cut away by unexcavated grave adjacent to the north; elbows flare outward from torso with both forearms folded over abdomen at right angles to spine.

Chronic anemia expressed as fine pitting lesions with diploe expansion (porotic hyperostosis) of both parietals (eye orbits and frontal missing). Distal two-thirds of right femur shaft greatly expanded and filled with trabecular bone (left femur missing), cause unknown. Developmental variants include unilateral left transitional facet moved up from 12th to 11th thoracic vertebra, bifurcated posterior arch of atlas vertebra (Fig. 48), and small Allen's fossa on right femur. Age based on dental development and long bone diaphyseal lengths.

57 Grave 2001-48 Figs. 27, 43, 91, 93

Christian-style grave, oriented S 73° W, 1.76 × 0.39 (across torso)–0.15 (across feet) × >0.12 m. Four individuals represented. Two rough limestone blocks (19 × 19 × 11.5 cm, 11 × 10.5 × 13 cm) frame individual A's head.

A. Articulated burial. Male, 45–55 years, stature 176.79 cm (5′8″). Extended on back with head to WSW and propped up ca. 75° and turned ca. 10° toward

This content downloaded from 78.100.65.226 on Fri, 11 Oct 2013 01:17:53 AM
All use subject to JSTOR Terms and Conditions



Figure 92 ***(left)*****. Christian-style grave 55**

Figure 93 ***(right)*****. Christian-style grave 57**

right (south); legs fully extended with knees separated by 4 cm and ankles by 7 cm; arms folded across abdomen at right angles to spine at L1 from outward flaring elbows with hands together at right side of spine, right hand on top. Iron belt buckle (MF-2001-32) found upright along right side of thoraco-lumbar vertebrae (Fig. 27).

Damaged ovoid-shaped skull within brachycrany (broad) range, cranial index 81.87, bulging occipital, medium forehead, fine pitting on brow ridges and glabella, wide mandible with broad square chin. Large bony buildup at right gonial angle of lower jaw, absent on left side. Cupric stain on teeth from right side of mouth and on hyoid bone. Signs of periodontal disease around molars, large chipping on some teeth, severe caries on upper and lower 3rd molars. Lower left 2nd and 3rd molars lost before death.

Pathology includes fine pitting around ear openings and upper occipital from back of skull. Raised linear lesions on inner aspect of rib fragments from lung infection. Old healed rib fracture from left side and healed fracture of right transverse process of 3rd lumbar from lower spine. "Gutter" lesion for attachment of muscle that extends toes on left calcaneus. Signs of functional stress on both shoulders and upper arms, including arthritis of os acromion (Fig. 43) on left scapula (unknown for right side) from rotating arms out, back, and inward with right elbow flexed at right angle and hand clenched. Hamates from both wrists show osteophytes on hamulus from excessive rotation of wrists, and both thumbs show arthritis and hyperextension facets along with some arthritic fingers. Both knees show some arthritis and thighs were stressed from heavy use. Poirier's wear facet on right femur (unknown for left side), and bilateral tibiotalar wear facets from habitual squatting. DJD in neck from heavy loading and bending stress. Developmental variants include wide type I sternum, unilateral right tympanic

This content downloaded from 78.100.65.226 on Fri, 11 Oct 2013 01:17:53 AM
All use subject to JSTOR Terms and Conditions

aperture, unilateral left mylohyoid bridge, unilateral left transitional facet moved up from 12th to 11th thoracic vertebra, and Allen's fossa on femur. Sex determined by robust bones, large femoral head diameter, and large ossified thyroid cartilage. Age based on dental wear, rib ends, spinal DJD, and endocranial suture closure. Stature estimated on length of tibia (39.2 cm).

B–D. Disarticulated burials. Pile of disarticulated bones lay primarily over the upper torso and along the right side to the pelvis of burial A; one leg bone beside right knee parallel to right leg, one skull part directly in front of A's face, a frontal sits just below left elbow, most long bones along right side of torso, another skull part rests at extreme south side of grave south of A's right arm.

The commingled skeletal remains of two men and a child are present: B is a male, 40+ years, stature 175.5 cm (5′8″); C is a male, 35–45 years, stature 171.55 cm (5′6″); and D is a child, 7.5–8.5 years. B's skull is ovoid in shape with slightly bulging occipital with pronounced nuchal ridge, narrow pointed chin, and small pitting scars of *cribra orbitalia* in eye orbits from childhood anemia. C's skull is missing; only the mandible with a broad chin survives. Both men suffered periodontal disease and the older man (B) had caries. D's skull is similar in shape to B's skull, but with metopism, and some pitting scars of *cribra orbitalia.* Adult sexes determined by robust bones and large femoral head diameters. Adult ages are based on dental wear and endocranial suture closure, while child's age based on dental development and diaphyseal length of tibia. Statures estimated on lengths of femora (47.4 and 45.7 cm).

58 Grave 2001-49 Figs. 34, 91

Christian-style grave, oriented S 76° W, 1.72 × 0.52 × 0.48 m. Niche formed by rough limestone blocks (25 × 15 × 11 cm and 16 × 11 × 7 cm) flanking the head, with a third horizontal limestone block (32 × 20 × 12 cm) spanning the space above the head.

Male, 40–50 years, stature 166.63 cm (5′5″). Extended on back with head to WSW and propped up ca. 45° and turned toward left ca. 45° to look over left shoulder with mouth agape and chin on left clavicle; legs fully extended with knees separated by 8 cm and ankles by 7 cm with feet extended on outer edges; arms folded across abdomen at ca. 80° to spine from flaring elbows with right hand resting atop left directly over T11–T12. Turkish coin (2001-209) found on maxilla.

Spheroid-shaped skull within hyperbrachycrany (very broad) range (Fig. 34), cranial index 85.33, low forehead, fairly straight nose, wide face, broad chin with flaring gonials, pronounced nuchal ridge on back of skull, and cupric stain below nose and on upper central incisors. Fine pitting lesions on glabella and brow ridges. Calculus covers occlusal surface of remaining upper molars, indicative of long illness. Tiny protostylid pit on remaining lower molar, and bilateral temporomandibular joint dysfunction associated with tooth loss.

Pathology includes fine pitting scars of *cribra orbitalia* in both eye orbits and the upper occipital from past childhood anemia, small healed depression fracture above the right eye, healed fractures on mid-left ribs, and trauma-induced faceted exostoses on two adjacent mid-right ribs. Pitting erosive lesion above occipital protuberance from functional stress on trapezius muscle, with prolonged suspension of arms with shoulders fixed and neck extended. Shoulders and upper arms reflect heavy pulling with arms rotated inward, down, and back, elbows flexed at right angles with grasping hands. Bilateral tibiotalar wear facets from habitual squatting. Developmental variants include small precondylar depression at base of skull, fused hyoid, ossified laryngeal cartilage, bilateral lumbar ribs, and large tubercle on both naviculars from feet. Sex determined by very robust bones and large femoral head diameter. Age based on dental wear, rib ends, and moderate spinal DJD. Stature estimated on length of tibia (35 cm).

This content downloaded from 78.100.65.226 on Fri, 11 Oct 2013 01:17:53 AM
All use subject to JSTOR Terms and Conditions

59 Grave 2001-50 Fig. 91

Christian-style grave, oriented WSW, dimensions unobtainable. Two individuals represented.

A. Disrupted burial. Female, 18–19 years, stature 171.18 cm (5′6″). Head in west end lying on right side facing ESE over right shoulder but tilted upward ca. 15°; both humeri flare markedly outward from shoulders to elbows with forearms missing.

Ovoid-shaped skull within mesocrany (medium) range, cranial index 78.03, slightly bulging occipital, vertical forehead, and large amount of pitting scars from *cribra orbitalia* in eye orbits from childhood anemia. Signs of functional stress on upper arms and shoulders from repetitive inward rotation of arms. Developmental variants include os acromion on both scapulae, deep crescent-shaped indentations on both distal femoral medial condyles, unilateral left humeral septal aperture, and left 5th toe symphalangism, not known for right. Sex determined by very slender and gracile bones, and wide pubic arch and sciatic notch. Age based on epiphyseal closures. Stature estimated on femur length (47.4 cm).

B. Disarticulated burial. Male, 23–25 years. Redeposited bones on top of disrupted burial A. Some skeletal elements of young man including part of skull and narrow mandible with very broad chin. Some calculus on teeth. Evidence of burst fractures on vertebral fragments. Tiny ectodermal cyst that does not penetrate inner table at base of skull. Sex determined by robust skull markings and age based on dental wear and endocranial sutures.

60 Grave 2001-51 Fig. 91

Grave of unassigned style, with no discernible outline, oriented S 63° W.

Newborn. Only ribs and thoracic vertebrae remain. Lying on back with head area to west. Age determined by fibrous nature and size of bones.

61 Grave 2001-52 Figs. 23, 91

Grave of unassigned style, with no discernible outline, oriented N 85° W.

Newborn. Tiny infant with damaged skull. Semiflexed on left side of back, with head to west; legs semiflexed with ca. 100° angle at knees. Age based on fibrous nature of bones and long bone diaphyseal lengths.

62 Grave 2001-53 Figs. 17, 91, 94

Christian-style grave, oriented S 83° W, 1.90 × 0.54 × at least 0.37 m. Niche formed by two limestone blocks (20 × 18 × 9 cm, 20 × 18 × 15 cm) flanking the head, with a third (40 × 20 × 11 cm) spanning them.

Female, 19–20 years, stature 156.71 cm (5′1″). Extended on back with head to west and propped up at 45° angle to face east and tilted ca. 10° to the left, mouth agape with chin on vertebrae; left leg fully extended but right leg is slightly flared (ca. 10°) at knee that turns toward left, knees separated by 8 cm and ankles by 11 cm, both feet turn ca. 45° to left; left elbow flared outward with both forearms folded over abdomen at L2–L3, right hand between left forearm and left ilium, left hand over right upper forearm.

Ovoid-shaped skull within mesocrany (medium) range, cranial index 77.53, vertical forehead, slightly angled nose, medium face, medium squarish chin, and pronounced overbite. Enamel hypoplasia bands on canine tooth reflect metabolic disturbance in infancy around 18 and 24 months. Some fine pitting scars of *cribra orbitalia* in eye orbits from childhood anemia, and fine pitting around ear openings from childhood ear infections. She had suffered a blow to left side resulting in healed fractured 12th rib and transverse process of 1st lumbar vertebra. No signs of functional stress. Developmental variants include unilateral right scapular os

This content downloaded from 78.100.65.226 on Fri, 11 Oct 2013 01:17:53 AM
All use subject to JSTOR Terms and Conditions

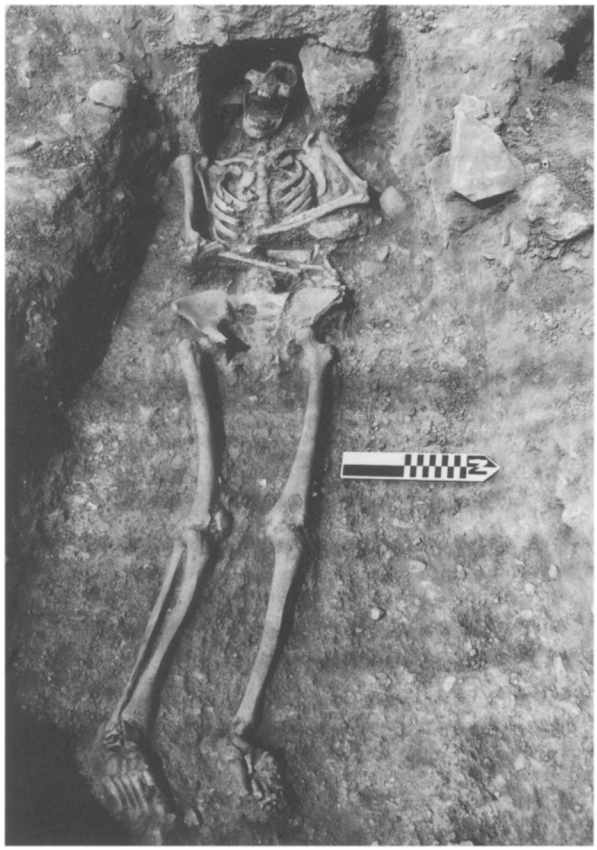

Figure 94. Christian-style grave 62

acromion, type I sternum, transitional facets moved up from 12th to 11th thoracic vertebra, and right 5th toe symphalangism (unknown for left side). Sex determined by very small, gracile bones and femoral head. Age based on dental wear, incomplete eruption of 3rd molars, and epiphyseal closures. Stature estimated on combined lengths of femur (41.1 cm) and tibia (33.2 cm).

63 Grave 2001-54 Figs. 27, 30, 91, 95

Christian-style grave, oriented N 90° W, ca. 1.20 × 0.39 m × unknown depth. Dug into grave **29** before grave **30** intruded into fill of this grave, removing child's skull and lengthening grave. French or Frankish coin (2001-212) of 13th–early 14th century in fill.

Child, 5–6 years. Extended on back with head area to west; legs fully extended with knees separated 5 cm and ankles by 6 cm and feet extended beyond ankles; upper arms flare outward from shoulders to elbows, with left forearm folded across abdomen at right angle to spine placing left hand on T9–L1 and right forearm bent toward spine with right hand over lower right ribs. Fewer than two dozen disarticulated adult bones from overlying intrusive grave **30** lie over lower legs. Coin (2001-213) of Murad IV (A.D. 1623–1640) near lower left leg. Ottoman coin (2001-217) found under body. Blue faience melon bead with bronze caps and iron rod (MF-2001-31) resting on right rib cage (Fig. 30). Blue steatite spindle whorl (half only) on right rib cage. Small lead weight (MF-2001-33) near left elbow (Fig. 27).

Damaged child's skull from overlying grave **30** matches this skeleton. Periosteal plaque above unerupted permanent 2nd molar and fine pitting scars of *cribra orbitalia* from anemia. Carabelli's cusp on upper deciduous and permanent molars. Age determined by dental development and long bone diaphyseal lengths.

This content downloaded from 78.100.65.226 on Fri, 11 Oct 2013 01:17:53 AM
All use subject to JSTOR Terms and Conditions

Figure 95. Christian-style grave 63

64 Grave 2001-55

Grave of unassigned style, oriented S 55° W (legs), >0.34 × 0.33 m × unknown depth.

Female, 20–21 years. Remnant burial consisting of lower legs extended on back with head area toward southwest and ankles separated by 5 cm. The individual was probably reburied along with other individuals in grave **35**.

65 Grave 2001-56 Fig. 91

Christian-style grave, oriented S 82° W (torso) and S 60° W (legs), 1.60 × >0.50 × >0.18 m. Flat bronze sheet fragment at grave's extreme west end.

Male, 40+ years, stature 159.85 cm (5′2″). Skull and upper body missing. Extended on back with head area to WSW; legs fully extended some 22° south from spine with knees separated by 7 cm and ankles by 4 cm, feet turned outward; left humerus flares outward from torso, but rest of arms missing.

Unilateral left tibiotalar wear facet from habitual squatting on left ankle. Signs of bending stress on upper back. Last sacral segment partially caudalized (not fused to sacrum). Sex based on narrow pubic arch, and age based on spinal DJD. Stature estimated on length of tibia (32.2 cm).

66 Grave 2001-57 Figs. 71, 91

Christian-style grave, oriented S 64° W, 2.39 × 0.42–0.55 × 0.57 m (at foot). Iron boot-heel cleat at extreme east end of grave, but not with burial A's feet.

A. Articulated burial. Male adolescent, 14–15 years. Extended on back with head to west and turned on right side to face SSE with mouth closed and chin resting on right shoulder; legs fully extended with knees separated by 4 cm and ankles by 6 cm, right foot angles outward (feet fall 0.62 m short of grave's east

This content downloaded from 78.100.65.226 on Fri, 11 Oct 2013 01:17:53 AM
All use subject to JSTOR Terms and Conditions

end); arms folded over abdomen from flaring elbows with left hand over T9–T10 and right rib cage and right hand resting on L2–L4.

Long ovoid-shaped skull, narrow face, and broad jutting chin. Signs of moderate periodontal disease around front teeth with large amount of calculus. Upper incisors curved inward, upper left 2nd molar of oblong shape, Carabelli's cusp on upper right 1st molar, and retention of upper deciduous canines. Signs of functional stress for costoclavicular ligament of right clavicle and right upper arm from repetitive forceful inward rotation and extension (unknown for left side). Both femora show stress from extending thighs. Developmental variants include type II sternum, unilateral right humeral septal aperture, and movement of transitional facets down from 12th thoracic to 1st lumbar vertebra. Sex determined by robust bones, large teeth, and narrow sciatic notch. Age based on dental development and epiphyseal fusions.

B. Disarticulated miscellaneous bones scattered over A's skeleton from neck to legs match skeletal material from grave **58** to the south and grave **59** above this grave.

67 Grave 2001-58 Fig. 96

Christian-style grave, oriented S 62° W, 1.89 × 0.59 × at least 0.45 m. Iron wire fragment in fill.

Male, 23–24 years, stature 163.77 cm (5′4″). Missing right arm and shoulder. Extended on back with head area to west. Legs fully extended with both knees and ankles slightly separated and feet extended beyond ankles; left forearm folded over abdomen (L3–L4) from flared elbow with left hand over right ilium; right hand lies above left rib cage. Iron staple or hook along left side of L3–L4.

Long pentagonoid-shaped skull within dolichocrany (long) range, cranial index 74.46, bulging occipital, fairly straight nose, and fine pitting on glabella. Pitting scars of *cribra orbitalia* from childhood anemia. Mild shovel-shaped upper incisors with ragged bite edge. Bilateral spondylolysis on 5th lumbar vertebra associated with asymmetrical neural arch and wedge-shaped vertebral body. Signs of functional stress on left forearm from overuse rotation with palm of hand down (unknown for right side). Small lesion at base of proximal phalange of right big toe (unknown for left side). Developmental variants include extreme torsion of right femoral neck (unknown for left side), cleft neural arch on 1st sacral segment, and accessory ossicle on 1st cuneiform on both feet. Sex determined by large femoral head diameter and narrow sciatic notch and pubic arch. Age based on incomplete epiphyseal fusions. Stature estimated on combined lengths of femur (42.3 cm) and tibia (33.9 cm).

68 Grave 2001-59 Fig. 96

Grave of unassigned style, oriented S 72° W (legs), ca. 1.74 × ca. 0.4 × 0.36–0.40 m.

Adult male remnant burial consisting of both feet and lower right leg extended on back with head area to WSW. Lower legs belong to one of extra males in grave **35**.

69 Grave 2001-60 Fig. 96

Christian-style grave, oriented S 64° W, 1.40 × 0.38 × 0.28 m.

Child, 8.5–9.5 years. Missing skull and part of right arm. Extended on back with head area toward WSW; legs fully extended with knees separated by 6 cm and ankles by 8 cm, feet pointing upright; left forearm bends toward abdomen from outward flaring elbow. Allen's fossa on femora. Age based on long bone diaphyseal lengths. Coins 2001-218 of Constantine I (A.D. 320) and 2001-219 of Theodosius I (A.D. 383–388), both from Thessalonica, found together between right ilium and right rib ends.

This content downloaded from 78.100.65.226 on Fri, 11 Oct 2013 01:17:53 AM
All use subject to JSTOR Terms and Conditions

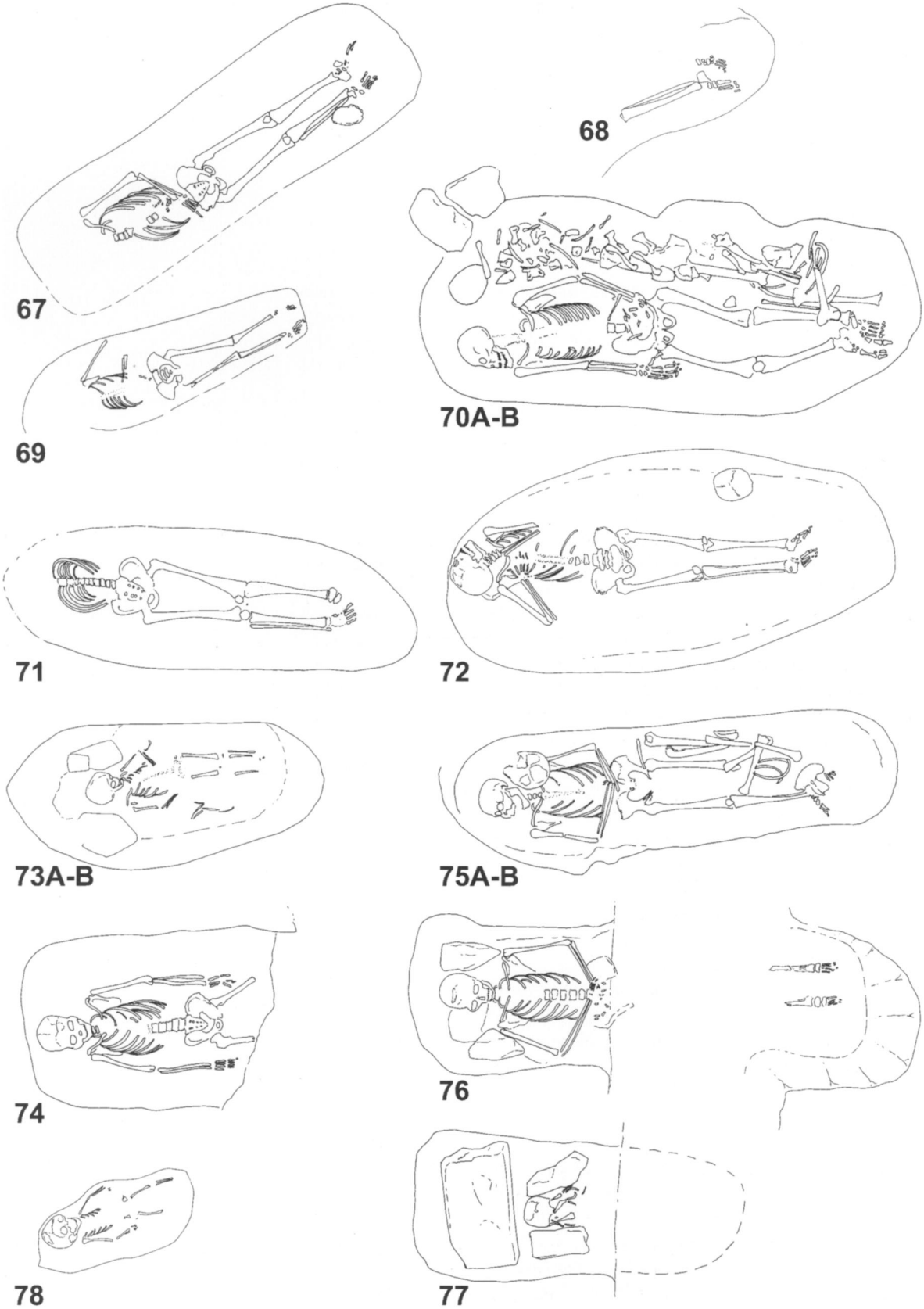

Figure 96. Graves 67–78

This content downloaded from 78.100.65.226 on Fri, 11 Oct 2013 01:17:53 AM
All use subject to JSTOR Terms and Conditions

70 Grave 2002-1 Figs. 12, 41, 96

Muslim-style grave, oriented S 80° W, 2.88 × 0.96 × 0.47 m. Two individuals represented. Articulated skeleton B displaced remains of disarticulated skeleton A to north side of grave. Coins 2002-19 of Theodosius I (A.D. 388–393) and 2002-20 of John II (A.D. 1118–1143), both in fill.

A. Disarticulated burial. Male, 30–35 years, stature 177.77 cm (5′8″). Extended on back with head to west turned onto right side to face SSE; torso turned very slightly onto right side of back; legs extended but bent slightly at knees and turned toward right; arms extended along sides, right arm straight with right hand next to right hip palm down, left arm bent slightly at elbow to place left hand palm down next to right hip.

Broad sphenoid-shaped skull within brachycrany (broad) range, cranial index 83.61, low forehead, slightly curved, projecting nose, back of skull rounded nearly flat. Periodontal disease, one large and some pinhole occlusal caries. Upper 3rd molars failed to develop, lower molars display protostylid pits. Fine pitting on both zygomatics from overlying irritation of cheeks.

Perimortem narrow oval-shaped smash wounds above knees, one on right femur and two on left femur. Old injuries include healed fractured lunate from midsection of right wrist, healed fractured ulnar styloid from left wrist, healed fractured base of tibia from left ankle, and healed crush injury between cuboid and calcaneus of right foot. Signs of functional stress on right shoulder joint and left arm from heavy use (unknown for right arm), with overuse of both wrists from grasping and clenching movements of hands while left forearm in extreme flexion. Signs of overuse flexing left foot, absent on right side. Developmental variants include incomplete transverse foramen on right side of atlas vertebra, incomplete suprascapular foramen on left scapula, and absent styloid process on right ulna. Sex determined by robust bones, large femoral head diameter, and narrow sciatic notch and pubic arch. Age based on dental wear, lack of spinal DJD, and pubic symphysis. Stature estimated on combined lengths of femur (47.8 cm) and tibia (40 cm).

B. Articulated burial. Male, 39–44 years, stature 174.85 cm (5′7″). Miniature terracotta female head lay face down on pelvis. Ovoid-shaped skull within mesocrany (medium) range, cranial index 76.11, low forehead, moderately protruding occipital, narrow mandible with medium square chin. Some periodontal disease, caries on lower right 1st molar, and large abscess associated with upper left 1st molar lost before death. Chipped upper front teeth.

Perimortem narrow oval smash wounds on lower tibia and fibula above backside of left ankle. Old injuries include two fractured right ribs (healed) from blow to back, trauma to neck resulting in slipped disc between 6th and 7th cervical vertebrae. Large brain tumor evident from irregularly shaped imprint, approximately 6.7 × 2.0 cm, inner table of occipital extending to parietal on left side of back of skull.

Signs of functional stress. Repetitive loading stress on back and heavy use of upper arms with overuse injury to tendon of teres minor on right scapula while arm was rotated outward. Distal end of left 2nd finger enlarged and flattened. Both heels reflect Achilles tendonitis from overextension, and 1st metatarsals of both feet reflect kneeling wear facets. Developmental variants include metopism on forehead (Fig. 41), unilateral right mendosa suture remnant on back of skull, and small precondylar facet with matching wear facets on atlas and dens of axis vertebrae. Wide type I sternum with misplaced manubriomesosternal joint, 12th thoracic asymmetrical apophyseal facets, and unilateral left 5th toe symphalangism. Sex determined by robust bones, large femoral head diameter, and narrow sciatic notch and pubic arch. Age based on dental wear, rib ends, spinal DJD, and pubic symphysis. Stature estimated on combined lengths of femur (46.7 cm) and tibia (38.8 cm).

This content downloaded from 78.100.65.226 on Fri, 11 Oct 2013 01:17:53 AM
All use subject to JSTOR Terms and Conditions

71 Grave 2002-2 Fig. 96

Christian-style grave, oriented S 88° W, 1.87 × 0.83 × >0.26 m. Intruded into fill of grave **72**. Roman coin (2002-24) of 4th–5th century A.D. and a metal eyelet in fill.

Male, 25–35 years, stature 172.48 cm (5′7″). Missing skull and upper body. Extended on back with head area to west; both legs fully extended with knees close together but ankles separated; pelvis tipped toward left (north). Trauma to tendon for gluteus maximus of left thigh. Large kneeling wear facet on right 1st metatarsal (unknown for left side). First caudal segment of coccyx partially united with sacrum. Sex determined by large femoral head diameter and narrow sciatic notch. Age range based on lack of spinal DJD and fused epiphyses. Stature estimated on length of fibula (37.3 cm).

72 Grave 2002-3 Figs. 21, 96

Grave of unassigned style, oriented S 80° W, 2.00 × 0.95 × >0.23 m. Grave **71** intruded into fill of this grave but did not disturb it. Late Roman(?) coin (2002-33) in fill, probably of 4th century A.D.

Male adolescent, 14–15 years. Extended on back with head to west and twisted backward and onto left side to face northwest with mouth open slightly; legs fully extended with knees and ankles apart and left leg rotated outward and feet angled toward the left; arms cross over chest with left forearm bent back on itself with left hand on neck palm down and fingers underneath right side of skull; right elbow projects outward from torso with right hand on right side of chest palm down and fingers over sternum with thumb out and fingers close together.

Skull flattened and damaged from ground pressure, and most of skeleton damaged. Some pitting lesions of *cribra orbitalia* in eye orbits from childhood anemia. Chipped upper right lateral incisor. Enamel hypoplasia bands on lower canine reflect four metabolic disturbances during infancy between 18 and 34 months. Allen's fossae on both femoral necks. Sex determined by very large epiphyseal femoral head diameter, large teeth, and narrow sciatic notch. Age based on 3rd molar crown development and epiphyseal fusions.

73 Grave 2002-4 Figs. 96, 98

Christian-style grave, oriented S 75° W, 1.39 × 0.62 × 0.26 m. Two individuals represented. Bones from disturbed burial B in fill above articulated burial A. A's head between two vertical rocks that did not prop head up; a third rock placed horizontally above the head, forming a niche. Nuremberg jeton (2002-34) of W. Lauffer II (A.D. 1612–1651) in fill (Fig. 98:36B).

A. Articulated burial. Infant, 30–36 months. Extended on back with head to west and turned toward left; legs fully extended parallel to one another with knees and ankles separated; elbows flared outward from torso, but forearms bent back toward it with right hand on right hip, palm down, and left hand on abdomen, palm down. Fragile skeletal remains with cupric stain on chin. Coin (2002-35) of Osman II (A.D. 1618–1622) found on chest where it fell from chin.

Signs of severe infection and malnutrition: fine pitting lesions of *cribra orbitalia* and raised pitting lesions on left parietal and some on right parietal from prolonged bout of anemia. Raised pitting lesions on upper portion of ramus from left side of jaw and adjacent large pitting lesions on left maxilla and right side. Similar lesions on both zygomatics and around infraorbital foramina. Developmental mendosa suture remnant on both sides of occipital. Age based on dental development and closure of anterior fontanelle.

B. Disarticulated burial. Infant, 12–16 months. Skull fragments and part of postcranial skeleton. Small amount of fine pitting of *cribra orbitalia* in eye orbits reflect anemia. Age based on diaphyseal length of left radius.

This content downloaded from 78.100.65.226 on Fri, 11 Oct 2013 01:17:53 AM
All use subject to JSTOR Terms and Conditions

74 Grave 2002-5 Fig. 96

Muslim-style grave, oriented S 80° W, >1.10 × 0.78 × >0.19 m.

Male, 16–17 years, stature 165.37 cm (5′4″). Legs missing below mid-femora. Extended on back with head to west and propped up on earth to face east with mouth closed; upper legs flare outward from hips; arms extend along sides with very slightly flared elbows and hands beside hips, palms down.

Very small build for a male. Broad sphenoid-shaped skull with flat occipital slanted inward toward mastoids within hyperbrachycrany (very broad) range, cranial index 89.09. Sloping forehead, flat skull top and broad chin. Fine pitting lesions around ear openings from past ear infections, and raised pitting lesions on palate from overlying soft tissue irritation. Large abscess associated with lower central incisor teeth. Upper incisors crowded. Signs of functional stress on both arms from forceful repetitive lifting or pulling with elbows flexed (greater on right side) and shoulders rotated. Developmental variants include mandibular coronoid hyperplasia, absence of unilateral left temporolambdoid suture, unilateral right transitional facet moved up from 12th to 11th thoracic vertebra, bilateral incomplete lateral bridge on atlas vertebra, and Allen's fossae on both femur necks. Sex determined by large femoral head diameter, large teeth, and narrow pubic arch. Age based on 3rd molar development and epiphyseal fusions. Stature estimated on length of humerus (30.2 cm).

75 Grave 2002-7 Fig. 96

Christian-style grave, oriented S 79° W, 2.05 × 0.55 × 0.32 m. Two separate burial events. Round-headed bronze pin in fill.

A. Articulated burial. Female, 50+ years, stature 159.84 cm (5′2″). Extended on back with head to west and tilted slightly to right while facing up with mouth open; legs fully extended with knees and ankles separated and feet inclined slightly to right; both arms bent across abdomen from slightly flared elbows with hands, right over left, resting on lumbar region. Iron horseshoe-shaped boot-heel cleat underneath left foot.

Ovoid-shaped skull within brachycrany (broad) range, cranial index 82.48, medium forehead, slightly curved narrow nose, wide upper face, small squarish chin. All bones light weight from osteoporosis. Severe tooth wear, some reduced to root stubs, large caries, two large abscesses, severe periodontal disease, and several teeth lost long before death with severe alveolar bone resorption. Temporomandibular joint dysfunction associated with tooth loss. Upper 3rd molars failed to develop.

Signs of functional stress on upper neck and back. Both arms show repetitive pulling inward with palms of hands down and elbows flexed. Habitual squatting reflected by tibiotalar wear facets. Sex determined by gracile bones and wide sciatic notch and pubic arch. Age based on spinal DJD, tooth loss and wear, bone atrophy, and pubic symphysis. Stature estimated on length of tibia (33.9 cm).

B. Disarticulated burial. Female, 25–30 years, stature 155.63 cm (5′1″). Mandible and most of bones from feet and hands missing. Remaining bones redeposited on and along north side of burial A, with skull against A's left cheek and atop her left shoulder, and long bones along A's left side and atop her left leg from pelvis to feet; B's ribs and pelvis over A's feet.

Ovoid–round skull within hyperbrachycrany (very broad) range, cranial index 85.71, low forehead, slightly curved narrow nose. Upper 3rd molars failed to develop. Fine chipping on upper front teeth. Signs of functional stress on both arms from repetitive pulling inward, and both distal femora show some irritation for attachment of gastrocnemius from pulling stress raising heels while knees were flexed. Left femur also shows repetitive inward rotation. Old healed shin injury on lower right leg. Developmental asymmetry of femoral necks. Sex determined by gracile bones, small femoral head diameter, small teeth, wide sciatic notch, and

This content downloaded from 78.100.65.226 on Fri, 11 Oct 2013 01:17:53 AM
All use subject to JSTOR Terms and Conditions

deep preauricular sulcus. Age based on dental wear, lack of spinal DJD, and recent fusion of upper sacrum. Stature estimated on combined lengths of femur (40.7 cm) and tibia (32.8 cm).

76 Grave 2002-8 Figs. 77, 96

Christian-style grave, oriented S 88° W, 2.20 × 0.75 × 0.48 m. Two large stones flank the head (although not propping it up), covered by a third thick stone slab above the head and shoulders, forming a niche. Directly underlies grave **77**.

Male, 25–35 years, stature 173.75 cm (5′7″). Missing most of leg bones. Extended on back with head to west and slightly propped up (ca. 35°) on a small stone to face feet (east), chin resting on chest with mouth open; legs must have been fully extended with ankles separated; arms folded over abdomen from slightly flared elbows with right hand clasping left wrist just above sacrum. Corinthian coin (2002-54) of 400–146 B.C. found on top of skeleton.

Broad sphenoid-shaped skull within brachycrany (broad) range, cranial index 82.45, rounded occipital with multiple lambdoid ossicles, medium forehead, projecting curved nose, narrow mandible with medium square chin. Upper right central incisor slightly rotated, small protostylid pits on lower 1st molars. Moderate periodontal disease and some pinhole occlusal caries. Signs of slipped disc between 12th thoracic and 1st lumbar vertebrae. Fine pitting lesions on zygomatics of both cheeks from overlying skin irritation. Upper arms show little functional stress, but right costoclavicular ligament stressed from heavy lifting or pulling with right arm. Trapezoid from left wrist displays developmental elongated extension for 2nd metacarpal articulation (unknown for right side). Sex determined by robust bones, large teeth, and narrow sciatic notch. Age based on dental wear, rib ends, and lack of spinal DJD. Stature estimated on length of humerus (33.1 cm).

77 Grave 2002-9 Figs. 30, 76, 96

Christian-style grave, oriented west, roughly >0.30 × 0.50 × 0.34 m. Head flanked by two large stones upon which rested a larger stone laid horizontally, forming a niche. Directly overlies grave **76**.

Infant, 12–14 months. Fragmented skeletal remains missing left leg. Skull placed upright facing east with the rest of the bones randomly dumped below and inside skull, indicating a secondary burial probably exhumed during digging of grave **76** and then redeposited on top of the later burial. Shell found inside skull and fragmentary bronze chain segment (both MF-2002-28) found among bones (Fig. 30). Age based on dental development, anterior fontanelle, fused neural arches, metopic suture, and diaphyseal lengths of long bones.

78 Grave 2003-1 Fig. 96

Muslim-style grave, oriented S 66° W, 0.80 × 0.40 × 0.15 m.

Infant, 6–9 months. Fragmented skeleton. Extended on back with head to southwest tilted upward toward the left; legs flare outward from hips with left lower leg bent back toward center line (right lower leg missing); arms also bow outward from torso with hands placed next to ilia, right palm down and left palm up. Age based on dental development. Small buttonlike bead left cupric stain on left temporal and could have been an earring.

79 Grave 2003-7 Figs. 49, 75, 97

Christian-style grave, oriented W, 1.30 × 0.60 × 0.38 m. Intruded into fill of grave **80**, disrupting a portion of that burial and its secondarily redeposited bone stack, causing parts of both grave **80**, burial A, and its one-time bone stack to be redeposited on top of this burial.

This content downloaded from 78.100.65.226 on Fri, 11 Oct 2013 01:17:53 AM
All use subject to JSTOR Terms and Conditions

Child, 6–7 years. Extended on back with head to west, mandible disengaged and turned slightly to left; legs extended at slight angle to spine with both knees and ankles together and feet extended; right arm bent behind back, left humerus flared slightly from spine. Metal hook and eye closure found in right rib cage still hooked together. Metal hook (same type) found 3 cm east of set.

Damaged skull. Cupric stains on all metacarpals of left hand, primarily covering palmar aspect. Small protostylid pits on permanent lower 1st molars. Developmental variants include cleft and bifurcated neural arches of sacrum and greatly enlarged anterior basivertebral foramina of thoracic and lumbar vertebral bodies (Fig. 49). Age determined by dental development, maximum width of ilium and diaphyseal lengths of long bones.

80 Grave 2003-8 Fig. 97

Christian-style grave, oriented S 85° W, 1.75 × 0.90 × 0.46 m. Five individuals represented.

A. Articulated burial. Male, 35–40 years, stature 175.1 cm (5′7″). Extended on back with head area to west, spine and torso curve slightly to left (north); legs fully extended with knees only slightly separated and ankles together with feet extended beyond ankles on outer edges; arm long bones missing, but wrist and hand bones lie on opposite sides of spine, suggesting that arms had been folded across abdomen with left hand beneath right.

Skull, upper vertebrae, and arms found among bone piles above grave **79**. Pelvis, most of rib cage, and some arm bones missing. Damaged skull (missing face) appears very broad and spheroid in shape within brachycrany (broad) range, with pronounced bulging occipital. Only a few teeth present with two pinhole occlusal caries. Signs of functional stress on lower lumbar spine and shoulders from heavy lifting. Femora show overuse flexing and rotating thighs. Separate ossicle formed from tubercle of 5th metatarsal from left foot. Sex determined by robust bones. Age based on dental wear, mild spinal DJD, and rib ends. Stature estimated on length of tibia (38.5 cm).

B–E. Disarticulated burials. Commingled remains of a woman, a child, and two infants. B is a female, 40–45 years, stature 151.66 cm (4′10″). Her skull and various postcranial elements are in a bone stack over pelvic area of burial A. The various elements of the other individuals are in two bone piles over burial A. C is a child of 9–10 years, D is a newborn, and E is an infant of 3–6 months.

Adult female B's skull is missing its face. It is of a broad sphenoid shape within brachycrany (broad) range, cranial index 82.58, low forehead, narrow mandible with protruding medium square chin; large cupric stain on back of skull. Some teeth reduced to root stubs, some lost before death; severe caries with abscesses. Protostylid pit on lower 3rd molar. Fine pitting lesions on zygomatics of both cheeks from overlying skin irritation, and similar lesions on back of skull. Signs of functional stress from overuse of woman's left arm and shoulder (unknown for right side); osteochondritis in left knee, osteoarthritis in both feet, and plantar tendonitis from pulling stress on ball of left foot. Sex determined by small femoral head diameter and gracile bones. Age based on dental wear and tooth loss, while stature estimated on length of femur (39.5 cm).

Fragments of child C's skull and teeth, with Carabelli's cusp on upper molar, deciduous molar with occlusal caries, and enamel hypoplasia band on permanent canine crown reflecting metabolic disturbance during infancy around 34 months. Cupric stain on phalanges of child's finger. Age of child based on dental development and diaphyseal length of humerus.

Newborn D defined by cranial and mandibular pieces, and some skeletal elements that are small and fibrous in nature. Older infant E represented by some cranial fragments and skeletal elements; age based on diaphyseal length of tibia.

This content downloaded from 78.100.65.226 on Fri, 11 Oct 2013 01:17:53 AM
All use subject to JSTOR Terms and Conditions

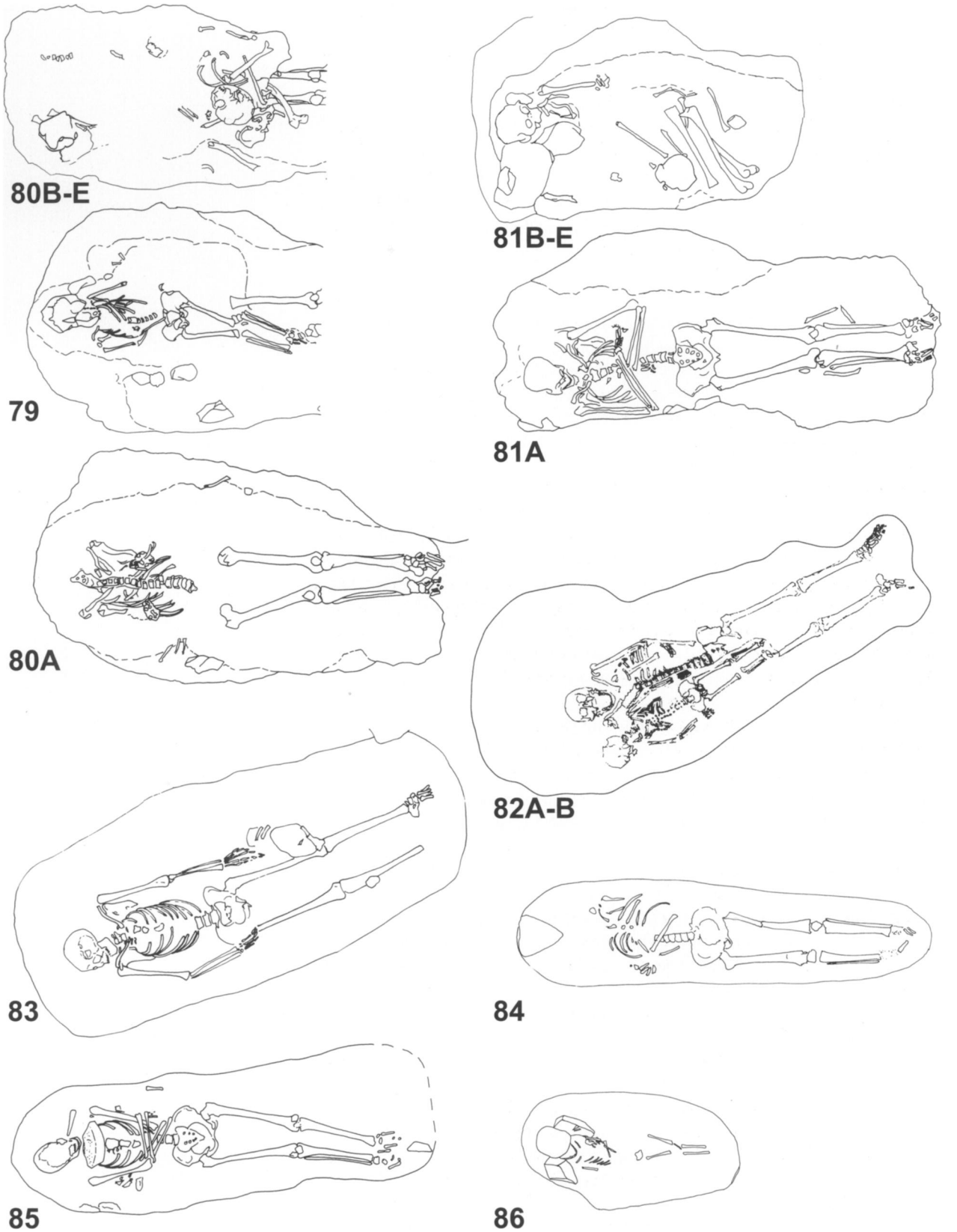

Figure 97. Graves 79–86

This content downloaded from 78.100.65.226 on Fri, 11 Oct 2013 01:17:53 AM
All use subject to JSTOR Terms and Conditions

81 Grave 2003-10 Figs. 38, 97, 98

Christian-style grave, oriented S 88° W, 1.95 × 0.70 × 0.45 m. Five individuals represented. A Corinthian coin (2003-10) of 400–146 B.C. was found on top of the grave fill, and a coin (2003-20) of the Corinthian *duoviri* (A.D. 12–16) in the fill (Fig. 98:4).

A. Articulated burial. Male, 22–24 years, stature 178 cm (5′8″). Extended on back with head to west and propped up on cushion of earth to face east (feet) and turned very slightly toward right (south); legs fully extended with knees and ankles together and feet turned laterally; arms folded over chest from slightly flaring elbows with left forearm crossing under right and left hand twisted so fingers point toward pelvis. Two cupric stains on burial A's bones suggest former presence of coins: one on maxilla next to left 1st molar, the other a round stain on left 4th proximal finger phalange. Iron boot cleat found by left foot.

Ovoid-shaped skull within mesocrany (medium) range, cranial index 77.40, high-backed skull with flat occipital, low sloping forehead, curved narrow nose, and medium squarish chin (Fig. 38). Some dental calculus with mild periodontal disease and chipped canines. Lower right 1st molar reduced to root stub by severe caries with associated large abscess, interproximal caries on lower left 1st molar. Developmental spaces between lateral incisors (upper and lower) and canines, upper right incisors.

Signs of functional stress on neck vertebrae. Left clavicle and both arms show signs of overuse raising, flexing, and extending arms inward, with palms of hands up. Phalanges of both hands show signs of overuse gripping. Signs of osteochondritis on both proximal tibiae reflect chronic stress on knee joints, while signs of overuse flexion and rotation of the left thigh appear on the femur (absent on right leg). Left lower leg also stressed during adolescence, reflected by bony spicules on tuberosity, known as Osgood-Schlatter disorder (absent on right side). Developmental variants include mild expression of occipital vertebra at base of skull and unilateral left scapular os acromion. Sex determined by large femoral head diameter and narrow sciatic notch. Age based on dental wear, incomplete fusion of sacral segments, recent fusion of iliac and ischial crests, and incomplete fusion of vertebral epiphyseal rings. Stature estimated on length of tibia (39.7 cm).

B–E. Commingled, disarticulated skeletal remains of an older man, a woman, a young baby, and an older child piled in two bone stacks over burial A's head and legs. B is a male, 50+ years, stature 174.62 cm (5′7″); C is a female, 30–40 years, stature 170.19 cm (5′6″); D an infant, 1–3 months; and E a child, 10–12 years. Associated with the bone pile over burial A's feet was an Ottoman coin (2003-21) of uncertain date and ruler.

Damaged skull of male B is a broad sphenoid shape within brachycrany (broad) range, cranial index 81.92, with very broad forehead and metopism, projecting curved nose, rounded occipital with pronounced nuchal ridge. Erosive lesions from temporomandibular joint dysfunction where jaw meets skull; mandible missing. Only a few upper teeth worn to root stubs left in place, with severe periodontal disease and a large abscess. The skull of female C is rhomboid-shaped within mesocrany (medium) range, cranial index 75.53, low forehead, and protruding occipital; with mandible. Skull vault unusually thick (1.1 cm). Two teeth lost before death and one molar reduced to root stub by severe caries.

Signs of functional stress on robust vertebrae from man's neck and back, along with osteochondritis in both knees reflected by lesions on distal femora. Left arm also shows heavy use, and he displays healed smash injury to left thumb and old injury to left 4th finger. Developmental variants on adult bones include fused manubriomesosternum joint, and unilateral right scapular os acromion from matching pair of scapulae. Sexes determined by gracile and robust bones, and ages based on dental wear and spinal DJD. Male stature estimated on length of humerus (33.4 cm).

This content downloaded from 78.100.65.226 on Fri, 11 Oct 2013 01:17:53 AM
All use subject to JSTOR Terms and Conditions

Outlying Post-Medieval Graves in Panayia Field

Although not clearly a part of the cemetery excavated in the northeastern Panayia Field described above, several additional nearby post-medieval graves are catalogued below. Two apparently Muslim-style graves (**82, 83**) lie 24 m southeast of the cemetery. Three other unexcavated grave outlines continue beneath the excavation's eastern scarp. All five of these graves seem to occur along what we believe to have been a minor road or path leading away from the center of Corinth village toward the southeast. This road probably passed to the east of the early-17th-century cemetery as well. The area between grave **1** at the southeastern edge of the cemetery and these five graves has not been excavated.

Three other Christian-style graves (**84, 85, 86**) were excavated to the west of the early-17th-century cemetery in what appears to have been the southern reaches of the large cemetery associated with the Old Panayia Church during the 18th, 19th, and early 20th centuries. Excavations in this area also revealed the outlines of at least three additional unexcavated graves, and many more outlines have also appeared to the north, next to where the church once stood.

82 Grave 1996-8 Fig. 97

Muslim-style grave, oriented S 65° W, ca. 2.25 × ca. 0.80 × 0.47 m. Two individuals represented. Probable coffin suggested by numerous iron nails, the large size of the grave, and the conformity of the two bodies within the space. Coin (1996-322) of Arcadius (A.D. 383–408) found in fill.

A. Articulated burial. Male, 40–45 years, stature 155.9 cm (5′1″). Extended on back with head to WSW facing up; legs fully extended with feet turned slightly outward; upper arms extended straight along sides with lower arms bent slightly so hands lay over hips, palms down.

Small man with ovoid–round skull within brachycrany (broad) range, cranial index 81.65, low forehead, rugose occipital protuberance, medium rounded chin, flaring gonials. Face damaged and some parts of skeleton missing. Pitting scars of *cribra orbitalia* in eye orbits from childhood anemia. Chipped upper right 2nd premolar, lower right 2nd molar lost before death; moderate periodontal disease.

Signs of functional stress on both arms from heavy lifting to a fixed level with more force on left shoulder and left thumb. Osteochondritis in right knee (unknown for left side), and signs of two slipped discs in lower back. Developmental variants include the lack of 12th ribs with movement of transitional facets up from 12th to 11th thoracic vertebra, bilateral os japonicum, type II sternum with xiphoid fused to sternum, and a large Allen's foss0a on femur neck. Sex determined by robust bones and narrow sciatic notch. Age based on dental wear, rib ends, and pubic symphysis. Stature estimated on combined lengths of femur (38.5 cm) and tibia (31 cm).

B. Articulated burial. Infant, 30–36 months. Extended on back on top of right side of A, with head to WSW and turned onto right side to rest on right shoulder; legs fully extended; arms extended along sides and bent inward with hands at sides, palms down. Damaged skeleton with no apparent pathology. Bifurcated neural arch of 1st sacral segment. Age based on dental development and long bone diaphyseal lengths.

83 Grave 2003-11 Fig. 97

Muslim-style grave, oriented S 70° W, 2.45 × 0.96 × 0.27 m.

Male, 22–24 years, stature 176.15 cm (5′8″). Extended on back with head to WSW and turned onto right side so chin rested on right clavicle facing east; legs

This content downloaded from 78.100.65.226 on Fri, 11 Oct 2013 01:17:53 AM
All use subject to JSTOR Terms and Conditions

extended parallel to one another with knees and ankles separated and left foot turned outward; arms extended along sides of torso with palms down, left hand next to left femur head, and right hand resting on right ilium, causing the right elbow to be bent slightly.

Ovoid-shaped skull within mesocrany (medium) range, cranial index 75.40, rounded occipital with pronounced nuchal ridge, narrow straight nose within narrow face, rounded chin, and large overbite. Carabelli's cusps on upper 1st molars, tiny protostylid pit on lower left 3rd molar. Some calculus on lower front teeth, and broken crown on upper right central incisor. Enamel hypoplasia bands on upper canine reflect three episodes of metabolic disturbance during infancy between 24 and 34 months.

Old injuries include healed circular depression fracture above right eye, and healed fractured of right clavicle. Signs of functional stress on shoulders and upper arms, with deep lesions for costoclavicular ligaments, greater on left side, from repetitive overuse extending arms with force on wrists overhead, rotating right arm out and back. Early stages of osteochondritis on right knee reflected by lesion on patella. Burst fractures on lower thoracic vertebrae from repeated heavy loading on spine, and kneeling wear facet on 1st metatarsal of left foot (unknown for right side).

Developmental variants include complete caudal shifting of sacrolumbar and sacrocaudal borders with complete separation (lumbarization) of 1st sacral segment and fusion of 1st caudal of coccyx to sacrum, unilateral left posterior bridge of atlas vertebra, asymmetrical torsion of femoral necks, unilateral left os trigonum (separate ossicle on talus), and bilateral expression of nonosseous coalition of 3rd metatarsals and cuneiforms in the feet. Sex determined by robust bones, large femoral head diameter, and narrow sciatic notch and pubic arch. Age based on dental wear, incomplete fusion of sternal ends of clavicles, and pubic symphysis. Stature estimated on combined lengths of femur (47.2 cm) and tibia (39.4 cm).

84 Grave 2002-6 Fig. 97

Christian-style grave, oriented W, 1.80 × 0.48 × >0.185 m.

Male, 17–18 years. Most of upper body missing, lower limbs damaged. Extended on back with head area to west; legs fully extended with ankles together and feet pointing up; both arms disrupted but apparently had once been folded across abdomen because hand digits lay on opposite sides of torso. Sex based on narrow sciatic notch. Age determined by epiphyseal fusions.

85 Grave 2002-10 Fig. 97

Christian-style grave, oriented S 88° W, 1.87 × 0.62 × 0.23–0.31 m.

Female, 27–30 years, stature 159 cm (5′2″). Extended on back with head to west and slightly propped up and turned ca. 15° toward the left; legs fully extended with ankles together and feet extended angling slightly toward right; arms crossed over abdomen with both elbows pulled inward over the 5th–6th ribs, with left wrist located directly under right elbow; right wrist on top of left humerus above the elbow.

Ovoid-shaped skull within mesocrany (medium) range, cranial index 77.40, protruding occipital, medium chin. Face missing. Both upper 3rd molars impacted, lower right 3rd molar failed to develop. Slight periodontal disease around front teeth. Goutlike lesion on capitate from right wrist. Signs of heavy lifting in upper arms, and hyperextension wear facets on proximal phalanges of both thumbs (greater on left thumb). Developmental variants include bilateral lateral bridge on atlas vertebra, cleft neural arch of 1st sacral segment, and sacralized 1st caudal of

This content downloaded from 78.100.65.226 on Fri, 11 Oct 2013 01:17:53 AM
All use subject to JSTOR Terms and Conditions

coccyx. Sex determined by gracile bones, small femoral head diameter, and wide sciatic notch and pubic arch. Age based on dental wear, lack of spinal DJD, and pubic symphysis. Stature estimated on combined lengths of femur (42.6 cm) and tibia (33.5 cm).

86 Grave 2003-3 Fig. 97

Christian-style grave, oriented W, 0.90 × 0.55 × >0.13 m. Two stones flank the head. A larger stone rests partially over right rib cage and pelvis and a smaller one against the left side; a tile rests on top of these two stones. A small stone props up the chin.

Infant, 18–20 months. Fragmented skeleton. Extended on back with head to west facing up; legs fully extended with both knees and ankles together; both upper arms lie alongside the rib cage with the left forearm bent ca. 75° across abdomen; right forearm missing. Small terracotta cross (MF-2003-3) found on chest. Age based on dental development and fused neural arches of vertebrae.

This content downloaded from 78.100.65.226 on Fri, 11 Oct 2013 01:17:53 AM
All use subject to JSTOR Terms and Conditions

APPENDIX
THE COINS

This appendix presents the coins and coinlike objects excavated from the general area of the 17th-century cemetery in Panayia Field.[46] The sample includes 35 pieces removed from the graves themselves and another 17 coins found around and above the graves in contexts defining the date of that cemetery. It also includes one coin found in grave **82**, outside the perimeter of the main cemetery. The numismatic material consists, then, of 53 pieces, of which five are jetons (coinlike disks used in the Later Middle Ages and beyond for ornamental and other purposes), the rest being regular coins.[47]

Most of the coins listed in the catalogue below, both those found inside and outside the graves, were found singly. Thirteen pieces, however, were discovered in three distinct groupings that technically can be considered hoards. These aggregates are (1) five Ottoman *akches* (coins 2001-189 to 2001-193) found together in a pile in grave **20**; (2) five Ottoman *paras* (coins 2000-126, 2000-127, 2000-133 to 2000-135) found in a saucer-shaped pit or dump (pit 2000-1, pottery lot 2000-23); and (3) three jetons (coins 2001-196, 2001-199, 2001-200) from grave **33**.

Of these hoards, the *paras* found in the dump clearly represent an unintentional loss; they were found mixed with other discarded objects, although they came up together, four of them back to back. The other two hoards, however, come from inside the graves, and were certainly placed there for a purpose. Indeed, the three jetons in grave **33** were probably part of a necklace (Fig. 31).[48] The purpose of the five *akches* from grave **20** is not altogether clear. They cannot have been used decoratively, either on a necklace or in some other way, since they were found stuck together, and only the topmost coin was perforated; it must be that these tiny coins had been tossed into the grave as a packet, before or while the deceased was lowered into the grave.[49] For the placement of the single finds, especially those deriving from inside the graves, see the catalogue of graves presented above.

Of particular interest are the two jetons (in graves **33** and **54**) found with remnants of cloth adhering to them. The phenomenon in which a fabric is preserved by virtue of its clinging to the oxidized surface of bronze

46. I am indebted to Slobodan Srećković for reading and dating the entire series of Ottoman coins (catalogue nos. 19–31). I have also profited from additional discussion with Panayiotis Kokkas on specific pieces.

47. Other finds of jetons in Greece and their uses are discussed in Wilski 1993, esp. pp. 45–47; and Kasdagli 1999, esp. pp. 119–121 (in Greek), 129–132 (in English). For general information about numismatic finds from graves (4th century B.C. to modern times), see Lazaridis, Romiopoulou, and Touratsoglou 1992, pp. 47–61; Tselekas 1996, passim; and *Neuchâtel Colloquium,* passim.

48. For descriptions of these jetons, see "Burial Accompaniments," above, and the commentary below.

49. The individual in this unusual burial had an iron hook passed through his shoulder and was interred face down.

This content downloaded from 78.100.65.226 on Fri, 11 Oct 2013 01:17:53 AM
All use subject to JSTOR Terms and Conditions

or billon coins, or to other objects of such metals,[50] is well known. From the Corinth excavations come several other recorded instances of coins carrying remnants of textile, none of which, however, originated in a cemetery.[51]

For convenience, I preface the coin catalogue with a list in which each coin is listed by its excavated context, with a cross-reference to its number in the catalogue. Notes on individual pieces are also given in a commentary at the end of this appendix.

CONTEXT LIST OF COINS

Panayia Field Cemetery

Grave **3**		
2000-139	Valentinian II	No. 9
Grave **17**		
2001-197	Mehmed III	No. 21
Grave **20** (hoard of *akches*)		
2001-189	Ahmed I	No. 22
2001-190	Mehmed III	No. 20
2001-191	Mehmed III	No. 19
2001-192	Mehmed III	No. 20
2001-193	Uncertain Ottoman	No. 31
Grave **23**		
2001-185	Valentinian I–II	No. 6
Grave **24**		
2001-186	Late Roman	No. 15
Grave **28**		
2001-188	Late Roman	No. 15
Grave **29**		
2001-195	Late Byzantine	No. 18
2001-216	Osman II	No. 24
Grave **30**		
2001-207	Late Roman	No. 15
Grave **33** (jetons on necklace)		
2001-196	Jeton (uncertain master)	No. 35
2001-199	Jeton (Lauffer)	No. 36
2001-200	Jeton (Krauwinckel)	No. 34
Grave **42**		
2001-208	Corinth, *duoviri*	No. 3
Grave **43**		
2001-206	Valentinian II	No. 7
Grave **46**		
2001-210	Uncertain Ottoman	No. 31
Grave **54**		
2001-211	Jeton (Lauffer)	No. 36
Grave **58**		
2001-209	Uncertain Ottoman	No. 31

50. See, for example, the recent discovery at Hellinikon, Attica, of a funerary bronze hydria with a patch of cloth clinging to its shoulder: *Kathimerini,* August 24, 2003, section "Τέχνες και γράμματα," p. 1.

51. At least three hoards dating from the Early Byzantine and Late Medieval periods include textile remnants: (a) hoard from south of the Sacred Spring (August, 17, 1905); (b) hoard from west of St. John's (April 29, 1907); and (c) hoard from south of the Old Museum (July 17, 1925), a Byzantine hoard described by Broneer (1926, pp. 52–53).

This content downloaded from 78.100.65.226 on Fri, 11 Oct 2013 01:17:53 AM
All use subject to JSTOR Terms and Conditions

Grave **63**

2001-212	French or Frankish	No. 32
2001-213	Murad IV	No. 25
2001-217	Uncertain Ottoman	No. 31

Grave **69**

2001-218	Constantine I	No. 5
2001-219	Theodosius I	No. 10

Grave **70**

2002-19	Theodosius I	No. 11
2002-20	John II	No. 16

Grave **71**

2002-24	Late Roman	No. 15

Grave **72**

2002-33	Late Roman	No. 15

Grave **73**

2002-34	Jeton (Lauffer)	No. 36
2002-35	Osman II	No. 23

Grave **76**

2002-54	Corinth, P/T	No. 1

Grave **81**

2003-20	Corinth, *duoviri*	No. 4
2003-21	Uncertain Ottoman	No. 31

Outlying Grave

Grave **82**

1996-322	Arcadius	No. 13

Fills Associated with the Main Cemetery

Pit (pottery lot 2000-23) cutting into and through the southwestern part of the cemetery (hoard of *paras*)

2000-126	Mustafa III	No. 26
2000-127	Abdul Hamid I	No. 29
2000-133	Abdul Hamid I	No. 29
2000-134	Abdul Hamid I	No. 28
2000-135	Abdul Hamid I	No. 27

Pit (pottery lot 2001-13) cutting into grave **9**

2001-117	Venetian	No. 33

Other fills from around and above the graves

2001-118	Mustafa III	No. 26
2001-120	Valentinian III	No. 14
2001-149	Selim III	No. 30
2001-152	Valentinian II	No. 8
2001-162	Arcadius	No. 12
2001-170	Corinth, P/T	No. 2
2001-194	Late Roman	No. 15
2001-198	Late Roman	No. 15
2001-205	Late Roman	No. 15
2002-21	Manuel I	No. 17
2003-10	Corinth, P/T	No. 2

This content downloaded from 78.100.65.226 on Fri, 11 Oct 2013 01:17:53 AM
All use subject to JSTOR Terms and Conditions

Figure 98. Coins recovered from the Panayia Field cemetery excavations.
Scale 1:1 unless otherwise noted



CATALOGUE

The following conventions are used in this catalogue: (1) silver and billon coins are indicated by numbers in *italic type;* (2) an asterisk (*) means that commentary follows at the end; (3) a single dagger (†) indicates a coin from a grave outside the main cemetery; and (4) a double dagger (‡) means that the piece is illustrated in Figure 98. For Turkish coins *(akches)* 2001-189 to 2001-193 from grave **20**, see Figure 26, above. Jetons 2001-196, 2001-199 and 2001-200 from grave **33** are illustrated as a group in Figure 31. Jeton 2001-211 from grave **54**, probably part of a necklace, is shown in Figure 32.

GREEK COINAGE (5)

Corinth

*1.	13 mm	400–146 B.C.	Pegasos flying l./Trident. A--(?)	*Corinth* VI, no. 11	2002-54
2.	13 mm	400–146 B.C.	Illegible or Pegasos l./ Trident. Uncertain controls		2001-170 2003-10

The Duoviri

		Primus-Hipparchus			
3.	21 mm	2–1 B.C.	Head r./Two heads face-to-face	Amandry 1988, XI.b *Rev.* C.L (dot)	2001-208
		Labeo-Plancus			
*4.	19 mm (ctmk.)	A.D. 12–16	Head r./Pegasos r.	Amandry 1988, XIV, nos. 54, 55	‡2003-20

This content downloaded from 78.100.65.226 on Fri, 11 Oct 2013 01:17:53 AM
All use subject to JSTOR Terms and Conditions

ROMAN IMPERIAL COINAGE (18)

Constantine I, A.D. 307–337

		Thessalonica			
5.	20 mm	A.D. 320	VIRTVS EXERCIT Vexillum	*RIC* VII, no. 80	2001-218

Valentinian I–II

		Uncertain mint			
6.	16 mm	—	SECVRITAS REIPVBLICAE Victory l.	cf. *LRBC* II, no. 2071	2001-185

Valentinian II, A.D. 375–392

		Thessalonica			
7.	12 mm	A.D. 383–388	GLORIA REIPVBLICE Camp gate (*Officina* A)	*RIC* IX, no. 62(a)	‡2001-206
		Cyzicus			
*8.	16 mm	A.D. 388–395	SALVS REIPVBLICAE Victory, captive (*manus dei* for trophy)	*RIC* IX, no. 26(a)	2001-152
		Uncertain mint			
9.	13 mm	—	SALVS REIPVBLICAE Victory, captive (*Symbol* ☨)	cf. *LRBC* II, no. 2183	2000-139

Theodosius I, A.D. 379–395

		Thessalonica			
10.	16 mm	A.D. 383–388	VIRTVS AVCCC Emperor on ship (*Officina* A or Δ)	*RIC* IX, no. 61(b)	2001-219
11.	13 mm	A.D. 388–393	SALVS REIPVBLICAE Victory, captive	*RIC* IX, no. 65(b)	2002-19

Arcadius, A.D. 383–408

		Heraclea or *Nicomedia*			
12.	11 mm	A.D. 402–408	CONCORDIA AVCCC Cross	*LRBC* II, no. 1996 or 2451	2001-162
		Uncertain mint			
*13.	13 mm	—	SALVS REIPVBLICAE (or REIPVBLICE) Victory, captive (*Symbol* ☨)	cf. *LRBC* II, no. 2185	†1996-322

Valentinian III, A.D. 425–455

		Rome			
14.	12 mm	A.D. 425–435	VICTORIA AVCCC Victory l.(*Officina* Q)	*RIC* X, no. 2118 or 2119	‡2001-120

Uncertain Late Emperor

		Uncertain mint			
*15.	17–19 mm	—	VOT V MVLT X in wreath		2001-207
			Uncertain type		2001-194
			Uncertain type		2001-198

This content downloaded from 78.100.65.226 on Fri, 11 Oct 2013 01:17:53 AM
All use subject to JSTOR Terms and Conditions

Uncertain Late Emperor *(cont.)*

		Uncertain mint			
*15.	17–19 mm	—	Uncertain type		2001-205
			Uncertain type		2002-24
			Uncertain type		2002-33
			Uncertain type (minimus)		2001-186
			Uncertain type (minimus)		2001-188

BYZANTINE COINAGE (3)

John II, A.D. 1118–1143

		Thessalonica			
16.	Tetart. (halved)	A.D. 1118–1143	Christ bust/Emperor bust	*DOC* 4.1, p. 270, no. 14	2002-20

Manuel I, A.D. 1143–1180

		Unattributed			
17.	Half-tetart. (1.36 g)	A.D. 1143–1180	St. George bust/Emperor bust	*DOC* 4.1, p. 337, no. 23	2002-21

Uncertain Emperor, 10th–11th Century A.D.

		Uncertain mint			
*18.	23 mm	—	Bust (in halo?) / Bust (in halo?)		2001-195

OTTOMAN TURKISH COINAGE (20)

Mehmed III, A.D. 1595–1603

		Belgrade			
19.	11 mm *(akche)*	A.D. 1595–1603	Inscription/Inscription	Sultan 1977, no. 1331	2001-191
		Constantinople			
20.	10–11 mm	A.D. 1595–1603	Inscription/Inscription	Sultan 1977, no. 1366	2001-190 2001-192
		Cyprus			
21.	11 mm *(akche)*	A.D. 1595–1603	Inscription/Inscription	Sultan 1977, no. 1398 (holed)	‡2001-197

Ahmed I, A.D. 1603–1617

		Constantinople			
22.	12 mm *(akche)*	A.D. 1603–1617	Inscription/Inscription	Sultan 1977, no. 1517 (holed)	2001-189

Osman II, A.D. 1618–1622

		Diyarbekir (Amid)			
**23.*	12 mm *(akche)*	A.D. 1618–1622	Inscription/Inscription	Sultan 1977, no. 1608	2002-35
		Uncertain mint			
**24.*	12 mm *(akche)*	—	Inscription/Inscription	cf. Pere 1968, no. 404	2001-216

This content downloaded from 78.100.65.226 on Fri, 11 Oct 2013 01:17:53 AM
All use subject to JSTOR Terms and Conditions

Murad IV, A.D. 1623–1640

		Cairo			
25.	16 mm Medin *(para)*	A.D. 1623–1640	Inscription/Inscription	Sultan 1977, no. 1700	2001-213

Mustafa III, A.D. 1757–1774

		Cairo			
26.	16 mm *(para)*	A.D. 1757–1774	Inscription (tughra)/Inscription	Sultan 1977, no. 2296 (both holed)	2000-126 2001-118

Abdul Hamid I, A.D. 1774–1789

		Constantinople			
**27.*	15 mm *(para)*	A.D. 1783 (regnal year 10)	Inscription (tughra)/Inscription	Sultan 1977, no. 2371	2000-135
28.	15 mm *(para)*	A.D. 1786 (regnal year 13)	Inscription (tughra)/Inscription	Sultan 1977, no. 2375	‡2000-134
		Cairo			
**29.*	15 mm *(para)*	A.D. 1775 (regnal year 2)	Inscription (tughra)/Inscription	Sultan 1977, no. 2461	2000-127 2000-133

Selim III, A.D. 1789–1807

		Cairo			
30.	15 mm *(para)*	A.D. 1789–1807	Inscription (tughra)/Inscription	Sultan 1977, nos. 2613 ff. (holed)	2001-149

Uncertain Ruler

		Uncertain mint			
**31.*	11 mm *(akches)*		Inscription/Inscription		2001-193 2001-209 2001-210 2001-217 2003-21

WESTERN MEDIEVAL COINAGE (2)

		French or *Frankish*			
**32.*	mm— (denier)	13th–14th century	(legend) Cross pattée/ (legend) Castle Tournois	cf. Metcalf 1995, no. 913 (cut down; holed)	2001-212
		Venetian colonial			
**33.*	14 mm Gazzetta	A.D. 1684–1710	DALMA ET ALBA(N)	Papadopoli 1919, pp. 927–933, nos. 7–51 (holed)	2001-117

JETONS (5)

**34.*		Counter of H. Krauwinckel II, A.D. 1586–1635 (Nuremberg)	2001-200
35.		Counter of uncertain master (Nuremberg?)	2001-196
**36.*		Counter of W. Lauffer II, A.D. 1612–1651 (Nuremberg)	2001-199 ‡2001-211 ‡2002-34

This content downloaded from 78.100.65.226 on Fri, 11 Oct 2013 01:17:53 AM
All use subject to JSTOR Terms and Conditions

COMMENTARY

(1) In his study of the autonomous bronze coinage of Corinth, Price (1967) describes two separate issues with field control A, one belonging in group IV (340–335 B.C.) and another in group IX (252–248 B.C.), distinguishable both by style and by field symbols. The coin from grave **76**, 2002-54, with its symbol effaced, definitely belongs to Price's second group. Price's chronological outline of the Corinthian bronze coinage is explicitly noted in a recent auction catalogue: Numismatik Lanz, Munich, Auction 105, November 26, 2001, especially lots 237–242 and 299–300.

(4) Countermark: *annulus.*

(8) The curious substitution of *manus dei* for the Victory's trophy on the reverse of the Salus Reipublicae issue, not noticed in the standard references, seems to occur only on the coins of Cyzicus and, less frequently, on those of Heraclea. See Mac Isaac 1975, p. 326, n. 22; Williams and Zervos 1990, p. 363, no. 38, p. 368, n. 38.

(13) Some of the letter shapes are odd: H for A, II for V, and so on, probably due to the use of lettering punches.

(15) Coin 2001-207. Fragment.

(18) Coin is octagonally clipped, probably a follis (11th–12th century A.D.). Weight 3.13 g.

(23) Fragment.

(24) Fragment.

(27) Almost certainly regnal year 10.

(29) Coin 2000-127. The regnal year is blurred; it may be year 3.

(31) Coins 2001-193, 2001-209, and 2001-217 are all fragmentary and may have originally been holed. Coin 2003-21 is possibly a counterfeit. Originally silver-washed, now only the copper core remains. Flan holed.

(32) This denier tournois is cut down and holed twice along its diameter (Diam. 11.5 mm).

(33) Square hole near the rim.

(34) Jeton 2001-200 (Krauwinckel). Found with cloth adhering to its obverse side, the cloth now partly removed. The obverse legend is totally gone. Cf. Mitchiner 1988, pp. 441–442, nos. 1540–1550. Flan holed. All four identifiable jetons, 2001-199, 2001-200, 2001-211, and 2002-34 (cat. nos. 34, 36) belong to the popular "Rose/Orb" series. The fifth piece, coin 2001-196 (cat. no. 35), is virtually illegible but probably also a jeton of Nuremberg; flan holed.

(36) Jeton 2001-199 (Lauffer): cf. Mitchiner 1988, p. 483, no. 1703, reverse legend variant. Flan holed. Jeton 2001-211 (Lauffer): found with cloth adhering to its obverse (as jeton 2001-200, above); cf. Mitchiner 1988, p. 484, no. 1713, reverse legend variant. Holed twice (with a bit of original string preserved in one hole). Jeton 2002-34 (Lauffer): see Mitchiner, p. 484, no. 1709. Holed twice.

Orestes H. Zervos

American School of Classical Studies at Athens
Corinth Excavations
54 Souidias Street
106 76 Athens
Greece

ozervos.corinth@ascsa.edu.gr

This content downloaded from 78.100.65.226 on Fri, 11 Oct 2013 01:17:53 AM
All use subject to JSTOR Terms and Conditions

REFERENCES

Amandry, M. 1988. *Le monnayage des duovirs corinthiens* (*BCH* Suppl. 15), Paris.

Baram, U., and L. Carroll, eds. 2000a. *A Historical Archaeology of the Ottoman Empire: Breaking New Ground* (Contributions to Global Historical Archaeology), New York.

———. 2000b. "The Future of the Ottoman Past," in Baram and Carroll 2000a, pp. 3–32.

Barnes, E. 1994. *Developmental Defects of the Axial Skeleton in Paleopathology,* Niwot, Colo.

———. 2003. "The Dead *Do* Tell Tales," in *Corinth* XX, pp. 435–443.

———. In prep. *Medieval Burials from the Frankish Area of Corinth.*

Bass, W. M. 1987. *Human Osteology: A Laboratory and Field Manual,* 3rd ed., Columbia, Mo.

Blackman, D. 1999. "Archaeology in Greece, 1998–99," *AR* 45, pp. 1–124.

Broneer, O. 1926. "Excavations at Corinth, 1925: Area North of Basilica," *AJA* 30, pp. 49–57.

Brothwell, D. R. 1981. *Digging Up Bones: The Excavation, Treatment, and Study of Human Skeletal Remains,* 3rd ed., London.

Chrysafi-Zografou, M. 1984. "Τουρκικά κτίσματα στην Κόρινθο: Κρήνες και θρησκευτικά κτήρια," in *ΥΠΠΕ Αναστήλωση–Συντήρηση–Προστασία Μνημείων και Συνόλων* 1, Athens, pp. 261–278.

———. 1987. *Corinthia,* Athens.

Corinth = *Corinth: Results of Excavations Conducted by the American School of Classical Studies at Athens*

III.2 = R. Carpenter and A. Bon, *The Defenses of Acrocorinth and the Lower Town,* Cambridge, Mass., 1936.

VI = K. M. Edwards, *Coins: 1896–1929,* Cambridge, Mass., 1933.

XI = C. H. Morgan II, *The Byzantine Pottery,* Cambridge, Mass., 1942.

XII = G. R. Davidson, *The Minor Objects,* Princeton 1952.

XIV = C. Roebuck, *The Asklepieion and Lerna,* Princeton 1951.

XX = C. K. Williams II and N. Bookidis, eds., *Corinth, the Centenary: 1896–1996,* Princeton 2003.

Danforth, L. M. 1982. *The Death Rituals of Rural Greece,* Princeton.

DOC 4.1 = M. F. Hendy, *Catalogue of the Byzantine Coins in the Dumbarton Oaks Collection and in the Whittemore Collection* 4.1: *Alexius I to Michael VIII, 1081–1261,* Washington, D.C., 1999.

Eakins, J. K., ed. 1993. *Tell el-Hesi* 5: *The Muslim Cemetery in Fields V and VI/IX (Stratum II),* Winona Lake, Ind.

Faroqhi, S. 1999. *Approaching Ottoman History: An Introduction to the Sources,* Cambridge.

———. 2000. *Subjects of the Sultan: Culture and Daily Life in the Ottoman Empire,* London.

Forbes, H. 2000. "Security and Settlement in the Medieval and Post-Medieval Peloponnese, Greece: 'Hard' History versus Oral History," *JMA* 13, pp. 202–224.

Gorlin, R. J., J. J. Pinborg, and M. M. Cohen Jr., eds. 1976. *Syndromes of the Head and Neck,* 2nd ed., New York.

Greene, M. 2000. *A Shared World: Christians and Muslims in the Early Modern Mediterranean,* Princeton.

İnalcık, H. 1993. *The Middle East and the Balkans under the Ottoman Empire: Essays on Economy and Society,* Bloomington.

Insoll, T. 1999. *The Archaeology of Islam,* Oxford.

Isthmia V = T. E. Gregory, *The Hexamilion and the Fortress* (*Isthmia* V), Princeton 1993.

Jennings, R. C. 1999. *Studies on Ottoman Social History in the Sixteenth and Seventeenth Centuries: Women, Zimmis, and Sharia Courts in Kayseri, Cyprus, and Trabzon* (Analecta Isisiana 39), Istanbul.

Kasdagli, A.-M. 1999. "Nuremberg and Other Reckoning Counters Found in Rhodes," *NomChron* 18, pp. 119–132 (in Greek and English).

Krogman, W. M. 1962. *The Human Skeleton in Forensic Medicine,* Springfield, Ill.

Kuniholm, P. I. 2000. "Dendrochronologically Dated Ottoman Monuments," in Baram and Carroll 2000a, pp. 93–136.

Kurtz, D. C., and J. Boardman. 1971. *Greek Burial Customs,* Ithaca.

Lazaridis, D., K. Romiopoulou, and Y. Touratsoglou. 1992. *Ο τύμβος της Νικήσιανης* (Βιβλιοθήκη της εν Αθήναις Αρχαιολογικής Εταιρείας 121), Athens.

LRBC = R. A. G. Carson, P. V. Hill, and J. P. C. Kent, *Late Roman Bronze Coinage, A.D. 324–498,* London 1960.

Ludwig, J. 1972. *Current Methods of Autopsy Practice,* Philadelphia.

Mac Isaac, J. D. 1975, "The Hand of God: A Numismatic Study," *Traditio* 31, pp. 319–328.

MacKay, P. A. 1967. "The Fountain at Hadji Mustapha," *Hesperia* 36, pp. 193–195.

———. 1968. "Acrocorinth in 1668: A Turkish Account," *Hesperia* 37, pp. 386–397.

———. n.d. *The Travel Journal of Evliya Çelebi* 8: *Travels in Mainland Greece* (unpublished translation).

Marks, A. E., Y. E. Demidenko, K. Monigal, V. I. Usik, C. R. Ferring, A. Burke, J. Rink, and C. McKinney. 1997. "Starosele and the Starosele Child: New Excavations, New Results," *CurrAnthr* 38, pp. 112–123.

Metcalf, D. M. 1995. *Coinage of the Crusades and the Latin East in the Ashmolean Museum* (Royal Numismatic Society, Special Publication 28), 2nd ed., London.

Mitchiner, M. 1988. *Jetons, Medalets, and Tokens* 1: *The Medieval Period and Nuremberg,* London.

Neuchâtel Colloquium = *Trouvailles monétaires de tombes. Actes du deuxième colloque international du Groupe suisse pour l'étude des trouvailles monétaires, Neuchâtel, 3–4 mars 1995,* ed. O. F. Dubuis, S. Frey-Kupper, and G. Perret, Lausanne 1999.

Panayiotopoulos, V. 1985. *Πληθυσμός και οικισμοί της Πελοποννήσου: 13ος–18ος αιώνας,* Athens.

Papadopoli, N. 1919. *Le monete di Venezia* 3, Milan.

Pere, N. 1968. *Osmanlılarda madeni paralar,* Istanbul.

Pouqueville, F.-C.-H.-L. 1826. *Voyage de la Grèce,* Paris.

Price, M. J. 1967. "Greek Bronze Coinage ca. 450–150 B.C.: Its Introduction, Circulation, and Value, with

This content downloaded from 78.100.65.226 on Fri, 11 Oct 2013 01:17:53 AM
All use subject to JSTOR Terms and Conditions

Particular Reference to the Series of Corinth" (diss. Univ. of Cambridge).
Robinson, H. S. 1962. "Excavations at Corinth, 1960," *Hesperia* 31, pp. 95–133.
———. 1976. "Excavations at Corinth: Temple Hill, 1968–1972," *Hesperia* 45, pp. 203–239.
Robinson, R. 1985. "Tobacco Pipes of Corinth and of the Athenian Agora," *Hesperia* 54, pp. 149–203.
Rogers, S. L. 1984. *The Human Skull: Its Mechanics, Measurements, and Variations,* Springfeld, Ill.
Rush, A. C. 1941. *Death and Burial in Christian Antiquity,* Washington, D.C.
Sanders, G. D. R. 1999. "A Late Roman Bath at Corinth: Excavations in the Panayia Field, 1995–1996," *Hesperia* 68, pp. 441–480.
———. 2001. "Corinth Excavations Focus on Panayia Field," *ASCSA Newsletter* 45, pp. 1, 5.
———. 2005. "Archaeological Evidence for Early Christianity and the End of Hellenic Religion in Corinth," in *Urban Religion in Roman Corinth: Interdisciplinary Approaches* (Harvard Theological Studies 53), ed. D. N. Schowalter and S. J. Friesen, Cambridge, Mass., pp. 419–442.
Spitz, W. U., and R. S. Fisher, eds. 1993. *Medicolegal Investigation of Death: Guidelines for the Application of Pathology to Crime Investigation,* Springfield, Ill.
Sultan, J. 1977. *Coins of the Ottoman Empire and the Turkish Republic: A Detailed Catalogue of the Jem Sultan Collection,* Thousand Oaks, Calif.
Toombs, L. E. 1985. *Tell el-Hesi: Modern Military Trenching and Muslim Cemetery in Field I, Strata I–II,* Winona Lake, Ind.
Trotter, M., and G. C. Gleser. 1952. "Estimation of Stature from Long Bones of American Whites and Negroes," *American Journal of Physical Anthropology* 10, pp. 463–514.
———. 1958. "A Re-evaluation of Estimation of Stature Based on Measurements Taken during Life and of Long Bones after Death," *American Journal of Physical Anthropology* 16, pp. 79–123.
Tselekas, P. 1996. "Grave Hoards of Greek Coins from Greece," *NC* 156, pp. 249–259.
Ubelaker, D. H. 1978. *Human Skeletal Remains: Excavation, Analysis, Interpretation* (Aldine Manuals on Archeology), Chicago.
Vin, J. P. A. van der. 1980. *Travellers to Greece and Constantinople: Ancient Monuments and Old Traditions in Medieval Travellers' Tales,* Leiden.
Weinberg, E. D. 1992. "Iron Withholding in Prevention of Disease," in *Diet, Demography, and Disease: Changing Perspectives on Anemia* (Foundations of Human Behavior), ed. P. Stuart-Macadam and S. Kent, New York, pp. 105–150.
Wheler, G. 1682. *A Journey into Greece,* London.
Williams, C. K., II, and O. H. Zervos. 1990. "Excavations at Corinth, 1989: The Temenos of Temple E," *Hesperia* 59, pp. 325–369.
———. 1991. "Corinth, 1990: Southeast Corner of Temenos E," *Hesperia* 60, pp. 1–58.
———. 1992. "Frankish Corinth, 1991," *Hesperia* 61, pp. 133–191.
Wilski, H. 1993. "The Agiasos Hoard," *NomChron* 12, pp. 45–66 (in Greek and English).
Woodhouse, C. M. 1991. *Modern Greece: A Short History,* 5th ed., rev., London.

Arthur H. Rohn

American School of Classical Studies at Athens
Corinth Excavations
54 Souidias Street
106 76 Athens
Greece

ahrohn@hotmail.com

Guy D. R. Sanders

American School of Classical Studies at Athens
Corinth Excavations
54 Souidias Street
106 76 Athens
Greece

gsanders.corinth@ascsa.edu.gr

Ethne Barnes

American School of Classical Studies at Athens
Corinth Excavations
54 Souidias Street
106 76 Athens
Greece

ethnebarnes@hotmail.com

This content downloaded from 78.100.65.226 on Fri, 11 Oct 2013 01:17:53 AM
All use subject to JSTOR Terms and Conditions