# HOW CAN THE BELT RECIPE IN ESTILL VOICE METHOD BE USED FOR FEMALE LEARNERS AGED 7-12?

Word Count: 4121

Gloria Chu
Student ID: 2326948

# Table of Contents

**Introduction** ..... 2
**Belt Recipe** ..... 2
True Vocal Folds (TVF) and True Vocal Folds Body Cover ..... 3
False Vocal Folds ..... 4
Thyroid Cartilage ..... 4
Cricoid Cartilage ..... 5
Aryepiglottic Sphincter ..... 5
Larynx ..... 5
Tongue ..... 6
Velum ..... 7
Jaw and Lips ..... 8
Head, Neck and Torso ..... 8
Strategies ..... 10
**Reflection** ..... 10
**Conclusion** ..... 12
**Reference** ..... 13
**Appendix A: Definition of the Voice Production Structures and Options** ..... 28
**Appendix B: Personal Development Plan** ..... 39
**Appendix C: Why the Estill Voice Method (EVM) for belting?** ..... 42
**Appendix D: Reflection on learning the EVM figures based on Borton's Reflective Model** ..... 43
**Appendix E: The undefined Thyroid Cartilage** ..... 44
**Appendix F: Controversy of the Cricoid Cartilage** ..... 45

## Introduction

I am a vocal instructor with a Western classical (classical) trained background. For the past 20 years, I have taught female students aged 7-12 years, continuing to appreciate Western Classical music. However, I noticed many of my students would be singing popular repertoire imitating the belt tones from contemporary artists. My teaching value is to inspire students to confidently express their unique voice in music that connects to them personally. Even though my past exposure is from a paradigm of classical pedagogy, through this paper I challenge myself to explore the element of belting in Contemporary Commercial Music (CCM) (Lovetri and Weekly, 2003). Belting, an outgrowth of energized speech (Spivey, 2008), has become an accepted standard in contemporary pop music (Lebowitz and Baken, 2011) and a frequent challenge I see in my students. Belting is a potential health concern as misuse of the vocal instrument can contribute to the development of vocal nodules which grows in the vocal folds (Mudd and Noelke, 2018). This is a result of frictional trauma between the folds through inappropriate use of the voice (Kiliç et al, 2004). Thus, developing the knowledge of exercises and approach to belting with a healthy approach is deemed necessary in my practice as a vocal teacher. The purpose of this paper is to investigate the mechanisms required to guide students to belt safely for vocal health. This paper further clarifies the definition of belting in the Estill Voice Method (EVM) and compares the recipe with other scientific and pedagogical literature to conclude on an appropriate strategy for teaching CCM to females in this age group. A reflection from the review of literature materials will be conducted to conclude on a strategy of how the belt recipe in EVM can be used for female ages 7-12 learners.

## Belt Recipe

The EVM method was chosen based on its healthy development of vocal skills based on scientific understanding and isolating specific structures in the vocal mechanisms (Appendix C). EVM has been used in clinical settings (Lombard and Steinhauer, 2007) and in voice therapy (Tellis, 2018), supporting it is a healthy vocal method choice. EVM defines the belt quality with the figure options outlined in Figure 1. The following discussion will analyze the EVM figures and compare them to other pedagogues and scientific literature to conclude how the figure can be used for age 7-12 female learners.

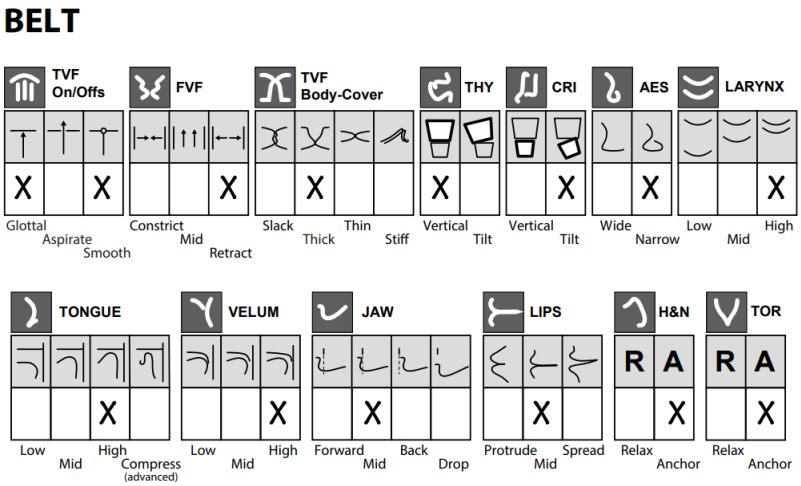


*Figure 1: Belt receipt from p.67 Estill et al, 2019. Definitions for the terms and abbreviations are included in Appendix A.*

<u>True Vocal Folds (TVF) and True Vocal Folds Body Cover</u>

Several studies concluded belting has high subglottal pressure (Sundberg and Thalén, 2015) and more glottal adductive forces (Stathopoulos and Sapienza, 1993). This is consistent with the findings of Estill and associates (1983). Subglottal pressure is defined as an important force in vowel production and is a primary variable in vocal intensity in both Western Classical and CCM (Fant, 1982; Björkner, 2008). The higher subglottal pressure causes the TVFs to close together more firmly (Herbst et al, 2015). This scientific literature supports Estill's figure in encouraging a glottal onset, which increases the subglottal pressure, with the TVFs (Estill, et al, 2019). This higher pressure pushes the TFVs more firmly together (Herbst et al, 2015). In the untrained voice, incomplete glottal closure is commonly seen in females (Södersten, Hertegård and Hammarberg, 1995) and children (Patel, et al, 2012). TVFs in children are thinner due to the underdeveloped layer of superficial lamina propria (SLP) which is not seen until age 12 (Hartnick, Rehbar and Prasad, 2005). The less developed SLP reduces control of the TVF. In addition, there are elastin and collagen groupings in the TVFs of children which can clump inconsistently thus impacting the seal of the glottis (Nita et al, 2009). These characteristics contribute to the common breathy tone in the untrained children's voice (Nita et al, 2009).

Using Schon's Reflective Practice Model (1983), the reflection on action made me aware of the reasoning behind the breathy timbre I often hear in my students – the TVFs were not completely closed. My action point to take away from this is the application of glottal onset exercises outlined by Estill (2019). However, I am cautious to balance the exercises without overloading the body. In addition, frequent hydration will be beneficial as it can promote optimal

biomechanical balance for efficient vocal fold oscillation during phonation (Tanner et al, 2007). In addition, females are more prone to vocal fatigue more often than males (Russell, Oates, and Greenwood, 1998). Singing warmups have been seen to prevent or delay vocal fatigue (Milbrath and Solomon, 2003). Warmup exercises focusing on a descending melodic pattern, singing softly as possible and singing various pitches and volumes and vowels are seen to be effective in reducing vocal fatigue (Elliot, Sundberg and Gramming, 1995).

## False Vocal Folds

False vocal folds are assigned a retracted state in the Estill figure (Appendix A). This outward open position of the false vocal folds allows for TVFs to vibrate more freely (Zheng et al, 2009). According to Zenker and Zenker (1960), belting is associated with a widening of the glottis. A retracted false vocal fold describes this widening as found by Estill and colleagues (Yanagisawa et al., 1989). The retracted state opens up the laryngeal space therefore allowing for increased space in the larynx for enhanced richness and depth of sound (Agarwal, Scherer and Hollien, 2003). The larger resonant cavity favors the lower frequencies and result in a warmer tone (Titze, Worley and Story, 2011). It is important to note over-retract as it can result in tension and strain in the larynx. Children's false vocal folds are more pliable and less dense (Boudoux, 2009). This allows for easier adjustments of the vocal tract and leads to a wider range of pitch (Schneider et al, 2010). However, due to the pliability resonance and richness are impacted and may be lighter and lack the depth heard in adults (Fiadjoe et al, 2019). There is limited research on the false vocal folds (Agarwal, Scherer and Hollien, 2003), but based on the above understandings, I need to be mindful of not demanding a more resonant depth in my students, understanding the false vocal folds have different tissue compositions. I can refer to other figures such as the jaw and lips oral cavity to be adjusted to help achieve greater resonance and depth if required.

## Thyroid Cartilage

The thyroid cartilage in children is less developed in the age group focused in this paper (Appendix E). The muscles coordinating the angle change from any position may not be fully developed (Glickson et al, 2017). This is further supported by Sapienza, Ruddy and Baker (2004) where no vertical laryngeal prominence was seen in the thyroid cartilage until age 10-14. The undefined change of angle in the thyroid cartilage in age 7-12 learners' results in this figure not being applicable to all singers in this learning grouping for the purpose of belting.

Cricoid Cartilage

Since Estill's initial research (1983) of the cricoid cartilage, more recent studies presented (Appendix F) have concluded the cricoid cartilage does not move for the purpose of belting as it does not contain muscles (Mathews and Jain, 2023). For this reason, this figure is not applicable for the purpose of this paper.

Aryepiglottic Sphincter

Both twang and belting voice quality in EVM includes the narrowing of the aryepiglottic sphincter (AES) (Estill et al., 2019). For this discussion, research on the twang quality will also be referenced in understanding the AES narrowing in the EVM belt recipe. Although specific studies on the narrow AES in belting might not be widely published as standalone research, the broader literature in vocal pedagogy (Miller, 1996; Estill et al., 2019), acoustic analysis (Sataloff, 2017), and voice science (Sundberg and Thalén, 2010) provides valuable insights of how AES adjustment influences vocal production in belting. Estill observed the AES narrows in belting (Yanagisawa, Estill, Kmucha, and Leder, 1989) while others have observed a reduction in the pharyngeal area (Perta, Bae, and Obert, 2021). When the narrowing of the AES occurs, there is greater subglottic pressure as a result of the TFVs staying closed for a longer period of time compared to an open AES (Lott, 2014; Estill et al., 2019). Titze and associates (2003) confirmed in a twang study that the true vocal folds have an increased closure period and observed a narrowing of the pharyngeal area. Source analysis of the fundamentals also revealed a higher degree of true vocal fold closure in twang (Sundberg and Thalén, 2010).

In children, the AES may be relatively larger in proportion to the rest of the larynx compared to adults (Orenstein, 2006). The larger AES increases the overall size of the airway above the vocal folds resulting in a more resonant space. In addition, the position of the larynx is higher in children and impacts the positioning of the AES resulting in it not closing properly (Sapienza, Ruddy and Baker, 2004; Westhorpe, 1987). This in turn will impact airflow and may cause force on the vocal folds leading to vocal fatigue (Orenstein, 2006). Thus, when teaching children this figure I have added extra precaution to not over use the AES as it is prone to problems if worked too hard in singing (Trollinger, 2005).

Larynx

A raised larynx in a belt voice is agreed by EVM, scientists and pedagogues (Estill, 1988; Sunderg, Gramming and Lovetri, 1993; Saldias et al, 2019). Titze (2007) and McCoy (2007) acknowledges this feature is advantageous as all formant frequency increases in

resonance when the vocal tract is shortened as in the case of the raised larynx. McCoy (2007) argues the larynx is not in the raised position but rather neutral location. This neutral position combined with the speech-like quality of singing allows the belt quality to be natural and unique to each singer's voice (White, 2011). Regardless of the raised larynx or neutral larynx, compared to classical singing the vocal tract is shorter elevating the acoustic signals (White, 2011). This contributes to the brassy quality some describe belting (Estill, et al, 2019).

Although some suggest vocal ligament is unidentifiable in children's larynxes until the age of 8 years old (Hirano, 1981); we know this is not true since children under the age of 8 can create sound with their voice box. The size of the larynx is smaller hence the volume on a belt tone may be limited by the size of the current larynx (Williams, 2013). The size of the larynx grows in size dependent on the age (Glikson et al, 2017). It is important to note children's larynx are positioned higher than in adults ( Holzki et al, 2018). The natural higher position of children lends itself to shorter vocal folds; the belt recipe of an even higher larynx will further shorten the vocal fold (Sapienza et al, 2004). It is important to be aware that too high of a larynx will result in overly tight vocal folds which are difficult to fully close since they are more rigid. This can be heard through with a breathier tone. Furthermore, it is cautioned the raised larynx can crowd the hyoid bone, tongue, and jaw (Titze, 2007). Thus, for children a sensitive approach to belting needs to be conducted to ensure a healthy development of the voice without overuse and development of nodules (Karali et al, 2022). Adjustment to this figure for young learners may be such that minimal alterations are required for a high larynx since children have a naturally high larynx. If movement is to be done, only a small amount should be raised to prevent crowding and incomplete closure of the vocal folds.

Tongue

EVM and other researchers agree a higher and more forward tongue position than classical singing is promoted in belting (Estill, 1988; Balog, 2005; Burdick, 2015). A higher tongue position will increase the second formants (Lee, Shaiman, and Weismer 2016) which belting requires. For belting higher second formants, the tongue is to be more forward and the lips to be less rounded (Lee, Shaiman, and Weismer 2016). The high and forward tongue will result in a higher larynx (Hosbach-Cannon et al, 2020) which is also part of the EVM belt recipe.

In children, the tongue is proportionally larger compared to the oral cavity than in adults (Di Cicco, et al., 2021). With changes of oral and facial structural changes, the tongue's shape will change (Di Cicco, et al., 2021); hence I need to be mindful that tongue control may fluctuate based on the growing structural changes in students. The tongue is the main articulator in

singing (Miller and Schutte, 2019), with a larger tongue it is more challenging to articulate certain consonants and vowels clearly. In addition, this will impact the clarity of lyrics in singing (miller and Schutte, 2019). Furthermore, a larger tongue occupies more space in the oral cavity and reduces the available space for resonance (Hiiemae and Palmer, 2003). This will result in a dampening of the higher frequencies which are favored in belting. The larger tongue will enhance the warmer qualities of tone rather than the brightness often associated with belting. A high tongue position as described in this figure is possible for the researched age group; however, adjustments to the jaw may need to be made to accommodate the smaller space in the oral cavity.

Velum

The velum is the gateway to the nasal cavity and is capable of a range of motions (Seikel, Drumright, and Hudock, 2023). When the velum is raised, the passage to the nasal cavity is closed. The Estill figure in the belt promotes a high velum, focusing the sound to flow through the mouth only (Estill et al., 2019). This is agreed by some researchers as the nasal cavity has the effect of dampening the sound and reducing general amplitude therefore decreasing upper formant activity (Yanagisawa, Kmucha and Estill, 1990; Wolfe, Garnier and Smith, 2009). Thus, a high velum with minimal participation of the nasal cavity is preferred in belting. Contrastingly, some studies conclude nasality induces acoustic strength (McIver and Miller, 1996). It is important to emphasize majority of the studies reviewed are primarily focused on Western classical singing with the perception nasality is detrimental to the voice quality (McCoy, 2007); however, the usage of the microphone in CCM has challenged this approach (Lockheart, 2003). Sound amplification systems allow a singer to develop timbres that not only depend on the sound acoustics of the room (Lockheart, 2023).

In children, the velum is relatively larger and thicker in portion to the oral cavity compared to adults (Kotlarek et al., 2019). In addition, the velum is higher in the mouth (Kotlarek et al., 2019). This results in an extra bright tone but does limit the lower resonance of the voice. I have taken this information and reduced repertoire choices with lower ranges for young learners in developing belt. From this research, the chosen strategy is to still focus on a high velum for belting; however, only a slight raise of the velum will be needed as children already have a naturally higher velum.

Jaw and Lips

A megaphone mouth shape is the suggested starting point for belting (Bozeman, 2022, Estill, 1992). Research by Titze, Worley and Story (2011) have shown the megaphone mouth shape allows for the first formant to be high. Combining the figures of a raised larynx, lip spreading east and west can raise the first formant high in belting (Titze, Worley and Story, 2011). While other researchers define the megaphone mouth shape as having a long-dropped jaw (Titze, 2011; Sundberg, Thalén and Popeil, 2012), Estill describes in the belt recipe for a mid-jaw opening (Estill et al., 2019). EVM argues a big open jaw can lead to unnecessary tension and strain. The focus is on efficient vocal fold closure and other figures combined to support the belt tone (Estill et al., 2019).

Children's lower jaw tends to be more rounded in shape than adults to accommodate smaller primary teeth (Alshammari et al, 2022. Children aged 6-10 have shown a gradual increase in vertical jaw displacement and by age 10 chewing trajectories were seen to be similar to adults, which can infer the motions can resemble those of adults (Almotairy et al, 2018). Given the understanding children have a larger tongue (Di Cicco et al., 2021), a slightly further dropped jaw than Estill described will be preferred in belting to allow for a larger resonant space.

The recipe for the lips is to be in mid position in EVM (Estill et al, 2019). This condition allows for no further adjustments to the vocal folds as influenced by the lips. Saldias and colleagues (2019) did find wider lips are see in belt singers; however, the measurement was from the distance between the lower and upper lip which differs than Estill's discussion of the shape of the lips. The lips of children are often less distinct than in adults (Sharma, Arora and Valiathan, 2014). Through maturity the lips become fuller and facial features become more defined and the jaw elongates (Arora and Valiathan, 2014). Since the EVM recipe calls for mid shape of lips where the lips are not actively manipulating the vocal tract, less pronounced lips in children should not significantly impact the belt approach.

Head, Neck and Torso

An engaged head, neck, and torso position is part of the belt recipe. With the skeletal structures of these parts anchored the smaller muscles involved in the other figures is deemed to be easier with a stable external frame (Estill et al., 2019). The anchored position of the Estill figures relates to research on postural alignment discussed in pedagogical literature and studies. EVM does not explicitly focus on breathing; however indirectly through the anchored head, neck, and torso breathing is addressed through the alignment of the body. Components

of the torso including bones and muscles of the back, chest, shoulders, lungs, and abdominal muscle are involved in the process of breathing (Miller, 2002).

There is minimal research on the impact of head and neck engagement in singing. Continued review of literature discovered research by Turner and Kenny (2010) who supported torso movement in CCM. There were more toros movement detected on the peak notes than on quiet lower pitch notes. Although the research was not directly on belt tones, it can be interpreted belt notes will be more related to the described peak notes in the research. Similarly, Brander and colleagues (2020) detected torso movement with research on a classical singer. Thus, these research supports Estill's anchor engagement of the torso in the belt recipe.

The body of young learners are still developing and torso muscles may not have the same strength and endurance as adults. Dejanovic and colleagues (2012) showed the stamina of the torso in age 10 was more than those of age 7 in females. In addition, the torso size is smaller in children (Dejanovic, Harvey and McGill, 2012). This will impact singing as children have less stamina and require more frequent breaks when engaging the torso. Additional physical exercises can be done with the torso to strengthen the developing muscles to assist in anchoring for belt tone. While there continues to be a gap in current research on the engagement of the head and neck in singing, a similar strategy to torso development can be assumed.

Strategies

Based on the literature reviewed, Table 1 summarizes the strategies for each of the EVM figures in the belt recipe for female learners aged 7-12.

| Modifications of Estill Voice Method belt recipe for female learners aged 7-12 | | |
|---|---|---|
| **Estill Figure** | **Vocal Characteristic for female learners aged 7-12** | **Strategies** |
| True Vocal Folds and True Vocal Folds Body Cover | • vocal folds are thinner (Hartnick, Rehbar & Prasad, 2005) and shorter (Hirano, 1983) than in adults<br>• less development of superficial lamina propria (SLP) (Hartnick, Rehbar & Prasad, 2005)<br>• elastin and collagen groupings in vocal folds clumping inconsistently impacting seal of glottis (Nita et al, 2009)<br>• incomplete glottal closure is common (Sodersten, Hertegard & Hammarberg, 1995; Patel et al, 2012) | • warmup focusing on descending melody, quiet tones, wide range of pitches, vowels, loudness (Elliot, Sundberg & Gramming, 1995)<br>• additional hydration to keep vocal folds lubricated reducing friction (Tanner et al, 2007). |
| False Vocal Folds | • children false vocal folds are more pliable and less dense than adults (Boudoux, 2009) resulting in lighter tone (Wilson, 1953, Fiadjoe et al, 2019) | • mindful of the lightness in tone, refer to jaw and lips to favor depth in tone rather than adjustments of false vocal folds |
| Thyroid Cartilage | • children have smaller and less developed thyroid cartilage (Sapienza, Ruddy & Baker, 2004)<br>• thyroid cartilage changes shape from a cylindrical to funnel-shaped through maturity (Glickson et al, 2017)<br>• thyroid cartilage is not fully developed and no changes in motion is observed until age 10-14 (Sapienza, Ruddy & Baker, 2004) | • the undefined change of angle in the thyroid cartilage in age 7-12 learners resulting in this figure not being applicable to all singers in this learning grouping for the purpose of belting. |
| Cricoid Cartilage | • this cartilage does not contain muscles (Mathews & Jain, 2023) therefore cannot move | • not applicable for the purpose of this paper |
| Aryepiglottic Sphincter | • AES in children is larger in proportion to the rest of the larynx (Orenstein, 2006).<br>• AES is positioned higher in children resulting in it not closing properly (Sapienza, Ruddy & Baker, 2004; Westhorpe, 1987) | • vocal folds will be more fatigue thus frequent breaks and shorter practice sessions while engaging the AES is needed to avoid overusing the voice (Trollinger, 2005) |
| Larynx | • children's larynxes are in a higher position than adults (Sapienza et al, 2004; Holzki et al, 2018) | • minimal adjustment of the larynx required for belting as larynx is already in a high position |
| Tongue | • tongue size is larger in children (Di Cicco, et al., 2021) | • high tongue position is possible for this age group, however, adjustments to jaw will need to be made to accommodate for the larger tongue size while balancing suffice resonant space |
| Velum | • children have a relatively high and thick velum (Kotlarek et al., 2019). | • only small adjustment to a higher velum in belting as the velum is already in a high position for children |
| Jaw and Lips | • children have rounder lower jaws than in adults (Alshammari et al, 2022)<br>• children have less pronounced lips than adults (Subtelny, 1959; Nanda et al, 1990; Sharma, Arora & Valiathan, 2014) | • more dropped jaw to be adjusted for in this age group to accommodate for the larger tongue in children<br>• no adjustment of lips required for children as lips do not actively change the vocal tract in the EVM belt recipe |
| Head, Neck and Torso | • shorter torso in children (Dejanovic, Harvey and McGill, 2012)<br>• weaker torso muscle in young children (Dejanovic, Harvey and McGill, 2012) | • additional physical exercises for torso, head and neck to strengthen these developing muscles<br>• be aware of the need of frequent breaks with anchor engagement |

*Table 1: Modifications of EVM belt recipe for female learners aged 7-12*

## Reflection

The reflective model that immediately connected with me is Schon's Reflective Practice Model (1983) encompassing the concepts of reflection-in-action and reflection-on-action. This model encourages teachers to reflect on their practice during the act of teaching (reflection-in-action) and aftermath (reflection-on-action) (Edwards and Huntley, 2013). Reflection-in-action is when an individual thinks, reassess and modifies the approach in real time to achieve a better outcome (Edwards and Huntley, 2013; Schon, 1983). When an individual does an introspection and critical evaluation after an event reflection-on-action takes place (Edwards and Huntley, 2013). Upon reading more about this model I gained awareness and appreciation of the role of the unconscious proficiency that I execute while teaching, also known as knowing-in-action (Schon, 1983).

One of the important lessons I took from teaching the EVM figures is to avoid overloading students with the new knowledge I have learned. After researching the thirteen figures and seeing the benefits of how they can assist students with belting, I was tempted to tackle all figures in the next lesson with students. Through my reading I was reminded a teacher is the filter of knowledge (Keys, 2007) and it is my responsibility as a teacher to capture the essential information (Munby, Russell, and Martin, 2001) to guide the students to be successful in their intended goal at the precise moment. As a vocal teacher, the information I learn heavily impacts the curriculum and pathway of learning for the student (Keys, 2007). However, cognitive load theory suggests there is limited capacity in the working memory (Sweller, Merrienboer and Paas, 2019). Presentation of information in small digestible chunks can allow learners to process and retain the information (Skulmowski and Xu, 2022). Through the initial week of this learning journey, the majority of my lessons were carried out with knowing-in-action. I depended largely on my instincts to guide the strategies of how to interact and continue the lessons. Upon reading about Hollingsworth and Clarke (2017) and the significance of video as a tool for focusing on teacher self-reflection, I intend to conduct a detailed analysis of a recorded lesson to gain deeper insights as to my current level of reflection-in-action (Appendix B). From reflection-on-action of my teaching, I notice there are minimal moments of silence in my teaching. This is powerful information informing me that I did not take a moment to reflect-in-action during this lesson. Silence can be an indication of reflection-in-action occurrence (Andrade et al., 2019); in addition, engaging in reflective questions with the student can also be helpful (Hattie and Donoghue, 2016). As the EVM figures are a rather new concept for me to apply to my teaching, the review of the literature supports the importance of engaging in intentional reflection-in-action moments (Korthagen and Nuijten, 2022). I have placed sticky note reminders in my teaching area to pause and conduct reflection-in-action. Upon collecting data on my recorded video of lesson teaching I will have further insights as to how I can more actively include reflection-in-action in my lessons.

When conducting reflection-on-action, I now recognize my background as a violinist heavily impacted my strategies for coaching how the posture for students to enhance head, neck, and torso energy for vocal students. When a student was locked in the body and unable to engage with the torso, I defaulted to exercises from violin pedagogue Paul Rolland's bilateral motion (Kim and Fairbanks, 2024). Even though Rolland's bilateral motion focused more horizontally left and right, the motion engaged the body in an external pendulum swing, which then moved to a forward and backward motion. Then the final step of engaging a sense of internal engagement for the torso, neck, and head. My response during the lesson was also a

reflection-in-action, I was puzzled how to help my student's posture when working on the neck, head, and torso EVM figure (reflecting on the phenomenon). My experimentation was using Rolland's bilateral motion methods to engage in total body action in a relaxed manner. I now recognize this experimentation serves to generate both a new understanding of the EVM figure for me and changes the situation to result in a positive outcome (Schon, 1983). The action of linking my existing knowledge (Rolland's bilateral motion) and the new idea (EVM figure) is a widely accepted approach to conceptual learning (Scott, Mortimer, and Ametller, 2011). Appendix B will address my intended focus on going forward with these new reflective thoughts while Appendix D addresses my reflection on learning the EVM figures.

## Conclusion

A review of literature suggests several researchers supporting the EVM figures in the belt recipe. A glottal onset of the true vocal folds with thick body cover, retracted false vocal folds, vertical thyroid, narrow AES, high larynx, tongue and velum, mid open jaw, mid position of lips, and anchored head, neck, and torso. There is a controversial debate as to the tilt of the cricoid cartilage. Nonetheless, this belt recipe can be adaptable for age 7-12 female learners (Table 1). With the understanding the voice box is in the developmental stages, appropriate precautions can train the young voice to belt with a healthy approach. A personal development plan (Appendix B) summarizes the next action for me as a practitioner based on the research of this paper.

**Reference**

Agarwal, M., Scherer, R.C. and Hollien, H., 2003. The false vocal folds: shape and size in frontal view during phonation based on laminagraphic tracings. *Journal of Voice*, *17*(2), pp.97-113.

Almotairy, N., Kumar, A., Trulsson, M. and Grigoriadis, A., 2018. Development of the jaw sensorimotor control and chewing-a systematic review. *Physiology and behavior*, *194*, pp.456-465.

Alshammari, A., Almotairy, N., Kumar, A. and Grigoriadis, A., 2022. Effect of malocclusion on jaw motor function and chewing in children: a systematic review. *Clinical oral investigations*, *26*(3), pp.2335-2351.

Andrade, A.M., Castro, E.A.B.D., Brito, M.J.M., Braga, P.P. and SilvaYanagisawa, E., Estill, J., Kmucha, S.T. and Leder, S.B., 1989. , K.L., 2019. Nursing practice in home care: the mediation of care by reflexivity. *Revista Brasileira de Enfermagem*, *72*, pp.956-963.

Balog, J.A., 2005. A Guide to Evaluating Music Theater Singing for the Classical Teacher. *Journal of Singing*, *61*(4).

Bestebreurtje, M.E. and Schutte, H.K., 2000. Resonance strategies for the belting style: results of a single female subject study. *Journal of voice*, *14*(2), pp.194-204.

Bevan, R.V., 1989. *Belting and chest voice: Perceptual differences and spectral correlates*. Teachers College, Columbia University.

Björkner, E., 2008. Musical theater and opera singing—why so different? A study of subglottal pressure, voice source, and formant frequency characteristics. *Journal of Voice*, *22*(5), pp.533-540.

Boardman, S.D., 1987. *Voice training for the musical theater singer (Broadway)*. University of Cincinnati.

Boudoux, C., Leuin, S.C., Oh, W.Y., Suter, M.J., Desjardins, A.E., Vakoc, B.J., Bouma, B.E., Hartnick, C.J. and Tearney, G.J., 2009. Optical microscopy of the pediatric vocal fold. *Archives of Otolaryngology–Head and Neck Surgery*, *135*(1), pp.53-64.

Bourne, T. and Garnier, M., 2012. Physiological and acoustic characteristics of the female music theater voice. *The Journal of the Acoustical Society of America*, *131*(2), pp.1586-1594.

Bourne, T. and Kenny, D., 2016. Vocal qualities in music theater voice: perceptions of expert pedagogues. *Journal of voice*, *30*(1), pp.128-e1.

Bozeman, K., 2022. *Practical vocal acoustics: Pedagogic applications for teachers and singers*. Rowman and Littlefield.

Brandner, M., Blandin, R., Frank, M. and Sontacchi, A., 2020. A pilot study on the influence of mouth configuration and torso on singing voice directivity. *The Journal of the Acoustical Society of America*, *148*(3), pp.1169-1180.

Buder, E.H., 2005. The acoustics of nasality: Steps towards a bridge to source literature. *Perspectives on Speech Science and Orofacial Disorders*, *15*(1), pp.4-8.

Burdick, B., 2005. Vocal Techniques for Music Theater: The High School and Undergraduate Singer. *Journal of Singing*, *61*(3).

Cain, B.A., 1998. *Vocal abuse in singers: Causes, prevention, remedies and cures*. Northwestern University.

Chhetri, D.K. and Park, S.J., 2016. Interactions of subglottal pressure and neuromuscular activation on fundamental frequency and intensity. *The Laryngoscope*, *126*(5), pp.1123-1130.

Colton, R.H. and Estill, J., 1979. Perceptual aspects of some voice qualities. *The Journal of the Acoustical Society of America*, *65*(S1), pp.S115-S115.

Colton, R.H. and Estill, J.A., 1981. Elements of voice quality: perceptual, acoustic, and physiologic aspects. In *Speech and Language* (Vol. 5, pp. 311-403). Elsevier.

Dang, J., Wei, J., Honda, K. and Nakai, T., 2016. A study on transvelar coupling for non-nasalized sounds. *The Journal of the Acoustical Society of America*, *139*(1), pp.441-454.

Daugherty, J.F. and Brunkan, M.C., 2013. Monkey see, monkey do? The effect of nonverbal conductor lip rounding on visual and acoustic measures of singers' lip postures. *Journal of Research in Music Education*, *60*(4), pp.345-362.

Dejanovic, A., Harvey, E.P. and McGill, S.M., 2012. Changes in torso muscle endurance profiles in children aged 7 to 14 years: Reference values. *Archives of physical medicine and rehabilitation*, *93*(12), pp.2295-2301.

Di Cicco, M., Kantar, A., Masini, B., Nuzzi, G., Ragazzo, V. and Peroni, D., 2021. Structural and functional development in airways throughout childhood: Children are not small adults. *Pediatric Pulmonology*, *56*(1), pp.240-251.

Doscher, B.M., 1993. *The functional unity of the singing voice*. Scarecrow Press.

Edwards, J.A. and Huntley, R., 2013. Reflective practitioners for lifelong learning. In *Mentoring Mathematics Teachers* (pp. 184-197). Routledge.

Edwards, S., 2017. Reflecting differently. New dimensions: reflection-before-action and reflection-beyond-action. *International Practice Development Journal*, *7*(1).

Edwin, R., 1998. The Bach to rock connection: Belting 101. *Journal of Singing-The Official Journal of the National Association of Teachers of Singing*, *55*(1), pp.53-55.

Edwin, R., 2007. Belt is legit. *Journal of singing*, *64*(2), pp.213-215.

Elliot, N., Sundberg, J. and Gramming, P., 1995. What happens during vocal warm-up?. *Journal of Voice*, *9*(1), pp.37-44.

Estill, J. and Colton, R.H., 1979. The identification of some voice qualities. *The Journal of the Acoustical Society of America*, *65*(S1), pp.S115-S115.

Estill, J., 1988. Belting and classic voice quality: some physiological differences. *Medical problems of performing artists*, *3*(1), pp.37-43.

*Estill, J., 1992. Basic Figures and Exercise Manual. New York City, NY: Imagetech.*

*Estill, J., Baer, T., Honda, K. and Harris, K.S., 1983. Supralaryngeal activity in a study of six voice qualities. In Proc. Stockholm Music Acoustics Conference (pp. 157-174).*

Estill, J., Klimek, M., Obert, K., Steinhauer, K., 2019. Estill Voice Training Level one: Figures for Voice Control Workbook. *Estill Voice International.*

Fant, G., 1982. Preliminaries to analysis of the human voice source. *STL-QPSR*, *4*(1982), pp.1-28.

Fantini, M., Fussi, F., Crosetti, E. and Succo, G., 2017. Estill Voice Training and voice quality control in contemporary commercial singing: an exploratory study. *Logopedics Phoniatrics Vocology*, *42*(4), pp.146-152.

Fiadjoe, J.E., Litman, R.S., Serber, J.F., Stricker, P.A. and Coté, C.J., 2019. The pediatric airway. *A practice of anesthesia for infants and children*, pp.297-339.

Flynn, A., Trudeau, J. and Johnson, A.M., 2020. Acoustic comparison of lower and higher belt ranges in professional broadway actresses. *Journal of Voice*, *34*(3), pp.410-414.

Frič, M., Dobrovolná, A. and Andrade, P.A., 2024. Comparison of laryngoscopic, glottal and vibratory parameters among Estill qualities–Case study. *Biomedical Signal Processing and Control*, *87*, p.105366.

Fukuda, H., 1988. A new concept of lubricating mechanisms of the larynx. *Vocal Physiology: Voice Production, Mechanisms, and Functions*, pp.83-92.

Gateno, J., Alfi, D., Xia, J.J. and Teichgraeber, J.F., 2015. A geometric classification of jaw deformities. *Journal of Oral and Maxillofacial Surgery*, *73*(12), pp.S26-S31.

Glikson, E., Sagiv, D., Eyal, A., Wolf, M. and Primov-Fever, A., 2017. The anatomical evolution of the thyroid cartilage from childhood to adulthood: A computed tomography evaluation. *The Laryngoscope*, *127*(10), pp.E354-E358.

Hartnick, C.J., Rehbar, R. and Prasad, V., 2005. Development and maturation of the pediatric human vocal fold lamina propria. *The Laryngoscope*, *115*(1), pp.4-15.

Hattie, J.A. and Donoghue, G.M., 2016. Learning strategies: A synthesis and conceptual model. *npj Science of Learning*, *1*(1), pp.1-13.

Herbst, C.T., Hess, M., Müller, F., Švec, J.G. and Sundberg, J., 2015. Glottal adduction and subglottal pressure in singing. *Journal of Voice*, *29*(4), pp.391-402.

Herbst, C.T., Story, B.H. and Meyer, D., 2023. Acoustical theory of vowel modification strategies in belting. *Journal of Voice*.

Herbst, Christian T., Markus Hess, Frank Müller, Jan G. Švec, and Johan Sundberg. "Glottal adduction and subglottal pressure in singing." Journal of Voice 29, no. 4 (2015): 391-402.

Herseth, F., 2004. Female Chest Voice. *Journal of Singing*, *60*(4), pp.125-126.

Hiiemae, K.M. and Palmer, J.B., 2003. Tongue movements in feeding and speech. *Critical Reviews in Oral Biology and Medicine*, *14*(6), pp.413-429.

Hirano, M., 1974. Morphological structure of the vocal cord as a vibrator and its variations. *Folia phoniatrica et logopaedica*, *26*(2), pp.89-94.

Hirano, M., 1981. Structure of the vocal fold in normal and disease states anatomical and physical studies. *ASHA Rep*, *11*, pp.11-30.

Hirano, M., 1983. Growth, development, and aging of human vocal folds. *Vocal fold physiology*, pp.22-43.

Hirano, M., 1988. Vocal mechanisms in singing: laryngological and phoniatric aspects. *Journal of Voice*, *2*(1), pp.51-69.

Hollingsworth, H. and Clarke, D., 2017. Video as a tool for focusing teacher self-reflection: Supporting and provoking teacher learning. *Journal of Mathematics Teacher Education*, *20*(5), pp.457-475.

Holzki, J., Brown, K.A., Carroll, R.G. and Cote, C.J., 2018. The anatomy of the pediatric airway: Has our knowledge changed in 120 years? A review of historic and recent investigations of the anatomy of the pediatric larynx. *Pediatric Anesthesia*, *28*(1), pp.13-22.

Honda, K., 1995. Contributions of vocal tract shape to voice quality: MRI data and articulatory modeling. *Vocal Fold Physiology-Voice quality control-*, pp.23-38.

Hosbach-Cannon, C.J., Lowell, S.Y., Colton, R.H., Kelley, R.T. and Bao, X., 2020. Assessment of tongue position and laryngeal height in two professional voice populations. *Journal of Speech, Language, and Hearing Research*, *63*(1), pp.109-124.

Isaacson, G., 1990. Extraluminal arytenoid reconstruction: laryngeal framework surgery applied to a pediatric problem. *Annals of Otology, Rhinology and Laryngology*, *99*(8), pp.616-620.

Ishii, K., Akita, M., Yamashita, K. and Hirose, H., 2000. Age-related development of the arrangement of connective tissue fibers in the lamina propria of the human vocal fold. *Annals of Otology, Rhinology and Laryngology*, *109*(11), pp.1055-1064.

Isshiki, N., 1964. Regulatory mechanism of voice intensity variation. *Journal of speech and hearing research*, *7*(1), pp.17-29.

Karalı, F.S., Azizli, E., Tadihan-Özkan, E., Eskioğlu, E.İ., Sari, A. and Resuloglu, A., 2022. Voice therapy efficacy in pediatric professional voice users with vocal fold nodules: A preliminary study. *Journal of Voice*.

Keys, P.M., 2007. A knowledge filter model for observing and facilitating change in teachers' beliefs. *Journal of Educational Change*, *8*, pp.41-60.

Kim, M.J. and Fairbanks, S.T., 2024. Biomechanically Informed Bowing: Revisiting Rolland's Principles of Violin Playing. *String Research Journal*, *14*(1), pp.5-21.

Kiliç, M.A., Okur, E., Yildirim, I. and Güzelsoy, S., 2004. The prevalence of vocal fold nodules in school age children. *International Journal of Pediatric Otorhinolaryngology*, *68*(4), pp.409-412.

Kmucha, S.T., Yanagisawa, E. and Estill, J., 1990. Endolaryngeal changes during high-intensity phonation videolaryngoscopic observations. *Journal of Voice*, *4*(4), pp.346-354.

Korthagen, F. and Nuijten, E., 2022. *The power of reflection in teacher education and professional development: Strategies for in-depth teacher learning*. Routledge.

Kotby, M.N., Kirchner, J.A., Kahane, J.C., Basiouny, S.E. and El-Samaa, M., 1991. Histo-anatomical structure of the human laryngeal ventricle. *Acta oto-laryngologica*, *111*(2), pp.396-402.

Kotlarek, K.J., Haenssler, A.E., Hildebrand, K.E. and Perry, J.L., 2019. Morphological variation of the velum in children and adults using magnetic resonance imaging. *Imaging science in dentistry*, *49*(2), pp.153-158.

Lawrence, V., 1979. Laryngological observations on belting. *J Res Singing*, *2*(1), pp.26-8.

Leborgne, W.D. and Rosenberg, M.D., 2024. *The vocal athlete*. Plural Publishing.

LeBorgne, W.D., Lee, L., Stemple, J.C. and Bush, H., 2010. Perceptual findings on the broadway belt voice. *Journal of Voice*, *24*(6), pp.678-689.

Lebowitz, A. and Baken, R.J., 2011. Correlates of the belt voice: a broader examination. *Journal of Voice*, *25*(2), pp.159-165.

Lee, J., Shaiman, S. and Weismer, G., 2016. Relationship between tongue positions and formant frequencies in female speakers. *The Journal of the Acoustical Society of America*, *139*(1), pp.426-440.

Leydon, C., Sivasankar, M., Falciglia, D.L., Atkins, C. and Fisher, K.V., 2009. Vocal fold surface hydration: a review. *Journal of Voice*, *23*(6), pp.658-665.

Lindblom, B.E. and Sundberg, J.E., 1971. Acoustical consequences of lip, tongue, jaw, and larynx movement. *The Journal of the Acoustical Society of America*, *50*(4B), pp.1166-1179.

Lisser, H., 1911. Studies on the development of the human larynx. *American Journal of Anatomy*, *12*(1), pp.27-66.

Liu, S., Qi, W., Zhang, X. and Dong, Y., 2020. The development of the cricoid cartilage and its implications for the use of endotracheal tubes in the pediatric population. *Pediatric Anesthesia*, *30*(1), pp.63-68.

Lockheart, P., 2003. A history of early microphone singing, 1925–1939: American mainstream popular singing at the advent of electronic microphone amplification. *Popular music and society*, *26*(3), pp.367-385.

Lombard, L.E. and Steinhauer, K.M., 2007. A novel treatment for hypophonic voice: Twang therapy. *Journal of Voice*, *21*(3), pp.294-299.

Lott, J., 2014. The use of the twang technique in voice therapy. *Division 3 Newsletter*, *24*(3), pp.119-123.

LoVetri, J.L. and Weekly, E.M., 2003. Contemporary commercial music (CCM) survey: Who's teaching what in nonclassical music. *Journal of Voice*, *17*(2), pp.207-215.

Mathews, S. and Jain, S., 2023. Anatomy, head and neck, cricoid cartilage. In *StatPearls [Internet]*. StatPearls Publishing.

McIver, W. and Miller, R., 1996. A brief study of nasality in singing. *Journal of Singing-the Official Journal of the National Association of Teachers of Singing*, *52*(4), pp.21-26.

Meller, S.M., 1984. Functional anatomy of the larynx. *Otolaryngologic Clinics of North America*, *17*(1), pp.3-12.

Milbrath, R.L. and Solomon, N.P., 2003. Do vocal warm-up exercises alleviate vocal fatigue?.

Miles, B. and Hollien, H., 1990. Whither belting?. *Journal of Voice*, *4*(1), pp.64-70.

Miller, D.G. and Schutte, H.K., 2005. 'Mixing'the registers: Glottal source or vocal tract?. *Folia phoniatrica et logopaedica*, *57*(5-6), pp.278-291.

Miller, R. and Kornelis Schutte, H., 2019. The Effect of Tongue Position on Spectra in Singing. *Journal of Singing*, *76*(1).

Miller, R., 1996. *On the art of singing*. Oxford University Press, USA.

Miller, R., 2002. *National schools of singing: English, French, German, and Italian techniques of singing revisited*. Scarecrow Press.

Mudd, P. and Noelke, C., 2018. Vocal fold nodules in children. *Current opinion in otolaryngology and head and neck surgery*, *26*(6), pp.426-430.

Munby, H., Russell, T., and Martin, A. K., 2001. Teachers' knowledge and how it develops. *V. Richardson (Ed.), Handbook of research on teaching,* 5, pp. 877–904.

Nanda, R.S., Meng, H., Kapila, S. and Goorhuis, J., 1990. Growth changes in the soft tissue facial profile. *The Angle Orthodontist*, *60*(3), pp.177-190.

Neely, S., 2009. *Stop screaming! A practical guide for helping classically-trained singers achieve the "belt" sound in a healthy manner*. Southern Illinois University at Carbondale.

Nita, L.M., Battlehner, C.N., Ferreira, M.A., Imamura, R., Sennes, L.U., Caldini, E.G. and Tsuji, D.H., 2009. The presence of a vocal ligament in fetuses: a histochemical and ultrastructural study. *Journal of anatomy*, *215*(6), pp.692-697.

Orenstein, S.R., 2006. Oral, pharyngeal, and esophageal motor disorders in infants and children. *GI Motility online*.

Patel, R.R., Dixon, A., Richmond, A. and Donohue, K.D., 2012. Pediatric high speed digital imaging of vocal fold vibration: A normative pilot study of glottal closure and phase closure characteristics. *International Journal of Pediatric Otorhinolaryngology*, *76*(7), pp.954-959.

Perta, K., Bae, Y. and Obert, K., 2021. A pilot investigation of twang quality using magnetic resonance imaging. *Logopedics Phoniatrics Vocology*, *46*(2), pp.77-85.

Phillips, K.H., Williams, J. and Edwin, R., 2012. The young singer.

Piatnytska-Pozdnyakova, I., Korshunova, A. and Galaidin, A., 2022. ROLE AND FUNCTIONS OF THE TORSO IN THE PROCESS OF VOCALIZATION. *Scientific Journal of Polonia University*, *51*(2), pp.125-134.

Prakash, M. and Johnny, J.C., 2015. Whats special in a child's larynx?. *Journal of Pharmacy and Bioallied Sciences*, *7*(Suppl 1), pp.S55-S58.

Randestad, Å., Lindholm, C.E. and Fabian, P., 2000. Dimensions of the cricoid cartilage and the trachea. *The Laryngoscope*, *110*(11), pp.1957-1961.

Raghavendra, B.N., Horii, S.C., Reede, D.L., Rumancik, W.M., Persky, M.A. and Bergeron, T., 1987. Sonographic anatomy of the larynx, with particular reference to the vocal cords. *Journal of ultrasound in medicine*, *6*(5), pp.225-230.

Reid, C.L., 2002. *The modern singing master: essays in honor of Cornelius L. Reid*. Scarecrow Press.

Reidenbach, M.M., 1998. The muscular tissue of the vestibular folds of the larynx. *European archives of oto-rhino-laryngology*, *255*, pp.365-367.

Rogers, E., 2019. To belt or not to belt... that is the question. *Journal of Singing*, *76*(1), pp.57-59.

Roll, C., 2016. The evolution of the female broadway belt voice: implications for teachers and singers. *Journal of voice*, *30*(5), pp.639-e1.

Roll, C., 2016. The evolution of the female broadway belt voice: implications for teachers and singers. *Journal of voice*, *30*(5), pp.639-e1.

Ruhl, J., 1986. Is singing a dying art. *The NATS Journal*, *42*, pp.31-33.

Russell, A., Oates, J. and Greenwood, K.M., 1998. Prevalence of voice problems in teachers. *Journal of voice*, *12*(4), pp.467-479.

McCoy, S. 2007. A Classical Pedagogue Explores Belting. *Journal of Singing, 64(4).*

Saldias, M., Guzman, M., Miranda, G. and Laukkanen, A.M., 2019. A computerized tomography study of vocal tract setting in hyperfunctional dysphonia and in belting. *Journal of Voice*, *33*(4), pp.412-419.

Saldias, M., Guzman, M., Miranda, G. and Laukkanen, A.M., 2019. A computerized tomography study of vocal tract setting in hyperfunctional dysphonia and in belting. *Journal of Voice*, *33*(4), pp.412-419.

Sapienza, C.M., Ruddy, B.H. and Baker, S., 2004. Laryngeal structure and function in the pediatric larynx.

Sasaki, C.T., Young, N., Matsuzaki, H. and Paskhover, B., 2014. Anatomy of the human larynx. *Rubin JS, Sataloff RT, Korovin GS Diagnosis and Treatment of Voice Disorders*, *3*, pp.31-46.

Sataloff, R.T., 1992. The human voice. *Scientific American*, *267*(6), pp.108-115.

Sataloff, R.T., 2017. *Professional voice: the science and art of clinical care, 3-volume set*. Plural Publishing.

Saxon, K.G. and Schneider, C.M., 1995. Vocal exercise physiology.

Schneider, B., Zumtobel, M., Prettenhofer, W., Aichstill, B. and Jocher, W., 2010. Normative voice range profiles in vocally trained and untrained children aged between 7 and 10 years. *Journal of voice*, *24*(2), pp.153-160.

Schon, D., 1983. The Reflective Practitioner (New York, Basic Books).

Schutte, H.K. and Miller, D.G., 1993. Belting and pop, nonclassical approaches to the female middle voice: some preliminary considerations. *Journal of Voice*, *7*(2), pp.142-150.

Schutte, H.K., Stark, J.A. and Miller, D.G., 2003. Change in singing voice production, objectively measured. *Journal of Voice*, *17*(4), pp.495-501.

Scott, P., Mortimer, E. and Ametller, J., 2011. Pedagogical link-making: a fundamental aspect of teaching and learning scientific conceptual knowledge. *Studies in Science education*, *47*(1), pp.3-36.

Seikel, J.A., Drumright, D.G. and Hudock, D.J., 2023. *Anatomy and physiology for speech, language, and hearing*. Plural Publishing.

Sharma, P., Arora, A. and Valiathan, A., 2014. Age changes of jaws and soft tissue profile. *The Scientific World Journal*, *2014*(1), p.301501.

Skinner, M. and Mitchell, D. (2016) "'What? So What? Now What?': Applying Borton and Rolfe's Models of Reflexive Practice in Healthcare Contexts", *Health and Social Care Chaplaincy*, 4(1), pp. 10–19.

Skulmowski, A. and Xu, K.M., 2022. Understanding cognitive load in digital and online learning: A new perspective on extraneous cognitive load. *Educational psychology review*, *34*(1), pp.171-196.

Södersten, M., Hertegård, S. and Hammarberg, B., 1995. Glottal closure, transglottal airflow, and voice quality in healthy middle-aged women. *Journal of Voice*, *9*(2), pp.182-197.

Stathopoulos, E.T. and Sapienza, C., 1993. Respiratory and laryngeal measures of children during vocal intensity variation. *The Journal of the Acoustical Society of America*, *94*(5), pp.2531-2543.

Stone Jr, R.E., Cleveland, T.F. and Sundberg, P.J., 2003. Acoustic and aerodynamic characteristics of Country-Western, Operatic and Broadway singing styles compared to speech. *The Journal of the Acoustical Society of America*, *113*(4_Supplement), pp.2242-2243.

Story, B.H. and Titze, I.R., 1995. Voice simulation with a body-cover model of the vocal folds. *The Journal of the Acoustical Society of America*, *97*(2), pp.1249-1260.

Su, F., Wood, M. and Tribe, R., 2023. 'Dare to be silent': Re-conceptualising silence as a positive pedagogical approach in schools. *Research in Education*, *116*(1), pp.29-42.

Subtelny, J.D., 1959. A longitudinal study of soft tissue facial structures and their profile characteristics, defined in relation to underlying skeletal structures. *American Journal of Orthodontics*, *45*(7), pp.481-507.

Sullivan, J., 1985. *The Phenomena of the Belt/pop Voice: The Technique for Safely Producing the Vocal Sounds of Today*. Logos.

Sundberg, J. and Thalén, M., 2010. What is “twang”?. *Journal of voice*, *24*(6), pp.654-660.

Sundberg, J. and Thalén, M., 2015. Respiratory and acoustical differences between belt and neutral style of singing. *Journal of Voice*, *29*(4), pp.418-425.

Sundberg, J., 1977. The acoustics of the singing voice. *Scientific American*, *236*(3), pp.82-91.

Sundberg, J., 1987. The science of the singing voice (DeKalb, IL, Northern Illinois Press).

Sundberg, J., Gramming, P. and Lovetri, J., 1993. Comparisons of pharynx, source, formant, and pressure characteristics in operatic and musical theatre singing. *Journal of Voice*, *7*(4), pp.301-310.

Sundberg, J., Thalén, M. and Popeil, L., 2012. Substyles of belting: phonatory and resonatory characteristics. *Journal of Voice*, *26*(1), pp.44-50.

Sundberg, J., Thalén, M., Alku, P. and Vilkman, E., 2004. Estimating perceived phonatory pressedness in singing from flow glottograms. *Journal of Voice*, *18*(1), pp.56-62.

Sweller, J., Van Merrienboer, J.J. and Paas, F., 2019. Cognitive architecture and instructional design: 20 years later. *Educational psychology review*, *31*, pp.261-292.

Tanner, K., Roy, N., Merrill, R.M. and Elstad, M., 2007. The effects of three nebulized osmotic agents in the dry larynx.

Tanner, K., Roy, N., Merrill, R.M. and Power, D., 2005. Velopharyngeal port status during classical singing.

Tellis, C., 2018. New concepts in motor learning and training related to voice rehabilitation. *Perspectives of the ASHA Special Interest Groups*, *3*(3), pp.56-67.

Titze, I., 2011. Formant frequency shifts for classical and theater belt vowel modification. *Journal of Singing*, *67*(3), pp.311-312.

Titze, I.R. and Worley, A.S., 2009. Modeling source-filter interaction in belting and high-pitched operatic male singing. *The Journal of the Acoustical Society of America*, *126*(3), pp.1530-1540.

Titze, I.R., 1989. On the relation between subglottal pressure and fundamental frequency in phonation. *The Journal of the Acoustical Society of America*, *85*(2), pp.901-906.

Titze, I.R., 2007. Voice Research and Technology: Belting and a High Larynx Position. *Journal of Singing-The Official Journal of the National Association of Teachers of Singing*, *63*(5), pp.557-558.

Titze, I.R., Bergan, C.C., Hunter, E.J. and Story, B., 2003. Source and filter adjustments affecting the perception of the vocal qualities twang and yawn. *Logopedics Phoniatrics Vocology*, *28*(4), pp.147-155.

Titze, I.R., Worley, A.S. and Story, B.H., 2011. Source-vocal tract interaction in female operatic singing and theater belting. *Journal of Singing*, *67*(5), pp.561-572.

Trollinger, V., 2005. Performing arts medicine and music education: What do we really need to know?. *Music Educators Journal*, *92*(2), pp.42-48.

Trollinger, V., 2007. Pediatric vocal development and voice science: Implications for teaching singing. *General music today*, *20*(3), pp.19-25.

Tschan, S., Honegger, F. and Storck, C., 2016. Cricothyroid joint anatomy as a predicting factor for success of cricoid-thyroid approximation in transwomen. *The Laryngoscope*, *126*(6), pp.1380-1384.

Tschan, S., Honegger, F. and Storck, C., 2016. Cricothyroid joint anatomy as a predicting factor for success of cricoid-thyroid approximation in transwomen. *The Laryngoscope*, *126*(6), pp.1380-1384.

Turner, G. and Kenny, D.T., 2010. A preliminary investigation into the association between body movement patterns and dynamic variation in western contemporary popular singing. *Musicae Scientiae*, *14*(1), pp.143-164.

Unteregger, F., Honegger, F., Potthast, S., Zwicky, S., Schiwowa, J. and Storck, C., 2017. 3D analysis of the movements of the laryngeal cartilages during singing. *The Laryngoscope*, *127*(7), pp.1639-1643.

Unteregger, F., Thommen, J., Honegger, F., Potthast, S., Zwicky, S. and Storck, C., 2019. How age and frequency impact the thyroid cartilages of professional singers. *Journal of Voice*, *33*(3), pp.284-289.

Van den Berg, J.W., 1955. On the role of the laryngeal ventricle in voice production. *Folia Phoniatrica et Logopaedica*, *7*(2), pp.57-69.

Von Doersten, P.G., Izdebski, K., Ross, J.C. and Cruz, R.M., 1992. Ventricular dysphonia: a profile of 40 cases. *The Laryngoscope*, *102*(11), pp.1296-1301.

Ware, C., 1998. Basics of Vocal Pedagogy: The Foundations and Process of Singing.

Wendler, J., Seidner, W. and Eysholdt, U., 1998. Lehrbuch der Phoniatrie und Padaudiologie. *Logopedics Phoniatrics Vocology*, *23*(1), pp.44-46.

Westhorpe, R.N., 1987. The position of the larynx in children and its relationship to the ease of intubation. *Anaesthesia and intensive care*, *15*(4), pp.384-388.

White, A.R., 2011. Belting: As an Academic Discipline. *The American Music Teacher*, *60*(6), p.22.

Williams, J., 2010. *The implications of intensive singing training on the vocal health and development of boy choristers in an English cathedral choir* (Doctoral dissertation, University of London).

Williams, J., 2013. *Teaching singing to children and young adults*. Compton Pub.

Wilson, T.G., 1953. Some observations on the anatomy of the infantile larynx. *Acta Oto-laryngologica*, *43*(2-3), pp.95-99.

Wolfe, J., Garnier, M. and Smith, J., 2009. Vocal tract resonances in speech, singing, and playing musical instruments. *HFSP journal*, *3*(1), pp.6-23.

Yanagisawa, E., Estill, J., Kmucha, S.T. and Leder, S.B., 1989. The contribution of aryepiglottic constriction to “ringing” voice quality—a videolaryngoscopic study with acoustic analysis. *Journal of Voice*, *3*(4), pp.342-350.

Yanagisawa, E., Kmucha, S.T. and Estill, J., 1990. Role of the soft palate in laryngeal functions and selected voice qualities. *Annals of Otology, Rhinology and Laryngology*, *99*(1), pp.18-28.

Yanagisawa, E., Mambrino, L., Estill, J. and Talkin, D., 1991. Supraglottic contributions to pitch raising: videoendoscopic study with spectroanalysis. *Annals of Otology, Rhinology and Laryngology*, *100*(1), pp.19-30.

Young, A.H., 2003. *Singing professionally: studying singing for singers and actors*. Heinemann Drama.

Zenker, W. and Zenker, A., 1960. Über die Regelung der Stimmlippenspannung durch von außen eingreifende Mechanismen. *Folia Phoniatrica et Logopaedica*, *12*(1), pp.1-36.

Zheng, X., Bielamowicz, S., Luo, H. and Mittal, R., 2009. A computational study of the effect of false vocal folds on glottal flow and vocal fold vibration during phonation. *Annals of biomedical engineering*, *37*, pp.625-642.

## Appendix A: Definition of the Voice Production Structures and Options

There are three voice production structures defined in the Estill Voice Method (EVM): larynx structures, vocal tract structures and support structures. The EVM teaches 13 figures for voice control, through different combinations of the figures six voice qualities are produced (Estill, et al., 2019). Below is a rudimentary introduction to the 13 figures. Information is based on the Estill Voice Training Workbook one and two.

### Larynx Structures

Figure #1: True Vocal Folds (TVF)

**Anatomy and Physiology**

True vocal folds are muscle tissue located in the larynx which open and close in singing. The tension and length can be adjusted. The space between the true vocal folds is the glottis. The front of each vocal fold is attached to the thyroid cartilage and the back is attached to the arytenoid cartilages (Sundberg, 1977). The true vocal folds protect the lungs by preventing unwanted items entering the lungs (Sundberg, 1977); thus, the folds are closed when swallowing. As Sundberg (1977) describes in singing, true vocal folds play a role in sound production. During exhalation, air from the lungs create subglottic pressure, pressure below the closed vocal folds, which forces the folds apart (abduct). The air going through the folds result in a Bernoulli force which closes the true vocal folds (adduct). The cycle of abduct and adduct in the vocal folds results in vibration and sound waves. The tension of true vocal folds is impacted by the pressure, the higher the lung pressure and thinner and more stretched are the vocal folds.

**Options in the figure**

**The Three Options**

| Icon | Option & Description | Schematic | Hand Signal |
|---|---|---|---|
| 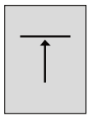 | **Glottal**<br>TVFs close (1) before exhalation begins (2) | 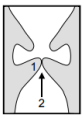 | |
| 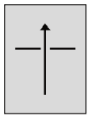 | **Aspirate:** *Abrupt, Gradual*<br>Exhalation begins (1) before TVFs close (2) *abruptly* or *gradually* | 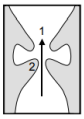 | |
| 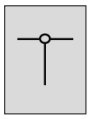 | **Smooth**<br>Exhalation and TVF movement occur *simultaneously* | 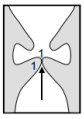 | |

*Figure 1: Options for True Vocal Folds (Estill, et al., 2019, p.26)*

Figure #2: False Vocal Folds (FVF)

**Anatomy and Physiology**

False vocal folds, also known as ventricular folds as wedge-shaped tissues above the true vocal folds (Meller,1984). There is controversy of the muscles involved in opening and closing the FVF, some argue the thyroarytenoid muscle (Raghavendra 1987; Von Doersten et al, 1992; Reidenbach, 1998) is engaged while others document the ventricularis muscle (Kotby et al, 1991). There is room for further scientific research in the specific muscle coordination of the FVF. Nonetheless, the FVF have been observed to adduct during phonation (Van den Berg, 1955). It is this movement of the FVF that Estill has adapted 3 positions in this figure (Figure 2).

The often-preferred state of the FVF is retraction in EVM. A retracted FVF allows for more air flow through the TVF which results in a louder tone. With the FVF in a retracted position, the TVF can come together more effectively for stronger closure (Agarwal, Scherer and Hollien, 2003).

**Options in the figure**

**The Three Options**

| Icon | Option & Description | Schematic | Hand Signal |
|---|---|---|---|
| 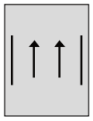 | **Mid**<br>The FVF position of comfortable speaking/ singing, mid-way between squeezed shut and widely opened. | 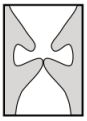 | |
| 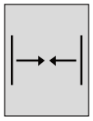 | **Constrict**<br>The condition when the FVFs are moved inward from Mid and toward their closed position. | 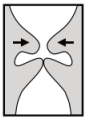 | |
| 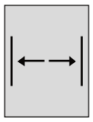 | **Retract**<br>The condition when the FVFs are moved outward from Mid to a widely opened position. | 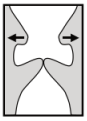 | |

*Figure 2: Options for False Vocal Folds (Estill, et al., 2019, p.35)*

Figure #3: True Vocal Folds Body-Cover

**Anatomy and Physiology**

The concept of body-cover model of fundamental frequency control was first hypothesized by Hirano (1974). The idea suggests there are two groups of tissue layers set into vibration by glottal airstream in the TVF (Hirano, 1974; Story and Titze, 1995). The two layers include the body, which are muscles and ligaments, and the cover, comprised of the skin and flexible soft tissue layer. The options in this figure trains the interplay between body and cover as the TVF changes length. The thickness and mass of body cover impact vibratory patterns of the TVF.

As seen above, subglottal pressure builds when the TVF are closed. When the TVF open, the subglottal air pressure drops and as a result the TVF vibrate making sound waves resonating in the vocal tract. The amount of TVF closure and the amount of time the TVF remain closed impacts the subglottal pressure. The subglottal pressure will directly relate to the amplitude of the sound wave. The more the pressure build up and drop off, the greater the amplitude of the sound waves.

**Options in the figure**

**The Four Options**

| Icon | Option & Description | Hand Signal |
|---|---|---|
| 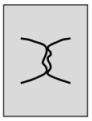 | **Slack**<br>Recognized as glottal fry, or creaky voice. Both body and cover are loose. This Body-Cover combination results in a unique vibratory pattern producing pulses of sound energy. | |
| 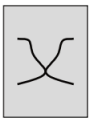 | **Thick**<br>Known as the modal or speech register. The true vocal folds are relatively short, with some contraction/muscle tone in the vocalis muscle within the body. The cover is pliant, and the folds ripple (mucosal wave) from the lower border to the upper border of the fold edge, with a *thick* depth of contact through the cycle. | |
| | **Thin**<br>May occur naturally at higher pitches where the true vocal folds are elongated, and/or during soft voicing. Less cover flexibility and/or less breath result in vibration without the lower-to-upper ripple, a *thin* or shallow depth of contact. | |
| | **Stiff**<br>May occur naturally at higher pitches. Associated with falsetto. The true vocal folds are elongated, pulled taut, and positioned slightly away from the midline. There is little or no contact during vibration. The tone may or may not be breathy. | |

*Figure 3: Options for True Vocal Folds: Body-Cover (Estill, et al., 2019, p. 42)*

Figure #4: Thyroid Cartilage

**Anatomy and Physiology**

At the cricothyroid joint, the thyroid cartilage and cricoid cartilage are connected. The thyroid cartilage is deemed to influence the TVF body cover. The tilt of the thyroid cartilage occurs when the TVF are adducted. When the thyroid cartilage tilts forward the TVF are stretched/elongated and increase in tension. This allows for quicker vibration. This results in a thinner body cover. When the thyroid cartilage is tilted backward is reduces tension in the vocal fold and leads to a thick body cover.

**Options in the figure**

**The Two Options**

| Icon | Option & Description | Schematic | Hand Signal |
|---|---|---|---|
| | **Vertical**<br>The condition of the thyroid cartilage in quiet breathing. | | |
| 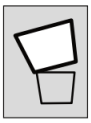 | **Tilt**<br>The condition when the cricothyroid muscle is actively engaged and the thyroid cartilage is rotating forward. | | |

*Figure 4: Options of Thyroid Cartilage (Estill, et al., 2019, p. 53)*

Figure #5: Cricoid Cartilage

**Anatomy and Physiology**

The cricoid cartilage is located at the bottom of the larynx below the thyroid cartilage. It is a ring shape around the airway. It is believed by Jo Estill that there was a tilt in the cricoid cartilage and the tilt impacted the TVF.

Options in the figure

**The Two Options**

| Icon | Option & Description | Schematic | Hand Signal |
|---|---|---|---|
| | **Vertical**<br>This is the condition during quiet breathing. | | |
| 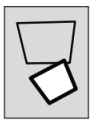 | **Tilt**<br>This is the condition during shouting. | | |

*Figure 5: Options of Cricoid Cartilage (Estill, et al., 2019, p.62).*

Figure #6: Aryepiglottic Sphincter (AES)

**Anatomy and Physiology**

The AES located at the entrance of the larynx above the false vocal folds. It can have the position of wide or narrow angle. A narrow AES produces a bright quality to the voice. Since the AES narrowing results in resonant frequency of the ear canal allowing the listener to perceive the sound to be louder. With this narrowing of the AES the vocal folds stay closed longer resulting in a higher subglottal air pressure and a more intense sound.

**Options in the figure**

**The Two Options**

| Icon | Option & Description | Schematic | Hand Signal |
|---|---|---|---|
| | **Wide**<br>This is the option where there is no brightness in the tone; the AES is Wide from front to back. | | |
| | **Narrow**<br>This is the option we have been experiencing in the "nyae-nyae's". | | |

*Figure 6: Options of AES (Estill, et al., 2019, p.66).*

**Vocal Tract Structures:**

Figure #7: Larynx

**Anatomy and Physiology**

The larynx is what Estill refers to as the voice box. The range of motion of the larynx is movement up and down. The muscles responsible for the change in height is the suprahyoid and infrahyoid muscles. The infrahyoid muscles lower the larynx, while the suprahyoid muscles lift the larynx. The engagement of these muscles alters the pharyngeal portion of the vocal tract. A higher larynx will shorten the pharynx, resulting in a more constrict lower part of the pharynx. By lowering the larynx, the pharynx walls will be stretched and there is a wider pharynx (Sundberg, 1987). The opposite occurs in a lower larynx where the pharynx will be lengthened.

**Options in the figure**

**The Three Options**

| Icon | Option & Description | Schematic | Hand Signal |
|---|---|---|---|
| | **Low**<br>This is the condition of the larynx at low pitches, and in the preparation to sob. | 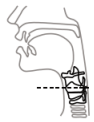 | |
| | **Mid**<br>This position should correspond to the position of the larynx during quiet breathing | | |
| | **High**<br>This is the condition of the larynx at high pitches, and in the preparation to scream or squeal. | | |

*Figure 7: Options of the larynx (Estill et al., 2019, p.72).*

Figure #8: Tongue

**Anatomy and Physiology**

There are many muscles in the tongue. The change in tongue shape impacts the articulation of the sound. The position of the tongue also affects the pitch by impacting the tension and length of the vocal folds. A forward tongue (towards the lips) will result in a shorten vocal tract therefore increasing the pitch and brightness of the tone. A backward tongue (towards the throat) will lengthen the vocal tract resulting in a lower pitch and darker tone quality. In addition, where the back of the tongue, called the dorsum, is higher, will result in a higher larynx and shorter vocal tract. When the dorsum is lowered, the vocal tract will be longer and result in a darker tone.

**Options in the figure**

**The Three Options**

| Icon | Option & Description | Schematic | Hand Signal |
|---|---|---|---|
| | **Low**<br>This is the low, flat tongue dorsum taught in some voice studios where a dark tone is the goal. | | |
| | **Mid**<br>The tongue dorsum is in the position it usually occupies during speech, assuming that you speak without a strong regional accent or voice quality. | | |
| | **High**<br>The dorsum and root of the tongue are lifted, as they are in the vowel / i / or in the / j / ("y"). | | |
| This fourth and advanced option is included here in the Level One Workbook, but will be taught in Level Two when Level One Figures are reviewed in preparation for Opera Quality. | | | |
|  | **Compress**<br>An option used in dramatic operatic singing. The tongue tip is curled up and pulled back, while the back of the tongue is pushed forward, compressing the tongue. | | |

*Figure 8: Options of the tongue (Estill et al., 2019, p.78).*

Figure #9: Velum

**Anatomy and Physiology**

The velum, soft palate, functions as the doorway between the oral and nasal cavity. The degree of opening to the entrance of the nose, velopharyngeal port, impacts the amount of resonance in the nose. Consonants /m/, /n/, and /ŋ/ mostly resonate in the nasal passage. Other sounds resonance in the oral cavity.

Options in the figure

**The Three Options**

| Icon | Option & Description | Schematic | Hand Signal |
|---|---|---|---|
| | **Low**<br>The velum is down, in contact with the back of the tongue.<br>The velopharyngeal port is all the way open.<br>The resonance is **nasal**. | |  |
| | **Mid**<br>The velum is lifted away from the tongue, but not high enough to close the velopharyngeal port completely.<br>The resonance is **nasalized**. | | 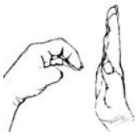 |
| | **High**<br>The velum is up all the way, in contact with the walls of the nasopharynx. The velopharyngeal port is completely closed.<br>The resonance is **oral**. | | |

*Figure 9: Options of the Velum (Estill et al, 2019, p.86)*

Figure #10: Jaw

**Anatomy and Physiology**

The temporo-mandibular joint (TMJ) allows for flexible movement of the jaw. The moments included side to side, forward and back, and up and down. Movement of the jaw influence pharyngeal space. A forward jaw elongates the vocal tract resulting in more resonance in sound and brighter tone. A jaw that is positioned back shortens the vocal trat resulting in less resonance and a duller tone. A dropped jaw position allows for larger vocal tract space, more resonance and a warmer tone.

**Options in the figure**

**The Four Options**

| Icon | Option & Description | Schematic |
|---|---|---|
| | **Forward**<br>In this condition, the chin is jutted forward, putting lower teeth and jaw ahead of the upper teeth. | 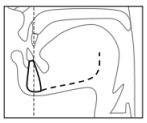 |
| | **Mid**<br>This is the alignment of a normal bite, with jaw slightly dropped. | 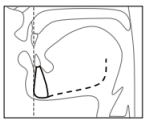 |
| | **Back**<br>The lower teeth are pulled back behind the upper teeth, pronounced "over-bite." | 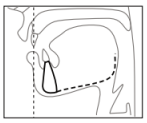 |
| 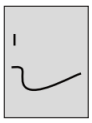 | **Drop**<br>This is the extreme "drop" of the jaw. | |

*Figure 10: Options for the jaw (Estill et al, 2019, p. 95)*

Figure #11: Lips

**Anatomy and Physiology**

The main muscle of the lips, orbicularis oris, is active for lip activity. Lips can be protruded, where the lips are extended forward from the face. The vocal tract is lengthened in this scenario favoring resonance of the lower notes. When the lips spread, similar to when smiling, the vocal tract is shortened strengthen the resonance of the higher notes.

**Options in the figure**

**The Three Options**

| Icon | Option & Description | Schematic |
|---|---|---|
| | **Protrude**<br>The lips extend forward of the face in this condition. | |
| | **Mid**<br>The lips are as they typically are in normal speech, "neutral," or "relaxed." | |
| | **Spread**<br>This is the condition of the broadest possible smile. | |

*Figure 11: Options for the lips (Estill et al, 2019, p.100).*

**Support Structures**

Figure #12: Head and Neck

**Anatomy and Physiology**

Estill strongly believed once the skeletal structures of the head and neck are anchored, the micro muscles that control the voice box can more easily adjust during singing. The smaller muscles do not have to work as hard with a stable external framework.

Options in the figure

**The Two Options**

| Icon | Option & Description | Schematic | Hand Signal |
|---|---|---|---|
| R | **Relax**<br>This is postural "resting" or neutral state. | | |
| A | **Anchor**<br>In this condition, muscles above the soft palate, to the sides of the neck, and in the occipital region are engaged. | | |

*Figure 12: Options for Head and Neck (Estill et al, 2019, p.106).*

Figure #13: Torso

**Anatomy and Physiology**

An anchored torso is described by Estill as a position that spreads the rib cage and lift the sternum slightly. The muscles are engaged (pectoralis major, quadratus lumborum and latissimus dorsi) to stabilize the spine and rib cage.

Options in the figure

**The Two Options**

| Icon | Option & Description | Schematic | Hand Signal |
|---|---|---|---|
| R | **Relax**<br>This is the condition assumed when sitting or standing in a comfortably upright posture: not slumping, and not straining to straighten up. | | |
| A | **Anchor**<br>When the Torso Anchor is engaged, the "pecs" and "lats" are contracted. The shoulders may pull down slightly; the sternum may lift. | 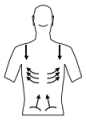 | |

*Figure 13: Options for the torso (Estill et al, 2019, p.112).*

## Appendix B: Personal Development Plan

### Develop Network and Professional Skills

My local music community knows me mostly as a pianist with some recognition in strings. I need to make an effort to let people know of my expertise in vocal pedagogy to expand on future opportunities to grow professionally as a vocal pedagogue. Below activities are designed with the intention to reach out to the music community while expanding on professional skills.

| | |
|---|---|
| **Activity** | Pursue Publication |
| **Objective** | To practice my academic writing skills and reach out to the music community about my expertise as a vocal teacher. |
| **Action 1** | Submit 1 article to local community Alberta Registered Music Teachers' Association (ARMTA) annual *Tempo* Magazine. |
| **Target Date(s)** | Submit 1 article by July 15, 2025 for September publication. |
| **Action 2** | Submit 1 article to local community Alberta Piano Teachers Association (APTA) News and Views Newsletter with a focus on how vocal ideas can impact piano playing. |
| **Target Date(s)** | Submit 1 article for one of the following issues:<br>- Winter issue – October 31, 2024<br>- Spring Issue – January 31st, 2025<br>- Summer issue – April 30, 2025<br>- Fall issue – July 31st, 2025 |
| **Action 3** | Submit 1 article to local community Alberta Registered Music Teachers' Association (ARMTA) quarterly *Impromptu* for each issue of the newsletter. |
| **Target Date(s)** | Submit 1 article by December 31, 2024 for February 2025 issue or July 31, 2025 for September 2025 issue. |

| | |
|---|---|
| **Activity** | Adjudication |
| **Objective** | To reach out to surrounding areas informing festivals of my interest to adjudicate and expertise in voice. |
| **Action 1** | Contact chairperson of Contemporary Showcase Calgary festival with my resume and let her know of my interest to adjudicate in Contemporary Showcase festivals throughout Canada, inquire her as to who best to share my resume with for this opportunity. |
| **Target Date(s)** | Updated resume completed by October 26, 2024.<br>Send out email to chairperson by October 30, 2024. |

**Develop Voice Specific Skills**

Development of a more comprehensive understanding in the Estill figures and their application in Contemporary Commercial Music (CCM) will be important for my intended expansion of vocal coaching into popular music with my students. In addition to including the figures into my daily teaching, below are activities designed with the purpose to gain deeper understanding of the Estill figures and mindful application of the new knowledge.

| | |
|---|---|
| **Activity** | Estill Figure Proficiency (EFP) Level |
| **Objective** | To learn and understand application of the EVM figures with formal training and coaching. |
| **Action 1** | Register for Level 1 and Level 2 Estill Course. |
| **Target Date(s)** | Register for October 26, 2024 – October 29, 2024 Level 1 and 2 Course by October 15, 2024. |
| **Action 2** | Attend practice group Sessions to prepare for EFP Certification. |
| **Target Date(s)** | Aim for EFP Certification test August 30, 2025. |
| **Action 2** | Contact Estill Mentor for mentorship in preparation of EFP Certification. |
| **Target Date(s)** | Contact to meet with Estill mentorship by November 30. 2024. |

| | |
|---|---|
| **Activity** | Learn Estill Voiceprint |
| **Objective** | To further understand the figures of the Estill Voice Method (EVM) through analysis of the real-time spectral analysis program of Voiceprint. This can become a tool for meaningful feedback for myself when practicing the figures. |
| **Action 1** | Purchase Estill Voiceprint. |
| **Target Date(s)** | October 30, 2024 to purchase Voiceprint. |
| **Action 2** | Using Voiceprint and explore the spectral analysis with each of the figures. |
| **Target Date(s)** | Ongoing. |

| | |
|---|---|
| **Activity** | Identification of EVM Figures |
| **Objective** | To hear and analyze what EVM Figures are being used by singers. |
| **Action 1** | Analyze one pop song by choosing one artist's youtube live performance of the song. Together with the score decipher how the EVM belt recipe is being applied to the song. Aim to replicate with own voice the belt notes mimicking the artist's application of the figures. |
| **Target Date(s)** | 1 song per week, ongoing. |

| | |
|---|---|
| **Activity** | Application of EVM Figures |
| **Objective** | To apply EVM Figures to my teaching and refine my ability to apply the figures for immediate results. |
| **Action 1** | To host *Karaoke Masterclass* in the studio inviting students to share a pop song they are working on. Each student will receive 15 minutes coaching in the masterclass where I will focus on 1 or 2 figures to apply into their singing. |
| **Target Date(s)** | 1 masterclass per semester (semester 1: Sept – January, semester 2: February – June). |

| | |
|---|---|
| **Activity** | Learning about vocal acoustics |
| **Objective** | To understand the science of formants and resonance in singing. |
| **Action 1** | To read *Practical Vocal Acoustics: Pedagogic Applications for Teachers and Singers* by Kenneth Bozeman. |
| **Target Date(s)** | Ongoing |

| | |
|---|---|
| **Activity** | Learning about vocal anatomy of children (age 7-12 female learners) |
| **Objective** | To understand the physiological differences in children age 7-12 in female students. . |
| **Action 1** | To read and find research on children vocal development and the differences between adults. |
| **Target Date(s)** | Ongoing |

**Develop Reflection-in-action Skills**

Being mindful of reflection-in-action in daily teaching. Below activities are intended to become aware of my current level of reflection-in-action.

| | |
|---|---|
| **Activity** | To include reflection-in-action in daily teaching. |
| **Objective** | To be mindful and intentful in application of reflection-in-action in daily teaching. Analyze my current teaching situation |
| **Action 1** | To record a video of myself teaching a 30-minute lesson, analyzing the moments of silence during the lesson. |
| **Target Date(s)** | By November 30, 2024 to record the lesson. By December 31, 2024 to analyze the video. |

## Appendix C: Why the Estill Voice Method (EVM) for belting?

There are several oppositions to the use of the belt voice for singers. Spivey (2008) shares the many opinions of belting and concludes much of the rejection is from voice teachers rooted in classical singing, believing the belt voice is the female raised chest register (Rogers, 2019; Young, 2003; Miller, 2002; Ware, 1998) without blending of the head register (Ware, 1998) contributing to tissue damage (Reid, 2002; Ruhl, 1986), development of nodules on the vocal folds (Cain, 1998) and severe vocal misuse (Miller, 2002; Doscher, 1993).

On the contrary, pedagogues argue belting is an outgrowth of energized speech (Miles and Hollien, 1990; Edwin, 1998; Balog, 2005; Spivey, 2008). Individuals can speak daily without damage to the voice, hence belting can be sung in the same healthy manner (Herseth, 2004; Boardman, 1987). There does not need to be tension, only the sensation that the area is being used (Sullivan ,1985). EVM promotes the healthy development of vocal skills based on scientific understanding and isolates specific structures in the vocal mechanism to achieve distinct voice qualities (Fantini, 2017). The method was developed by American voice pedagogue Jo Still in 1988 upon research in voice physiology (Estill and Kolton, 1979) through the division of the vocal system into three components: power (lungs), source (glottis) and filter (vocal tract) (Estill and Kolton, 1979; Kolton and Estill, 1981; Kmucha, Yanagisawa, and Estill, 1990). The emphasis on the quantification and localization of the muscular effort level for different voice production brings awareness to the singer of what is happening in the sound produced (Kolton and Estill, 1979; Yanagisawa et al., 1991;Yanagisawa, Kmucha, and Estill, 1990). Thus the EVM method is chosen as the basis of this research paper for a learning strategy in belting for age 7-12 female learners.

## Appendix D: Reflection on learning the EVM figures based on Borton's Reflective Model

Below reflection is based on Borton's Reflective Model *(*Skinner and Mitchell, 2016) of What? So what? And now what?

What?

Through my learning of belt receipt in EVM I studied with the Estill Voice Training workbook (Estill et al., 2019) to understand the figures. In addition, I conducted a review of the literature of information relating to the EVM figures.

So What?

There was an overwhelming amount of information on ideas that agreed and differed from Estill's original recipe. This process was particularly challenging as I had to further research on specific anatomy terms and general vocal acoustic knowledge involved to understand the literature. Being relatively new to the figures I questioned my assumptions and had to confirm my understanding of the scientific literature through additional readings. As my research continued, I gained confidence in synthesizing the information.

Now What?

Reflecting on the learning journey of EVM figures has inspired me to acquire a further understanding of the body anatomy, connecting a stronger relationship between muscle movement and the impact on the sound produced. Through my literature review, I recognize I lack the understanding of the science of formants and sound resonance. This area has always been a fear of mine, feeling it is too much information to understand. However, learning about the EVM figures gave me a great appreciation of how formant and

## Appendix E: The undefined Thyroid Cartilage

A vertical position of the thyroid cartilage is demanded in the EVM belt. The vertical position creates greater distance between the true vocal fold attachment points which contributes to longer vocal folds (Unteregger et al, 2019). The increased length of true vocal folds assists with a fuller sound production. The thyroid cartilage, the largest cartilage in the larynx acts as a protective shield around the vocal folds and creates a resonating chamber to assist in amplifying sound that passes through the vocal tract (Gilikson et al, 2017). The vertical position promotes true vocal folds to have better closure contributing to a more focused sound in belting (Unteregger et al, 2019). The tilt of the thyroid cartilage occurs when the TVF are adducted (Estill et al, 2019). When the thyroid cartilage is tilted, this results in thinner vocal folds (Kayes, 2017). Thinner vocal folds will vibrate faster, the faster speed results in a higher pitch beneficial for the belt recipe (Kayes, 2017). When the thyroid cartilage is tilted backward it reduces tension in the vocal fold and leads to a thick body cover (Estill et al, 2019).

In children, the thyroid cartilage is smaller and less developed (Sapienza, Ruddy and Baker, 2004). As the thyroid cartilage grows with age, the shape changes from cylindrical to funnel-shaped (Glickson et al, 2017), in addition this cartilage is positioned higher in children (Glickson et al, 2017). The funnel-shaped appearance, although less prominent in females compared to male, will enhance the deeper resonant tones. During growth period where a learner still has a more cylinder-shaped cartilage the sound results in a brighter colour but also a balanced pitch range (Sasaki et al, 2014). A more funnel shape will favor lower frequencies and promote warmer tones (Sasaki et al, 2014). It is concluded the anterior part of the thyroid cartilage is the last to grow and is the least developed in the age groups of this paper (Glickson et al, 2017). Thus, the muscles coordinating the angle change from any position may not be fully developed. This is further supported by Sapienza, Ruddy and Baker (2004) where no vertical laryngeal prominence was seen in the thyroid cartilage until age 10-14. The undefined change of angle in the thyroid cartilage in age 7-12 learners' results in this figure not being applicable to all singers in this learning grouping for the purpose of belting.

## Appendix F: Controversy of the Cricoid Cartilage

Estill figure promotes the tilting of the cricoid cartilage downward (Estill et al., 2019). This is supported by the research that the muscles joined with the cricoid cartilage, cricothyroid muscles, are engaged with an increase of the vocal pitch (Tschan, Honegger and Storck, 2016). The lengthening of these muscles results in the cricoid cartilage tilting forward (Chhetri, and Park, 2016) along with lengthening of the vocal folds and resulted in a higher pitch for singers (Unterregger et al, 2017). A backward tilt will shorten the vocal folds resulting in a lower pitch. For this reason, I have discovered since belting is done on an elevated vocal pitch, the tilting impact is beneficial to help students more easily to belt the pitch. However, in a study of young children the cricoid cartilage was found to be maintained at an angle of 30 degree with the true vocal folds (Isaacson, 1990). Thus, the cricoid is tilted in the pediatric larynx until adulthood (Parkash, Johnny, 2015). There are minimal studies on pediatric larynx cricoid position; thus, this is an area that requires further scientific research.

There is controversy over this figure. Some argue cricoid tilt is not physically possible since there are no muscles in the cricoid cartilage (Matthews and Jain, 2023), rather serving as an attachment point for laryngeal muscles involved in movement of the vocal folds (Bourne and Kenny, 2016; Matthews and Jain, 2023). There are no muscles to tilt the cricoid down as Estill originally thought (Kayes, 2017). In addition, the cricoid cartilage is believed to provide a stable base anchor for the larynx and is a structure not designed for movement (Randestad, Lindholm and Fabian, 2000). The cricoid cartilage contains no muscles but rather serves as an attachment point for laryngeal muscles in moving the TVFs (Mathews and Jain, 2023). For young learners, cricoid cartilage is smaller and more rounded, pliable and flexible (Liu et al, 2020). The rounder shape enhances a more mellow and often softer quality as the resonance is impacted (Liu et al, 2020).

Since Estill's initial research of the cricoid cartilage, the more recent studies presented have concluded the cricoid cartilage does not move for the purpose of belting as it does not contain muscles (Mathews and Jain, 2023). For these reasons, this figure is not applicable for the purpose of this paper.